

# The Frequency and Outcome of Lip Cancer in Serbian Population\*

## SUMMARY

**Aim:** Lip cancer is one of the most common cancers of the head and neck region. Among all lip malignancies, squamous cell carcinoma is most common, whereas basal cell carcinoma accounts for only 1% of all lip carcinomas. The aim of this paper was to evaluate the frequency of lip lesions among Serbian population and to consider its outcome.

**Material and Method:** The analysis encompassed 479 patients who were hospitalized at the Clinic of Maxillofacial Surgery (Faculty of Dentistry, University of Belgrade) during the period 1989-2005 for the treatment of lip lesions. The following parameters were analyzed: sex, age, size and localization of the lesion, duration of hospitalization, TNM classification, histopathologic analysis, type of surgical procedure, other possible treatment, and a recurrence rate.

**Results:** There were majority of males (78%). Average age of our patients was 63.4 years. Lesions were most often localized in the lower lip (88%), and less frequently in the upper lip (8%) or at the lip angle (4%). Average size of the lesion was 24.3 mm. Data confirmed that the "W" excision was the most frequently used surgical procedure, and for bigger lesions, surgical reconstruction was performed by the technique suggested by Karapandzic. Histopathologic analysis confirmed the most frequent incidence of the squamous cell carcinoma.

**Conclusion:** Squamous cell carcinoma of the lip generally has a favourable prognosis. Early detection is very important for its successful treatment.

**Keywords:** Lip Lesions; Squamous Cell Carcinoma; Lip Reconstruction

**Milan Petrović, Drago Jelovac**

University of Belgrade, Faculty of Dentistry  
Clinic of Maxillofacial Surgery  
Belgrade, Serbia

**ORIGINAL PAPER (OP)**

**Balk J Stom, 2008; 12:34-37**

## Introduction

Squamous-cell carcinoma (SCC) of the head and neck is one of the most common cancers, with a global incidence of 500,000 cases per year<sup>6</sup>. SCC of the lip is a relatively common malignancy of the head and neck region, accounting for approximately one quarter of all oral cavity cancers<sup>10</sup>. Basal cell carcinoma (BCC) accounts for only 1% of all lip carcinomas<sup>11</sup>, while other malignancies of the lip have also been reported, but are less common<sup>11</sup>.

The lip cancer is one of the most easily diagnosed, with a generally good prognosis<sup>10</sup>. Although this form of

cancer is generally curable compared with other head and neck malignancies, regional metastases, local recurrence, and even death from this disease may occasionally occur<sup>10</sup>. Moreover, in some individuals, lip cancer may behave aggressively, which is manifested by recurrence of the lesion after surgical removal, or mortality rate up to 15% of patients<sup>11</sup>.

The single most important prognostic factor for SCC of the head and neck is complete surgical removal of the neoplasm, because it is generally believed that failure to eradicate the primary tumour is the leading cause of death from this type of cancer. Surgical resection is the principal treatment for the majority of advanced-stage carcinomas of the upper aero-digestive tract and a frequent choice in treating early lesions as well<sup>6</sup>. Selection of a specific regional flap depends on the type of defect, i.e. its size and location, and on the intrinsic properties of the regional flap<sup>8</sup>.

\*Some of the presented results in this paper have been reported at the 12<sup>th</sup> Congress of the BaSS, held in Istanbul, 2007

Early cancers of the lip and oral cavity (stage I and stage II) are highly curable by surgery alone, or along with radiation therapy, and the choice of treatment is dictated by the anticipated functional and cosmetic results of treatment<sup>8</sup>. However, the behaviour of lip cancer generally resembles skin cancer more than carcinoma of mucosal origin in the oral cavity proper<sup>11</sup>. The presence of a positive margin of the resected lesion significantly increases the risk of local recurrence, as well as the depth of the tumour being >5 mm, suggesting that the combined treatment may be beneficial<sup>2</sup>.

The **aim** of this investigation was to evaluate the frequency of lip cancers among Serbian population and to consider its outcome after surgical treatment.

## Patients and Methods

The research is planned as a retrospective study, done at the Clinic of Maxillofacial Surgery at the Faculty of Dentistry, University of Belgrade, during the period 1989-2005. During this period 463 patient were admitted with the diagnosis "tumour of the lip". The data were gathered from medical histories of patients, and were entered in particular examination forms in Microsoft Access and Microsoft Excel programme.

The following parameters were analysed: sex, age, period between noticing first symptoms and the beginning of therapy, localisation and size of the lesion, presence of suspect lymph nodes, type of operation, histopathologic analysis, duration of hospitalization and recurrence rate.

## Results

The lip lesion were found in 360 males (78%) and 103 females (22%). Average age of our patients was 63.4 (ranging between 11 and 96 years of age). We noticed that usually less then 6 months elapsed from noticing first symptoms and coming for the treatment (41%). Mean diameter of the lesion was 23.3 mm (2-82 mm in range).

The lip lesions most frequently developed at the lower lip, followed by the upper lip and lip angle (Fig. 1). We found suspect lymph nodes in 53 patients (11%) in the submandibular region, and in 9 patients (2%) in the submental region (Fig. 2).

The „W“ excision was the most frequently used surgical technique, followed by „V“ excision and lip shave procedure (Fig. 3). The lip reconstruction using Karapandzic's mioarterial flap was performed in 63 patients - 14% (Fig. 4), followed by Fries reconstruction, in 48 patients or 10%. Average duration of hospitalization was 12 days. 60 patients (14.9%) had infection in the postoperative period, 2 patients had necrosis, while in only

1 patient tracheotomy was required. During the follow up period of the study, recurrence developed in 49 patients (11.7%).

Histopathologic analysis of the resected lesions mainly showed malignancy (402 cases, 87%), and benign lesions were found in 61 cases, or 13%. SCC was the most common finding at the lower lip (354 patients or 86%), and BCC was found in only 4 patients (1%). At the upper lip, BCC has been more often reported (12 patients or 35%) than SCC (9 patients - 26%).

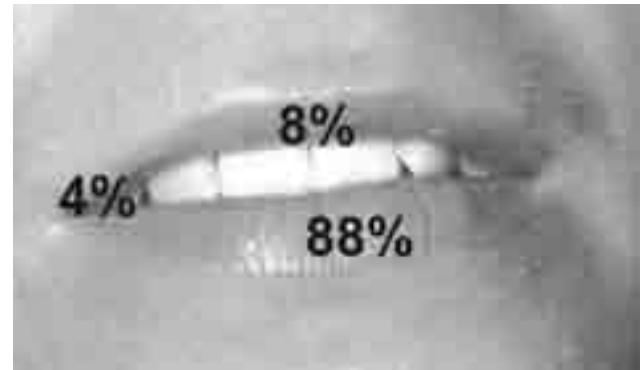


Figure 1.

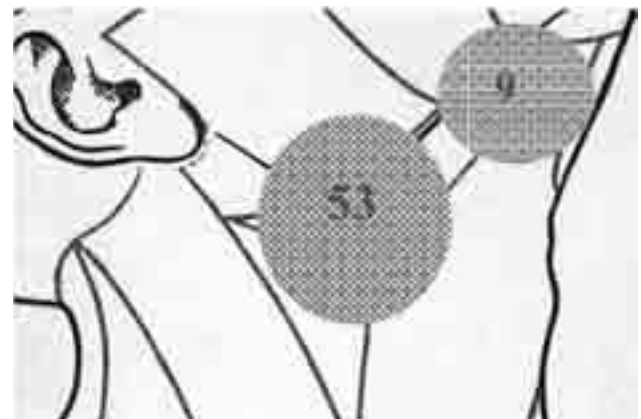


Figure 2.

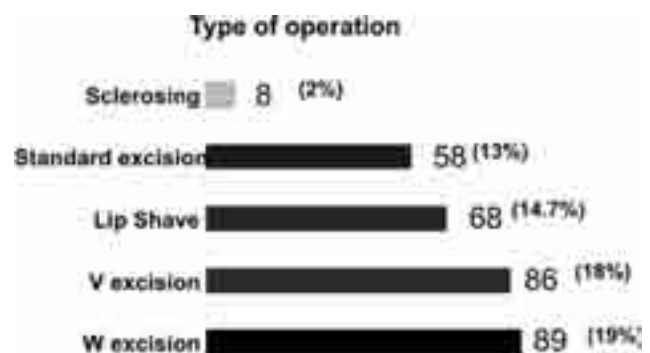

Figure 3.

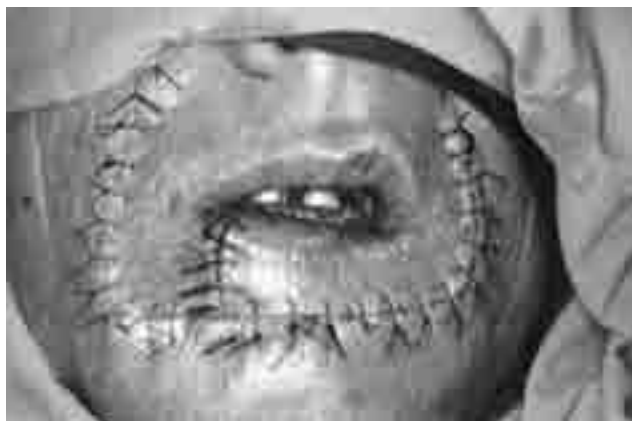

Figure 4.

## Discussion

Lip cancer represents the most frequent malignant neoplasm of the oral cavity. This study provides information about the clinicopathologic features of patients with SCC of the lip and describes the treatment modalities performed.

A previous study<sup>9</sup> from the same institution (Clinic of Maxillofacial Surgery, Faculty of Dentistry, University of Belgrade) showed that total of 223 patients with SCC of the lip, were diagnosed and treated during a 10-year period between 1991 and 2000. We noticed that from 2001 to 2005, in a 5-year shorter period, 157 patients with SCC were surgically treated. This increased number of the patients from 2001 to 2005 could be explained by the fact that all patients with SCC of the lip were treated as in-patients at the Faculty Clinic; before that period (between 1989 and 2001), patients with "small" lip lesions were usually treated at the out-patient basis. We analyzed only the patients which were hospitalized. We found that the lip lesion developed in the lower lip in 88% patients with lip cancers. We also found suspect lymph nodes in 13% (62) of patients.

The retrospective study performed in 113 patient<sup>11</sup> shown that there were 74 men (65.5%) and 39 women (34.5%) with tumours of the lip, aged from 14 to 106 years. Several researches indicated the lower lip as the most common site for lip cancer (88-98%), with only 2-7% arising from the upper lip and 4% at the lip commissures<sup>1,5,11</sup>. The most common age at diagnosis is 54 to 65 years.

Although a condition seen in middle age, lip cancer occasionally occurs in patients under age 30 years. Lip cancer has a predilection for men, with men to women ratios ranging from 35:1 to 6:1, depending on the location of the lesion<sup>5</sup>.

Early diagnosis and the surgical treatment are the only proper solutions in the diagnosis and therapy of these

lesions. We need an urgent awareness campaign, and programmes for the prevention and early detection of lip cancer. The average time between the first symptom and therapy was less than 6 months. It is very important to distinguish precancerous lesions (leukoplakia, eritroplakia, and actinic cheilitis), which pathologically may correspond to intraepithelial dysplasia, hyperkeratosis, carcinoma in situ, or SCC<sup>7</sup>.

Several methods for treatment of SCC of the lip are available, including surgery, radiotherapy, chemotherapy, and combination of these. The primary goals of treatment are the following: total removal of the lesion, prevention of relapse, and maintenance of quality of life<sup>3</sup>. With overall cure rates of 80 to 90%, lip cancers have a more favourable prognosis than most other head and neck cancers. The most performed surgical action was „ W “excision, followed by „ V “excision. We have particularly good experiences in the reconstruction of the lower lip using the Karapandzic mioarterial advancement flap, developed by Karapandzic in the early 1970s at our clinic<sup>9</sup>. The reconstruction made by Karapandzic mioarterial flap was performed in 10 % (48) of patients.

Approximately 85 to 95% of all oral cancer is SCC<sup>8,9</sup>. The study from Mexico<sup>4</sup> shown that there were 82 SCC (83.7%), 10 (10.2%) BCC, and 6 other diagnoses (adenocarcinoma melanoma, adenoid cystic carcinoma, Merkel cell carcinoma, lympho-epithelioma and angiosarcoma). Cervical lymph node metastases were found in 21% of patients with no previous treatment, and they developed in 5.3% after treatment<sup>1</sup>.

## References

1. Broders AC. Squamous-cell epithelioma of the lip: a study of five hundred and thirty-seven cases. In: Peterson's principles of oral and maxillofacial surgery. 2<sup>nd</sup> ed. London: Hamilton, 2004; p 659.
2. Harrison LB, Sessions RB, Hong WK, eds: Head and Neck Cancer: A Multidisciplinary Approach. Philadelphia: Lippincott-Raven, 1999; pp 100-110.
3. Jones KR, Lodge-Rigal RD, Reddick RL, et al. Prognostic factors in the recurrence of stage I and II squamous cell cancer of the oral cavity. *Arch Otolaryngol Head Neck Surg*, 1992; 118(5):483-485.
4. Luna OK, Güemes MA, Villavicencio VV, Mosqueda T. A lip cancer experience in Mexico. An 11-year retrospective study. *Oral Oncol*, 2004; 40(10):992-999.
5. Martin H, MacComb WS, Blady JV. Cancer of the lip. Part I. *Ann Surg*, 1941; 114:226.
6. Parkin DM, Laara E, Muir CS. Estimates of the worldwide frequency of sixteen major cancers in 1980. *Int J Cancer*, 1988; 41:184-197.

7. *Po Wing Yuen A, Lam KY, Lam LK, et al.* Prognostic factors of clinically stage I and II oral tongue carcinoma - A comparative study of stage, thickness, shape, growth pattern, invasive front malignancy grading, Martinez-Gimeno score, and pathologic features. *Head Neck*, 2002; 24(6):513-2002.
8. *Sykes AJ, Allan E, Irwin C.* Squamous cell carcinoma of the lip: the role of electron treatment. *Clin Oncol (R Coll Radiol)*, 1996; 8(6):384-386.
9. *Vukadinovic M, et al.* Surgical Management of Squamous Cell Carcinoma of the Lip: Analysis of a 10-Year Experience in 223 Patients. *J Oral Maxillofac Surg*, 2007; 65:675-679
10. *Teichgraeber JF, Larson DL.* Some oncologic considerations in the treatment of lip cancer. *Otolaryngol Head Neck Surg* 1988; 98:589-592.
11. *Zitsch RP, Park CW, Renner GJ, et al.* Outcome analysis for lip carcinoma. *Otolaryngol Head Neck Surg*, 1995; 113:589-596.

---

Correspondence and request for offprints to:

Milan Petrović  
Faculty of Dentistry  
Clinic of Maxillofacial Surgery  
Dr Subotića 4  
11000 Belgrade, Serbia