



## Application of radiovisiography (digital radiology) in dental clinical practice

### Primena radiovizigrafije (digitalne radiologije) u stomatološkoj kliničkoj praksi

Dragan V. Ilić\*, Ljiljana S. Stojanović†

Stomatološki fakultet Univerziteta u Beogradu, \*Klinika za bolesti zuba,

†Klinika za ortodonciju, Beograd, Srbija

#### Abstract

**Introduction.** Radiovisiography (RVG) as the latest imaging technique in dentistry with the minimal radiation exposure of the patient and numerous possibilities to process the images has many advantages over classic radiography. **Case report.** We presented an interesting clinical endodontic case of primary postulated diagnosis of traumatic periodontitis of upper right canine upon orthodontics treatment. As the patient previously had been exposed to alleged high dose of radiation the patient agreed to minimal exposition using digital RVG. The options of the tool bar of RVG Trophy device enabled the solving of etiologic factor of presented periodontitis. The enigma of the symptoms on the 'over-filled' root canal was solved zooming and 3-D analysis avoiding periapical surgery owing to the patience of the patient and the dentist in a couple of days. **Conclusion.** By applying RVG technique the time for diagnostic procedure is much shorter in comparison with traditional dental radiography enabling archiving and follow-up the presented case in the course of time.

#### Key words:

radiography, dental, digital; radiography; orthodontics; diagnosis, differential.

#### Apstrakt

**Uvod.** Radiovizigrafija (RVG) je najnovija tehnika u stomatologiji sa minimalnom ekspozicijom i brojnim mogućnostima obrade slike i ima brojne prednosti u odnosu na klasičnu radiografiju. **Prikaz bolesnika.** Prikazali smo rešavanje zanimljivog kliničkog endodontskog slučaja sa prvobitno postavljenoj dijagnozom traumatskog parodontitisa na zubu 13 nakon primene ortodontskog tretmana. Kako je prethodno bolesnica bila izložena navodno velikim dozama zračenja, pristala je na opciju minimalne ekspozicije tehnikom digitalne RVG. Primenom digitalne radiografije iz servisa RVG Trophy uređaja utvrđen je uzrok nastalog parodontitisa. Zumiranjem i trodimenzionim prikazom radiograma zuba, nakon punjenja kanala korena, primećena je opturaciona masa lagano prebačena preko nivoa apeksa zuba. Analizom snimka, uz strpljenje bolesnice od par dana, izbegnuta je nepotrebna procedura periapikalne hirurgije za kojom se često lako poseže. **Zaključak.** Primenom RVG skraćuje se vreme do postavljanja dijagnoze u poređenju sa konvencionalnom dentalnom radiografijom omogućujući arhiviranje i praćenje bolesnika u funkciji vremena.

#### Ključne reči:

radiografija, stomatološka, digitalna; radiografija; ortodoncija; dijagnoza, diferencijalna.

#### Introduction

In 1895 the first dental radiograph was taken and since that time it has become an integral part of dental practice<sup>1</sup>. Unfortunately, radiographic imaging process has not been changed much for almost 80 years except sending dental radiographs by telegraph in 1929<sup>2</sup>. Film sensitivity has been increased while radiation dosage decreased, but the basic exposure and developing processes have remained unchanged.

The first considerations about high precision and quality of computer analyses of radiographic images were presented in 1968 by Ando et al.<sup>3</sup>. Realizing the advantages of

computerized radiographic system soon, in 1973 Robb et al.<sup>4</sup> worked on specialization on operator-interactive, computer controlled system for high fidelity digitalization and analysis of biomedical images. Dawn of the digital era in dental radiography came in 1987 when the first digital radiography apparatus system called RadioVisioGraphy (RVG) was launched in Europe by a French company Trophy Radiologie. The inventor of this system, Dr. Francis Mouyen, invented in 1989 a way to employ fibre optics to narrow down a large radiographic image onto a smaller size that could be sensed by a CCD image sensor chip<sup>5</sup> that was specialized by Finnish engineer Paul Suni<sup>6</sup>. Thus completed (composed),

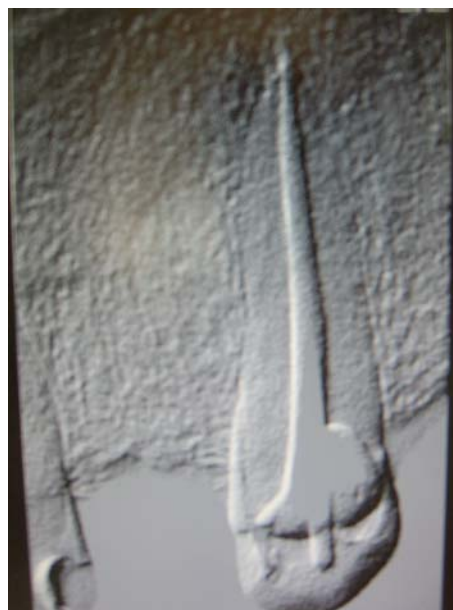the newer system offered an instantaneous imaging system not requiring a darkroom and significantly diminishing radiation.

We presented an interesting case of endodontic treatment solved with the help of RVG Trophy apparatus on the patient suffering from painful tooth still sensitive to percussion after a short period of orthodontic therapy.

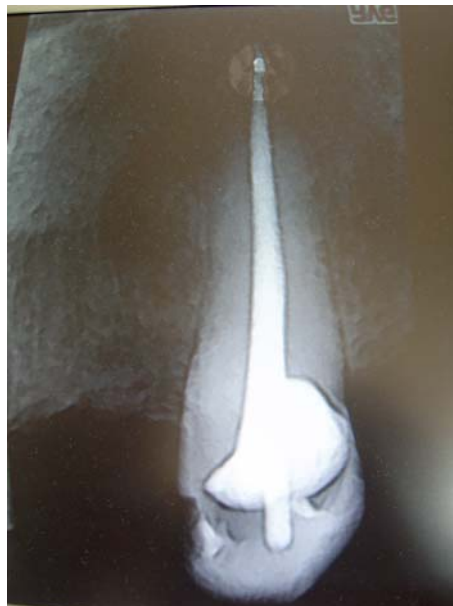### Case report

A female patient, aged 25, came to the Clinic for Restorative Dentistry and Endodontics (Faculty of Stomatology, Belgrade University) suffering from a dull pain in the upper right canine. The patient did not have previous radiographs refusing to contact her local stomatologist and made new ones. The tooth was sensitive to percussion, horizontal as well as vertical, after a short period of the applied orthodontic force (upper dental arch expansion). The vitality test for tooth 13 exposed the value of 3 mA that was in the range of satisfactory values for the sound tooth 11 (2 mA). Three days later, during the patient's second visit, the vitality test values were in the range of 1 mA for 13 and 2 mA for 11 tooth but with persistent sensitivity to percussion for tooth 13. The orthodontist decided to remove the braces and wires temporarily in order to prevent irreversible pulpitis and apical parodontitis. Four days later (at the third visit), the same symptoms were still persistent. The diagnosis was confirmed as chronic pulpitis and parodontitis (pulpoperiapical inflammation without periapical bone lesion). Clinical symptoms confirmed the postulated diagnosis as the consequence of overdosed forces during arch expansion. The endodontic procedure assumed biopulpectomy (electro odontometry, crown-down preparation and the root canal analgesic dressing). At the fourth visit, three days later, root canal was obturated with master gutta-percha cone 45. Manual lateral-vertical compaction technique of gutta-percha was applied using Acroseal endodontic sealer (calcium hydroxide, enoxolone preparation). Accessory gutta-percha cones were compressed laterally by cold spreaders and vertical compaction of obturation mass by pluggers to obtain homogenous dense canal filling. Coronal cavity was restored by composite filling. Explaining the patient of low radiation dose, the first RVG radiogram of obturated canal was analyzed with contrast filter option (Figure 1).

Radiovisiography revealed a slightly overfilled obturation mass and unclear ellipsoidal area in alveolar bone segment between teeth 13 and 11 (Figure 1). This finding and still tenderness to percussion provoked therapist to clear up the situation of that bone segment due to the possible causative factor (chronic bone lesion). Because of that, zooming in normal (without contrast) window format was made (Figure 2). In this way the situation was cleared up concerning the alveolar bone lesion at the place of the missing tooth 12 and apical part of the root. The bone lesion area was marked by a software ruler as 9.2 mm in diameter. Unfortunately, the patient forgot to tell us to have had tooth 12 extracted a few months before, causing the ellipsoid-shape bone defect in that region to be noted clearer in Figure 1,



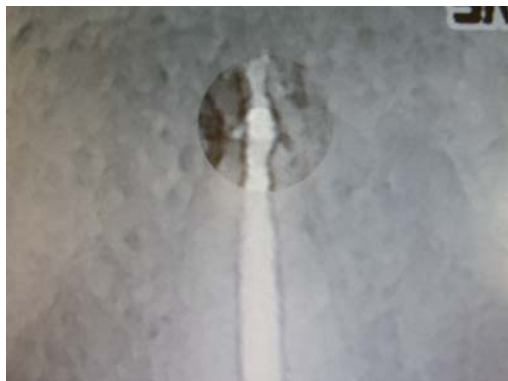**Fig. 1 – Radiovisiographic image with contrast effect of the upper right canine after root canal obturation made by the manual lateral-vertical technique of gutta-percha compaction**



**Fig. 2 – A marked area of the apical portion of the root for zooming in 'window' format**

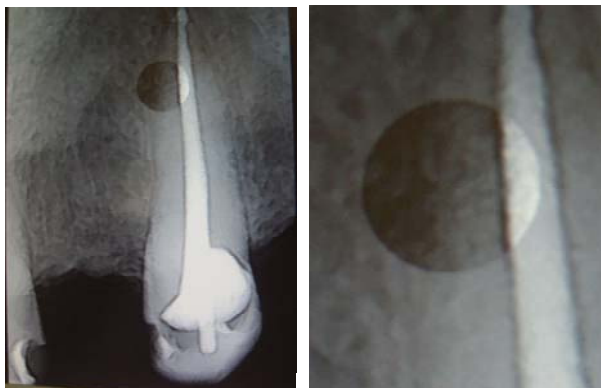
thus confirming the patient's own words that it was „a difficult and unpleasant intervention at tooth 12 with gross existing process“. Anamnestic data and symptoms were reasons to zoom (2X) the apical part and now exposed to contrast filter option thus giving the next display image (Figure 3), as well as to apply densitometry analysis later on. The analysis of the radiogram revealed overfilling of endodontic sealer beyond the root apex as the number-eight-shaped displayed slight shadow in apical area of the root (Figure 3). A certain amount of the sealer was exposed at the mesial side of the apical segment and visible as small ellipsoid light grey area. The denser gutta-percha mass reached the last millimetre of the canal exposing an oval rectangular field presented as the

more contrasted field than endodontic sealer. Due to the mild sensitivity to percussion at the fifth visit the patient was advised to have analgesic oral administration in the next three days as an integral part of endodontic procedure. After that period, obturated tooth was less sensitive to lateral and vertical percussion test and almost without any symptoms in the next week.



**Fig. 3 – A zoomed apical region (2X) with the applied contrast effect – a clear radiopaque field of an overfilled gutta-percha mass was presented as oblique rectangle in the region of the apical foramen. A mass over it is noted as a number-eight-shaped slight shadow area and presents an endodontic sealer**

The next step was zooming of the area at the mesial portion of the middle segment of the treated canine tooth (Figure 4). The reason for zooming was the presence of ra-

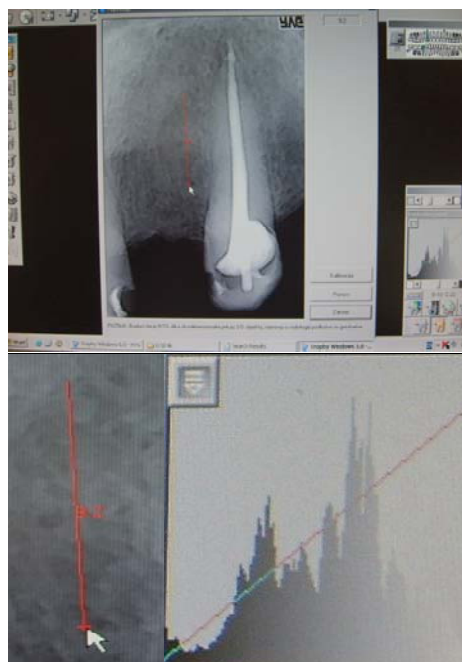


**Fig. 4 – A marked area points out the presence of a lateral pulp-periodontal canal, filled almost totally with obturation sealer**

diolucent elliptic area noted on the first RVG (contrast filter option in Figure 1 and normal window option in Figure 2). The lateral pulpoperiodontal canal was noted as communicating to the ellipsoid bone defect due to possible pulpal pathology. This canal located at the border of the middle and apical portion of the root was almost totally filled with endodontic sealer enoxolon, an ingredient of Acroseal (greyish line) owing to the lateral and vertical forces during the act of compaction. Antinflammatory action of enoxolon may be of significance for subsiding inflammation in periodontal tissues.

The indication for endodontic treatment was postulated upon the removing of the braces, allegedly responsible for percussion sensitivity, when unpleasant symptoms did not vanish even four days later on. As the tooth 13 was not in traumatic contact position, the diagnosis of pulpoperiodontitis, irreversible inflammatory condition of pulp with affected apical periodontal tissues were made. The only choice was vital extirpation, canal obturation and coronal composite restoration.


Densitometry analysis of adjacent mesial part of alveolar bone gave a histogram presented in Figure 5. A ruler from the service tool bar enabled measuring the longer diameter of elliptic bone defect as 9,2 mm and discerned various bone density values. The distant points of the longer diameter were of the high density value. The remaining inner portion exposes decreasing density and lower values in the middle of diameter. These findings confirmed the histogram values shown in the right lower corner in Figure 5.



**Fig. 5 – A marked, bigger diameter of elliptic resorptive alveolar bone lesion by the ruler in the condition of repairation was subjected to densitometric analysis. A histogram is placed at the middle right margin of the figure**

The service tool bar enables three-dimensional image which was used for analysis of root canal filling mass (Figure 6). Greyish radiopaque elliptic bulging area of overfilled endodontic sealer was clearly noted beyond the root apex. At the very end of the root canal (last millimetre), the amount of presented convex shadow pointed out probably to the more gutta-percha mass and more dramatical situation in comparison with Figure 3 where two-dimensional image was applied like it would be done with conventional radiography.

Considering the overfilled material in Figure 6 the subsiding the symptoms a week upon completion of the therapy pointed up that patience is mandatory for both the patient and the therapist.



**Fig. 6 – Three-dimensional analysis showed overfilled obturation mass as mild bulging at the very end of the root canal**

Aforementioned RVG findings in concordance to the correct endodontic treatment procedure excluded periapical surgery.

### Discussion

Digital RVG equipped with a special image analysing software, enlarging, zooming, fast imaging by a CCD sensor, shading and contrast function, densitometry and 3-D analyses, linear and angle measuring as well as archiving and interchange of records and internet consultation exposed many advantages over traditional radiography promises comfort-

able practice for the general practitioner and other specialists. The advantages over conventional radiography have been proved during the past two decades in published papers worldwide, owing to many advantages in comparison to classical dental radiographies<sup>6-11</sup>. Kantor<sup>2</sup> even noted that interest for RVG system exploded exposing the rise in cumulative number of articles from around twenty in 1992 to over 700 in 2004.

Digital radiovisiography was used in the presented case due to less exposition time as compared with the previous exposing of three conventional retroalveolar and panoramic radiography. Radiovisiography we made displayed a high resolution of details owing to filter options, zooming and densitometry effect revealing lateral lesion and pulpoperiodontal sealed canal. The enigma of 'overfilled' root canal was solved due to zooming and 3-D analysis avoiding periapical surgery diagnostic quality images. The obtained data saved the time as diagnostic procedure in compared with traditional radiography enabling archiving and follow-up the presented case in the course of time.

Conventional dental radiographies obtained by standard dental radiography could not confirm the quality of the accomplished endodontic treatment like RVG could.

### Conclusion

By applying RVG technique the time for diagnostic procedure is much shorter in comparison with traditional dental radiography enabling archiving and follow-up the presented case in the course of time.

### R E F E R E N C E S

1. *Gavrilovic V.* Introducing stomatology. Belgrade – Zagreb: Medicinska knjiga; 1980. (Serbian)
2. *Kantor ML.* Dental digital radiography: more than a fad, less than a revolution. *J Am Dent Assoc* 2005; 136(10): 1358–60.
3. *Ando S, Nishioka T, Ozawa M, Yamano H, Shinoda K.* Computer analysis of radiographic images. *J Nihon Univ Sch Dent* 1968; 10(2): 65–70.
4. *Robb RA, Greenleaf JF, Ritman EL, Lee SL, Herman GT, Sturm RE,* et al. An operator-interactive, computer controlled system for high fidelity digitization and analysis of biomedical images. In: *Johnson SA, Robb RA, Greenleaf JF, Ritman EL, Lee SL, Herman GT,* et al, editors. *Proceedings of the Society of Photo-optical Instrumentation Engineers. San Diego: Quantitative Imagery in the Biomedical Sciences-II; 1973. p. 11–26.*
5. *Mouyen F, Benz C, Sonnabend E, Lodter JP.* Presentation and physical evaluation of RadioVisioGraphy. *Oral Surg Oral Med Oral Pathol* 1989; 68(2): 238–42.
6. *Fidanoski B.* Digital Radiography [cited 2007 February 1]. Available from: [www.fidanoski.ca/dentistry/digital-dental-radiography.htm](http://www.fidanoski.ca/dentistry/digital-dental-radiography.htm)
7. *Sullivan JE Jr, Di Fiore PM, Koerber A.* Radiovisiography in the detection of periapical lesions. *J Endod* 2000; 26(1): 32–5.
8. *Torić M, Masić I.* Radiovisiography—a modern method of diagnosis in stomatology. *Med Arh* 1997; 51(3–4): 109–12. (Croatian)
9. *Miletić V, Ilić DV.* Application of radiovisiography (digital radiology) in dental clinical practice. *Serb Dent J* 2005; 52(suppl 1): 47. (Serbian)
10. *Cohen S, Hargreaves KM.* Pathways of the pulp. 9th ed. St. Louis, Mo: Elsevier Mosby, 2006.
11. *Khojasteh A.* Sensor-based intraoral digital radiography. *Pract Proced Aesthet Dent* 2004; 16(5): 349–50.

Received on May 20, 2010.

Revised on November 17, 2010.

Accepted on November 25, 2010.