



## Influence of balanced occlusion in complete dentures on the decrease in the reduction of an edentulous ridge

Uticaj balansne okluzije kod totalnih proteza na smanjenje redukcije bezubog grebena

Srdjan D. Poštić

Clinic for Dental Prosthetics, Faculty of Dental Medicine, University of Belgrade, Belgrade, Serbia

### Abstract

**Background/Aim.** Balanced occlusal arrangement of artificial teeth and balanced occlusion is a specific type of occlusion that preserves the stability of complete dentures. Balanced occlusion comprises realization of tooth contacts at the working side as well as at the balancing side, at the same time. The aim of this study was to assess the influence of balanced occlusal arrangement of artificial teeth on the decrease in reduction of edentulous alveolar ridge. **Methods.** A longitudinal study on 91 fully edentulous patients was conducted using their panoramic radiographs and parameters of vertical dimension of edentulous ridges. All the patients were clinically examined by the same and a qualified dental practitioner. Numerical values of parameters of vertical dimensions of edentulous ridges and lines were statistically processed and compared using the Student's *t*-test. **Results.** Vertical dimensions and heights of edentulous ridges were different after comparison of parameters in complete denture wearers with balanced occlusion and complete denture wearers without bilaterally balanced occlusion, as well as between male and female edentulous patients. Statistically significant differences of heights were established in complete denture wearers' with a set of artificial teeth without balanced occlusion, at the baseline and 12 months after wearing of complete dentures. **Conclusion.** Balanced occlusion is a favored occlusal design in setting of artificial teeth in conventional complete dentures, which preserves edentulous ridge and influence the stability of dentures.

### Key words:

denture complete; alveolar bone loss; dental occlusion balanced; radiography, panoramic.

### Apstrakt

**Uvod/Cilj.** Postava veštačkih zuba po balansnoj okluziji (BO) i balansno okluzalno uravnoteženje je posebna vrsta okluzije koja uslovljava i čuva stabilnost totalnih proteza. Balansna okluzija podrazumeva da kontakti veštačkih zuba postoje u isto vreme i na radnoj i na balansnoj strani. Cilj ove studije bio je da se ispita uticaj postave zuba po balansnoj okluziji na sniženje redukcije bezubog grebena. **Metode.** U okviru ove longitudinalne studije ispitan je 91 bezubi pacijent uz korišćenje ortopantomograma i parametara vertikalne dimenzije bezubog grebena. Svi pacijenti bili su i klinički ispitani od strane istog kvalifikovanog stomatologa, specijaliste stomatološke protetike. Numeričke vrednosti parametara vertikalne dimenzije bezubih grebenova bile su statistički obrađene i upoređene korišćenjem Studentovog *t*-testa. **Rezultati.** Vertikalna rastojanja i visine bezubih grebenova bile su različite pri upoređivanju parametara kod pacijenata koji su koristili totalne proteze sa BO i pacijenata koji su imali totalne proteze bez obostrane BO, a takođe i između pacijenata i pacijentkinja. Statistički značajne razlike utvrđene su kod pacijenata sa totalnim protezama u kojima zubi nisu bili postavljeni u skladu sa obostrano uravnoteženom BO, na početku merenja i posle 12 meseci terapije totalnim protezama. **Zaključak.** Balansna okluzija je zadovoljavajuća i uspešan okluzalni odnos veštačkih zuba u totalnim zubnim protezama koji utiče na očuvanje bezubog grebena i uslovljava stabilnost totalnih proteza.

### Ključne reči:

zubna proteza, totalna; alveolna kost, gubitak; zubna okluzija, balansna; ortopantomogram.

### Introduction

The phenomenon of the marked atrophy of the alveolar bone following tooth loss has been termed a "reduction of residual ridges" by Atwood, who considered it a major oral

problem entity<sup>1</sup>. These alveolar bone and oral soft tissue changes observed in denture wearers may be an inevitable consequence of the loss of natural teeth, tissue remodelling, occlusal factors, and prolonged denture wear<sup>1-17</sup>. Alveolar bone loss subsequent to a long-term edentulism may be se-

vere and the process may progress<sup>3, 5, 6, 8-15</sup>. Although generally more pronounced in the mandible and characterized by individual variability in volume and rate, advanced reduction in residual ridges (RRR) presents a significant challenge in prosthetic therapy of edentulous patients<sup>14-17</sup>.

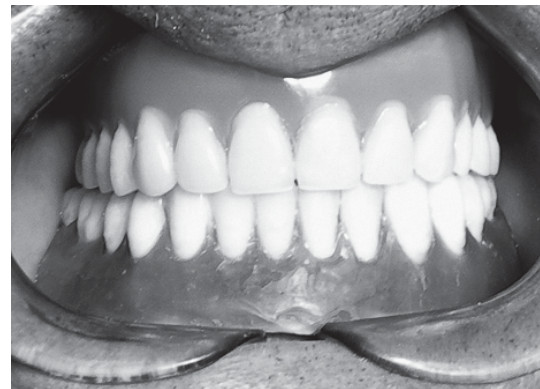
Balanced occlusal arrangement is a specific type of occlusion. Occlusion of this kind is used only in the setting of artificial teeth in complete dentures, and usually not related to natural dentition. In the literature, balanced occlusal arrangement is assigned as "balanced occlusion" (BO) comprising realization of contacts at the working side as well as at the balancing side, at the same time<sup>18-21</sup>. Balanced occlusal contacts have convincing advantages, but certain disadvantages, too. The advantages of occlusal balance are preservation of the stability of complete dentures, for the chewing function, and decrease in active loading of supporting tissue and edentulous ridge.

Setting of artificial teeth in balanced occlusal arrangement should cause a reduction in loading to edentulous ridge. In support to this statement are descriptions of significant reductions in edentulous ridges that were evidenced in the literature up to now, particularly for cases which teeth not set in complete dentures according to BO<sup>22-28</sup>. Certain disadvantages of setting of a teeth in balanced occlusal arrangement could be in the fact that changes in chewing pattern are required for denture wearers, which prolongs a period of adaptation to complete dentures<sup>20, 21, 27</sup>.

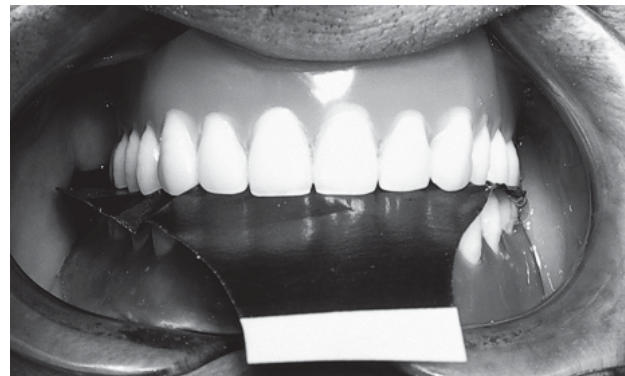
The aim of this study was to assess the influence of balanced occlusal arrangement of artificial teeth on the decrease in the reduction of an edentulous alveolar ridge.

### Methods

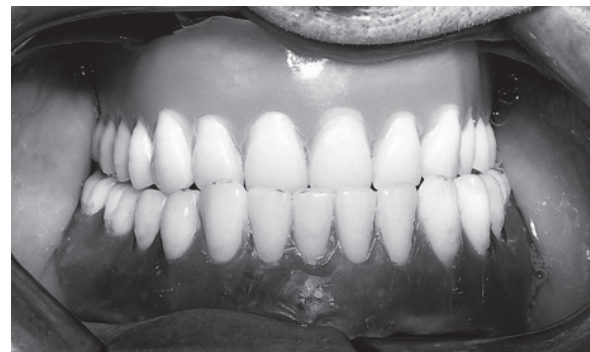The patients included in this study were edentulous. The experimental group consisted of 61 conventional acrylic complete denture wearers – 21 men, aged 45–65 years, and 40 women, aged 47–65 years. In complete dentures of the patients of the experimental group, artificial teeth were arranged according to the principles of balanced occlusal arrangement (Figures 1–6). For each patient of the experimental group, complete dentures were constructed in the Clinic of Dental Prosthetic, School of Dentistry, University in Belgrade, following the established procedures using semiad-



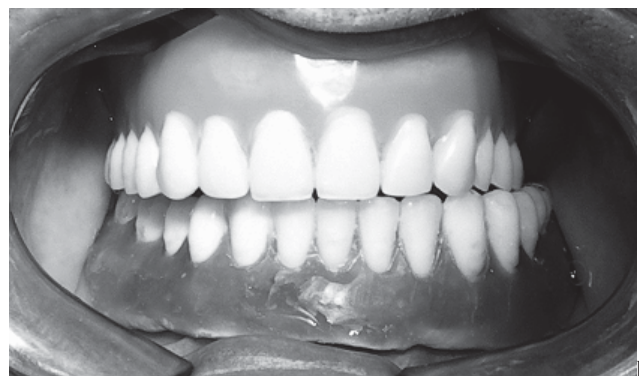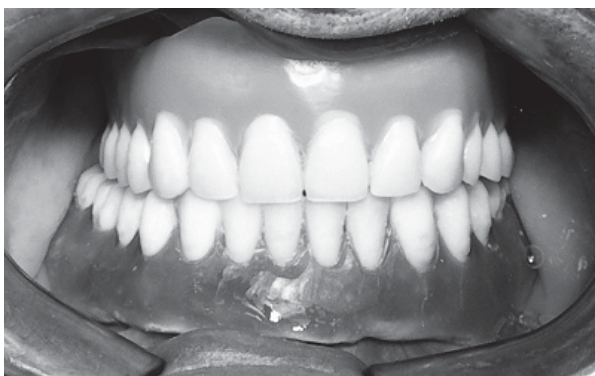**Fig. 1 – Balanced occlusion of artificial teeth in centric position in a patient of the experimental group**



**Fig. 2 – Check-in of occlusal contacts of artificial teeth in complete dentures in patient of the experimental group using articulating paper**

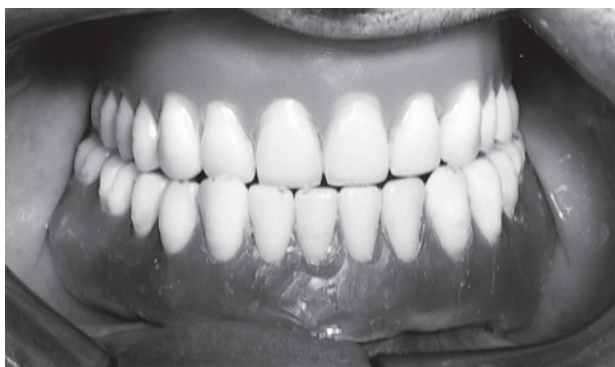

**Fig. 4 – Balanced occlusal contacts in propulsion of a patient in the experimental group**

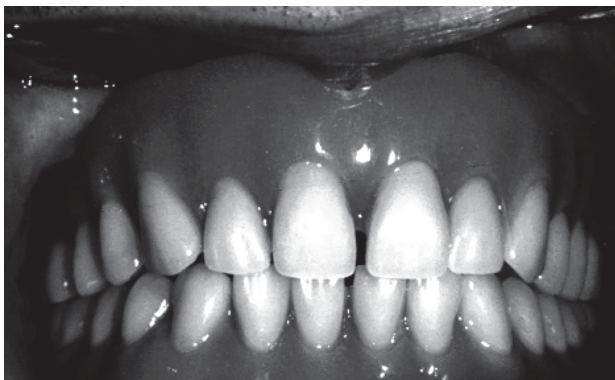

**Fig. 3 – Balanced occlusion in lateral position**

a) to the right side in the mouth of a patient in the experimental group  
b) to the left side in the mouth of a patient in the experimental group

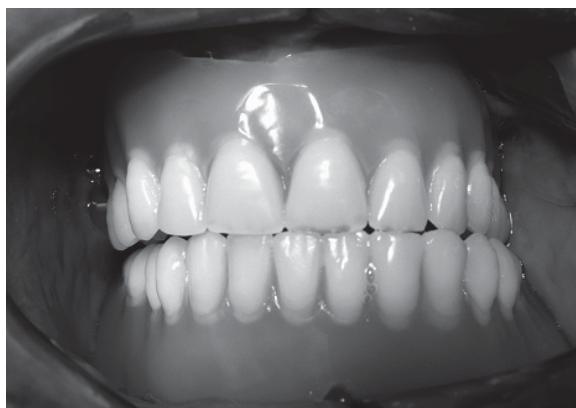

**Fig. 5 – Balanced occlusal contacts in lateropulsion of a patient in the experimental group**



**Fig. 6 – Balanced occlusion of artificial teeth in complete dentures of an edentulous woman in the experimental group**

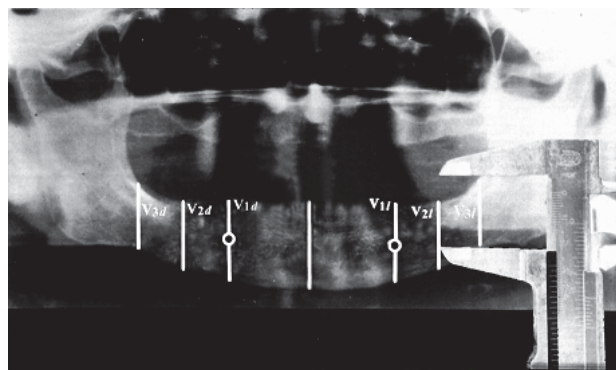
justable articulator (Artex, Girbach Dental, Germany). The control group included 30 complete denture wearers – 15 men, aged 50–65 years, and 15 women, aged 49–60 years. In complete dentures of the patients of the control group, artificial teeth were not set appropriately to balanced occlusal arrangement. Complete dentures of the patients of the control group were not fabricated in University Clinic of Dental Prosthetics in Belgrade, and teeth were arranged similar to the occlusal scheme of dentate subjects with unilaterally balanced-grouped occlusal design (Figure 7). The patients of the control group came to the Clinic of Dental Prosthetics, University in Belgrade because of the need for rebasing, relining and correcting their complete dentures, as well as for interest in fabricating a new pair of complete dentures.



**Fig. 7 – Unilaterally balanced occlusion of artificial teeth in complete dentures of a patient in the control group**

Standardized panoramic radiographs (Kodak T-MAT G) were made in all of the patients, respecting a determined distance of scale on a plastic chin's holder of orthopantomograph (Orthopantomograph 10-serial no 01492, Siemens, Germany). Two panoramic radiographs were provided for every patient – in a 12-months interval. The baseline of observation was a clinical situation immediately after fabricating and positioning of complete dentures in the mouths of the patients of the experimental group, or after finished rebasing of dentures of patients in the control group. The next measurements were provided 12 months after baseline. A total of 91 patients were assessed in this study, thus 91 panoramic radiographs were analyzed prior to the therapy by complete dentures, and 91 panoramic radiographs were analyzed after 12 months with respect to the baseline. Next, 61 panoramic radiographs were made for the patients of the experimental group after completion of the prosthetic therapy by complete dentures with a balanced occlusal design, in a 12-months period.

Four parameters were analyzed on panoramic radiographs of patients: heights of edentulous ridges of corpuses of mandibles in the areas of mental foramen to the right side and to the left side, and heights of the areas in which were roots of molars to the right and to the left side. Two control parameters were assigned on panoramic radiographs in the regions of distal edges of retromolar pads to the left and to the right side. The parameters were established using vertical lines which were drawn through midpoints of mental foramens towards lower edges of panoramic radiographs. A segment of each of these lines and a distance from the point on the upper edge of the corpus of mandible to the point on the lower edge of corpus of mandible was adequately marked as V1d to the right side, as well as by V1l. Similarly, lines were drawn from the distal edge of retromolar pads vertically to the lower edge of panoramic radiograph and the segments of these lines were marked as V3d, and V3l, respectively. At the middle of the distance between the lines V1d and V3d, and at the middle of the distance between the lines V1l and V3l vertical lines were drawn in rectangular position with respect to the lower edge of panoramic radiographs, and these lines were assigned as V2d to the right, and V2l to the left. Vertical dimension in this study was measured at 4 sites: in the region of the first missing molars and in the regions of foramen mentale (Figure 8). Heights of lines



**Fig. 8 – Panoramic radiograph of an edentulous patient in the experimental group and parameters of heights of edentulous ridges to the left side – V1l, V2l and V3l and to the right side – V1d, V2d and V3d**

which were assigned were measured using a nanometer scale (Manser, Inox, Switzerland) with divisions of 0.1 part of millimeter and with the error of a measurement of 0.05 mm.

A new pair of conventional complete dentures with BO was fabricated for every patient of the experimental group, at the beginning of the measurement.

Numerical values of vertical dimension and lines were statistically processed and compared using the Student's *t*-test.

## Results

Numerical values of heights of edentulous ridges were different at the baseline and after a 12-month-observation between the patients of the experimental group and those of the control group.

A vertical dimension and height of edentulous ridges were measured on each panoramic radiograph of the patients. The results and numerical values of heights are shown in tables, separately for edentulous men and women (Table 1). Statistically significant differences of heights were established in the patients of the control group at the baseline and of 12 months after wearing of complete dentures, indicating unsuccessful wearing of their complete dentures and harmful influence of unilaterally balanced occlusal scheme in dentures.

Marked atrophy and reduction in the alveolar bone following tooth loss complicate prosthodontic rehabilitation<sup>3, 5, 12, 13, 17, 20, 21</sup>. Difficulties were observed in clinical work in the procedure of impressing edentulous jaws with reduced and resorbed edentulous ridges<sup>19-21</sup>. Many of the problems were obvious in achievement and maintaining the persistence of stability of fabricated acrylic complete dentures. It was particularly shown for lower complete dentures on edentulous mandibles<sup>5, 12, 20, 21</sup>. Edentulous patients with RRR have had serious problems in chewing with complete dentures<sup>13, 16, 20, 21</sup>. Because of all of these reasons it is of crucial importance that the height of edentulous alveolar ridge after tooth extractions remains at the constant level, as much as possible in a long run. Additionally, it is necessary that fabricated acrylic dentures, regarding constant pressures to edentulous ridge, do not cause postponed RRR. Preservation of level of edentulous ridge and alveolar bone after extractions of teeth is of ultimate importance in the therapy and in maintaining of therapeutic effects during wearing complete acrylic dentures.

Based on literature data, it was shown that the most intensive reductions in edentulous ridges, particularly for the lower jaws, happened in mouths of fully edentulous patients in the regions of missing molars<sup>1, 12, 20, 21</sup>. The region of the first missing molar is principally predisposed to reductions. Moreover, it is the fact that this region is very hard to deter-

Table 1

The results and numerical values of heights of edentulous ridges for both male and female patients

Patients	Height of segment of mandible's ridge	Experimental group			Control group		
		$\bar{x} \pm SD$ (mm) at the baseline	$\bar{x} \pm SD$ (mm) other 12 months	<i>p</i>	$\bar{x} \pm SD$ (mm) at the baseline	$\bar{x} \pm SD$ (mm) other 12 months	<i>p</i>
Men	V1d	33.17 ± 3.74	33.04 ± 3.85	ns	30.06 ± 2.57	27.19 ± 3.46	0.06
	V2d	30.28 ± 4.17	30.19 ± 4.32	ns	28.1 ± 2.94	25.42 ± 3.76	0.03
	V1l	33.76 ± 3.89	33.71 ± 3.95	ns	30.21 ± 2.63	27.05 ± 3.58	0.08
	V2l	30.45 ± 4.08	30.41 ± 4.14	ns	28.24 ± 2.89	25.34 ± 3.89	0.02
Women	V1d	30.09 ± 2.96	30.01 ± 3.14	ns	28.27 ± 2.74	24.21 ± 3.07	0.07
	V2d	28.38 ± 2.76	28.42 ± 2.93	ns	26.17 ± 2.98	23.57 ± 2.86	0.02
	V1l	30.02 ± 2.91	29.97 ± 3.05	ns	28.31 ± 2.83	24.16 ± 3.12	0.9
	V2l	28.44 ± 2.81	28.41 ± 3.17	ns	26.14 ± 2.92	23.31 ± 2.93	0.01

ns – no significance

Statistically significant differences in vertical dimensions of edentulous ridges were not established in the experimental group after 12 months of wearing of conventional complete dentures, which indicated success in the therapy by dentures and positive influence of balanced occlusal design of artificial teeth in dentures to preserve the level of alveolar edentulous ridges, and prevent RRR.

## Discussion

The problem of reduction in edentulous ridge has been present in the dental literature for many years. A number of authors discussed this problem because of the fact that subsequent consequences are present prior to therapy using complete dentures and rehabilitation of edentulous orofacial system<sup>1-3, 5, 9, 21</sup>. Panoramic radiographs and other dental radiographies have been shown as very reliable and useful in assessment of RRR<sup>4, 6, 7, 10, 17</sup>.

mine in edentulous jaw and difficult to locate precisely on a cast or dental roentgen film, since there are no roots of tooth indicating exact position of the first molar with the region of chewing center<sup>4, 12, 17</sup>. For the reason of determining the region of chewing center and missing first molar, two reliable lines were assigned in this study. These lines in vertical dimension were V1 and V3 lines located mesially and distally respecting region of chewing center of edentulous jaw (Figure 9). The lines V1 were also used in the analysis of reductions in edentulous ridges, concerning the fact that the reduction in an edentulous jaw affects bone structures around mental foramina, too. The lines V3 were not used in the analysis of reduction in edentulous mandibles, because these lines were drawn from the appearance of retromolar pad which represents the structure of mandible bone that is less predisposed to reductions.

Numerous authors advocated for setting of artificial teeth in complete dentures as the exact copying of position of

teeth prior to extractions. Authors of these clinical studies exposed explanation that the appearance of teeth, arranged the same way as it was in natural dentition prior extraction, offer to a patient an excellent esthetic, as well as much important enhanced subjective feeling of identical position and dimension of dental arch in their mouths without a change in habitual chewing movements of jaws<sup>20, 29–32</sup>. However, it is the fact that characteristic of natural dentition and occlusion is unilaterally balanced occlusion with tooth contacts only at working side which is used in chewing. Most often, in natural dentition there are not contacts at balancing side during chewing on the working side. If this concept of occlusion is applied to setting of artificial teeth in complete dentures, more intensive pressures of artificial teeth at the working side will compromise supporting tissues, and will be a factor for intensive resorption of edentulous ridge influencing RRR<sup>21, 33–37</sup>.

The concept of bilaterally BO in complete dentures has to provide that chewing forces and forces in the function of edentulous mouth are applied to the working-ipsilateral and non-working balancing-contralateral side simultaneously,

and over all of the surfaces of edentulous ridge, resulting in the decrease in pressure on edentulous jaw, and preventing RRR<sup>27, 38</sup>. This study confirmed the same level of edentulous residual ridge prior the therapy and after the therapy by acrylic complete dentures in the patients of the experimental group. At the same time, the level of residual edentulous ridge significantly decreased in the patients of the control group most probably because of the fact that artificial teeth in their complete denture were not set in accordance with BO (Table 1).

On the basis of this study the concept of balanced occlusal schemes should be applied not only in setting of artificial teeth in conventional complete dentures, but also in construction of complete dentures on implants which are inserted and osseointegrated in edentulous jaws<sup>38, 39</sup>.

### Conclusion

BO is a favored occlusal design in setting artificial teeth in conventional complete dentures since it preserves edentulous ridge and influences the stability of dentures.

### R E F E R E N C E S

1. *Atwood DA*. Reduction of residual ridges: a major oral disease entity. *J Prosthet Dent* 1971; 26(3): 266–79.
2. *Atwood DA, Coy WA*. Clinical, cephalometric, and densitometric study of reduction of residual ridges. *J Prosthet Dent* 1971; 26(3): 280–95.
3. *Zmysłowska E, Ledzion S, Jędrzejewski K*. Factors affecting mandibular residual ridge resorption in edentulous patients: a preliminary report. *Folia Morphol (Warsz)* 2007; 66(4): 346–52.
4. *Yüzügüllü B, Gulsabi A, İmirzalıoğlu P*. Radiomorphometric indices and their relation to alveolar bone loss in completely edentulous Turkish patients: a retrospective study. *J Prosthet Dent* 2009; 101(3): 160–5.
5. *Marković D, Krstić M*. Current knowledge on resorption of the edentulous alveolar ridge. *Med Pregl* 1999; 52(9–10): 357–61. (Croatian)
6. *Humphries S, Devlin H, Worthington H*. A radiographic investigation into bone resorption of mandibular alveolar bone in elderly edentulous adults. *J Dent* 1989; 17(2): 94–6.
7. *Canger EM, Celenk P*. Radiographic evaluation of alveolar ridge heights of dentate and edentulous patients. *Gerodontology* 2012; 29(1): 17–23.
8. *Canwood JI, Howell RA*. A classification of the edentulous jaws. *Int J Oral Maxillofac Surg* 1988; 17(4): 232–6.
9. *Ortman HR*. Factors of bone resorption of the residual ridge. *J Prosthet Dent* 1962; 12: 429–40.
10. *Carlsson GE, Ragnarson N, Astrand P*. Changes in height of the alveolar process in edentulous segments. A longitudinal clinical and radiographic study of full upper denture cases with residual lower anteriors. *Odontol Tidskr* 1967; 75(3): 193–208.
11. *Campbell RL*. A comparative study of the resorption of the alveolar ridges in denture-wearers and non-denture-wearers. *J Am Dent Assoc* 1960; 60: 143–53.
12. *Tallgren A*. The continuing reduction of the residual alveolar ridges in complete denture wearers: a mixed-longitudinal study covering 25 years. *J Prosthet Dent* 1972; 27(2): 120–32.
13. *Xie Q, Närhi TO, Nevalainen JM, Wolf J, Ainamo A*. Oral status and prosthetic factors related to residual ridge resorption in elderly subjects. *Acta Odontol Scand* 1997; 55(5): 306–13.
14. *Wyatt CC*. The effect of prosthodontic treatment on alveolar bone loss: a review of the literature. *J Prosthet Dent* 1998; 80(3): 362–6.
15. *Lammie GA*. The reduction of the edentulous ridges. *J Prosthet Dent* 1960; 10: 605–11.
16. *Maeda Y, Wood WW*. Finite element method simulation of bone resorption beneath a complete denture. *J Dent Res* 1989; 68(9): 1370–3.
17. *Poštić S, Marković D, Krstić M, Rakočević Z, Brković S*. Radiographic assessment of edentulous residual ridge reductions. Proceedings of the 15th Congress of the BaSS; 2010 April 22–25; Greece, Thessaloniki; 2010.
18. *Winkler S*. Essentials of complete denture prosthodontics. 1st ed. Philadelphia: WB Saunders Co; 1979. p. 332–7.
19. *Watt DM, Macgregor AR*. Biometric guides to the design of complete dentures. In: *Watt DM, Macgregor AR*, editors: Designing complete dentures. 2nd ed. Bristol: John Wright; 1986. p. 142–59.
20. *Zarb GA, Bolender CL, Eckert SE, Jacob RF, Fenton AH, Meric-Ske-Stern R*. Prosthodontic treatment for edentulous patients. 12th ed. St. Louis: Mosby; 2004.
21. *Krstić M, Petrović A, Stanišić-Sinobad D, Stošić Z*. Dental prosthesis – complete prosthesis. In: *Krstić M, Petrović A, Stanišić-Sinobad D, Stošić Z*, editors. Totalna proteza. 1st ed. Gornji Milanovac: Dečje novine; 1991. p. 277–319. (Serbian)
22. *Lang BR*. Complete denture occlusion. *Dent Clin North Am* 1996; 40(1): 85–101.
23. *Sutton AF, Worthington HV, McCord JF*. RCT comparing posterior occlusal forms for complete dentures. *J Dent Res* 2007; 86(7): 651–5.
24. *Scott BJ, Hunter RV*. Creating complete dentures that are stable in function. *Dent Update*. 2008; 35(4): 259–62, 265–7.
25. *Loney RW*. Complete Denture Manual. Halifax, Nova Scotia; Dalhousie University, Faculty of Dentistry; 2009. [cited 2010 May 29]. Available from: [www/removpros.dentistry.dal.ca/RemovSite/Manuals.../CD%20Manual%202009.pdf](http://www/removpros.dentistry.dal.ca/RemovSite/Manuals.../CD%20Manual%202009.pdf)

26. *Henriques GEP, Nóbilo MA, Mesquita MF*. Complete dentures over resorbed ridges: enhancing stability and esthetics with posterior platforms. *Braz J Oral Sci* 2003; 2(4): 160–3.
27. *Poštić SD, Krstić MS, Teodosijević MV*. A comparative study of the chewing cycles of dentate and denture-wearing subjects. *Int J Prosthodont* 1992; 5(3): 244–56.
28. *Suzuki T*. Complete denture occlusion considered from occlusal contacts during mastication. *Nihon Hotetsu Shika Gakkai Zasshi* 2004; 48(5): 664–72. (Japanese)
29. *Kaires AK*. A study of occlusal surface contacts in artificial dentures. *J Prosthet Dent* 1957; 7(4): 553–64.
30. *Becker CM, Swoope CC, Guckes AD*. Lingualized occlusion for removable prosthodontics. *J Prosthet Dent* 1977; 38(6): 601–8.
31. *Koyama M, Inaba S, Yokoyama K*. Quest for ideal occlusal patterns for complete dentures. *J Prosthet Dent* 1976; 35(6): 620–3.
32. *Beck HO*. Occlusion as related to complete removable prosthodontics. *J Prosthet Dent* 1972; 27(3): 246–62.
33. *Kawano F, Nagao K, Inoue S, Matsumoto N*. Influence of the buccolingual position of artificial posterior teeth on the pressure distribution on the supporting tissue under a complete denture. *J Oral Rehabil* 1996; 23(7): 456–63.
34. *Frechette AR*. Comparison of balanced and nonbalanced occlusion of artificial dentures based upon distribution of masticatory force. *J Prosthet Dent* 1955; 5(6): 801–10.
35. *Frechette AR*. Complete denture stability related to tooth position. *J Prosthet Dent* 1961; 11(6): 1032–7.
36. *Trapožžano VR*. Tests of balanced and nonbalanced occlusions. *J Prosthet Dent* 1960; 10(3): 476–87.
37. *Tarazi E, Ticotsky-Zadok N*. Occlusal schemes of complete dentures—a review of the literature. *Refuat Hapeh Vehashinayim* 2007; 24(1): 56–64, 85–6. (Hebrew)
38. *Pera P, Bassi F, Schierano G, Appendino P, Preti G*. Implant anchored complete mandibular denture: evaluation of masticatory efficiency, oral function and degree of satisfaction. *J Oral Rehabil* 1998; 25(6): 462–7.
39. *Heckmann SM, Heussinger S, Linke JJ, Graef F, Pröschel P*. Improvement and long-term stability of neuromuscular adaptation in implant-supported overdentures. *Clin Oral Implants Res* 2009; 20(11): 1200–5.

Received on July 16, 2011.

Revised on September 29, 2011.

Accepted on October 5, 2011.

OnLine-first, May, 2012.