

University of Novi Sad, Serbia  
 Faculty of medicine  
 Department of Dentistry<sup>1</sup>  
 Faculty of Dentistry Belgrade<sup>2</sup>

Stručni članak  
*Professional article*  
 UDK 616.314-001:616.314.18  
 DOI: 10.2298/MPNS1304149B

## PULP VITALITY PRESERVATION AFTER TRAUMATIC DENTAL INJURIES TO PERMANENT TEETH

### OČUVANJE VITALITETA PULPE NAKON TRAUME STALNIH ZUBA

Duška BLAGOJEVIĆ<sup>1</sup>, Bojan PETROVIĆ<sup>1</sup>, Dejan MARKOVIĆ<sup>2</sup>, Sanja VUJKOV<sup>1</sup> and Ivana DEMKO RIHTER<sup>1</sup>

#### Summary

**Introduction.** The pulp vitality preservation after a trauma to permanent teeth is of great importance since dental injuries are common. The aim of our study was to investigate the pulp vitality preservation after tooth injuries. **Material and Methods.** A retrospective analysis of records of patients with a trauma was performed. The sample consisted of all patients who had been referred to the Department of Dentistry of Vojvodina for a trauma to permanent teeth during the period 2005-2010. We recorded the type of injury, treatment, state of vitality during the first visit and subsequent check-ups. **Results.** The study included 162 children and adolescents aged 6-18 years having a trauma to 314 permanent teeth. The most frequent type of injuries in permanent teeth was fractures (54.5%), whereas luxation was a less common trauma (45.5%). Though different kinds of traumas have different optimal time for treatment, a period of 24 hours was taken as optimal; hence, 189 teeth were treated in optimal time and 55 complications occurred in them; while 105 complications occurred in 114 teeth which were treated 24 hours after the trauma. A year after the trauma the pulp vitality was preserved in 88 teeth (32%), pulp necrosis and other complications developed in 160 teeth (68%). **Conclusion.** The therapy of pulp vitality preservation in injured teeth was found successful in 32% and unsuccessful in 68% of cases at check-ups over one year.

**Key words:** Dental Pulp; Tooth Fractures; Tooth Avulsion; Dental Pulp Necrosis; Dentition, Permanent; Tooth Injuries; Child; Adolescent; Treatment Outcome

#### Introduction

Dental injuries often occur in children and adolescents in modern living conditions.

Injuries to permanent teeth have a great clinical importance because damage to the dental and periodontal tissues impairs the aesthetic appearance of a child as well as the mastication function and speech.

According to current knowledge based on a lot of scientific research, it has been proved that an injury in a permanent dentition crown [1-3] and a fracture of the root [2-4] are more often than supporting tissue injuries (dislocation of the tooth and dental avulsion).

#### Sažetak

**Uvod.** Očuvanje vitaliteta pulpe nakon traume stalnih zuba izuzetno je značajno, s obzirom da su povrede zuba česte. Gubitak vitaliteta pulpe povređenog zuba je osnov svih daljih komplikacija traumatskih povreda zuba. Cilj istraživanja bio je da se ispita stepen očuvanja vitaliteta pulpe nakon povrede stalnih zuba. **Materijal i metode.** Izvršena je retrospektivna analiza kartona traume pacijenata. Uzorak se sastojao iz svih slučajeva sa traumom stalnih zuba upućenih na Kliniku za stomatologiju Vojvodine, u vremenskom periodu 2005–2010. godine. Beležena je vrsta povrede, tretman, stanje vitaliteta na prvom i kontrolnim pregledima. **Rezultati.** U istraživanje je uključeno 162 dece i adolescenata uzrasta 6–18 godina, sa traumom na 314 stalnih zuba. Najzastupljeniji tip povreda kod stalnih zuba bile su frakture (54,5%). Redu su bile zastupljene luksacije (45,5%). Iako je kod različitih vrsta trauma optimalno vreme za tretman različito, mi smo uzeli period od 24 h kao optimalan. U optimalnom vremenu tretirano je 189 zuba, od kojih se javilo 55 komplikacija, a 115 zuba tretirano je posle 24 h od traume, gde se javilo 105 komplikacija. Godinu dana nakon traume, vitalitet pulpe je očuvan kod 88 zuba (32%), nekroza pulpe i komplikacije razvile su se kod 160 zuba (68%). **Zaključak.** Terapija očuvanja vitaliteta pulpe kod povreda zuba u kontrolnom periodu od godinu dana uspešna je u 32%, a neuspešna u 68% slučajeva.

**Glavne reči:** Zubna pulpa; Prelom zuba; Luksacija zuba; Nekroza zubne pulpe; Stalni zubi; Povrede zuba; Dete; Adolescent; Ishod lečenja

Dental injuries themselves represent a complication, and they also induce a number of additional complications. One of these is loss of the pulp vitality [5].

Loss of the pulp vitality may be caused by strong noxious agents acting through the dentinal tubules or directly to the pulp, or it may be due to damage to the nervous fibers in a tooth root apex or to blood vessels and occurrence of ischemia.

The basic aim of treatment of tooth crown and root fractures and dislocations is to preserve the pulp vitality. Since dental trauma occurs more frequently in young permanent teeth with incomplete root formation, the pulp vitality preservation is of

a great importance. A diagnostic method which is usually used for evaluating the pulp condition immediately after dental trauma is the electric pulp test, whose results are unsafe and do not reflect the true condition of the pulp.

Successful treatment and prevention of complications can be achieved if the treatment is implemented correctly and the principles of modern concepts of therapy are respected.

The success of therapy depends on multiple factors: time elapsed between trauma and emergency care, degree of development of permanent teeth roots, type of injury, mechanism of injury, condition of the alveolar bone, and the previous condition of the tooth crown, pulp and periodontal tissues, as well as the existence of possible orthodontic irregularities [6,7].

The aim of our study was to investigate the pulp vitality preservation after tooth injuries, depending on the type of injury and therapeutic procedure.

### Material and Methods

The research was conducted at the Department of Dentistry, Ward of Pediatric and Preventive Dentistry. The sample consisted of all patients who had been referred to the Department for a trauma of permanent teeth during the period 2005-2010. The study included 162 children and adolescents aged from 6 to 18 years (mean 8.2, SD 4.7) who had a trauma to 314 permanent teeth. Of the total number of patients, 47 (29.1%) were female and 115 (70.9%) were male.

Clinical data were obtained from the patients' records. These include all teeth with fractures and dislocations, with various degrees of root development. The study was performed as a retrospective clinical study, which analyzed patients' demographics, clinical examination, radiographs, types of treatments and check-ups.

#### Clinical examination

The data were collected on the number of injured permanent teeth, the type of injury and the pulp vitality immediately after dental injury and at the check-ups as well as on the success of therapy. The analysis was performed on the first examination and check-ups of traumatized teeth. Medical history was obtained and additional analyses of radiographs were performed. The detailed data on the results of vitality tests during the first examination were taken from the patients' dental records. Every positive result was considered as positive and the negative result of test vitality from the first examination was not recorded as negative until the therapeutic protocol or radiographic analysis confirmed the loss of vitality in the injured tooth.

#### Radiographic examination

All available radiographs were re-analyzed with in this research in order to determine the existence of periapical lesion changes which would either con-

firm the clinical diagnosis or be the only sign of pulp vitality loss.

#### The choice of treatment

Depending on the type of injury and degree of root development, the administration of different endodontic therapy was differently classified with respect to the fact whether the pulp vitality was preserved or pulp necrosis had occurred. All teeth subjected to direct overlays, partial pulp amputation, high amputation were considered to be vital until this kind of endodontic treatment was found unsuccessful and identified as such in the therapeutic protocol.

#### Check-up

The analysis of data obtained at the check-ups performed 7 days, 1 month, 3 months, 6 months and one year after the injury included the result of the electric pulp test (for the tooth with preserved pulp vitality) or information on the endodontic treatment (if an endodontic treatment was performed due to the pulp vitality loss between two check-ups).

#### Statistical Methods

Statistical analysis included standard methods of the descriptive statistical analysis (mean value, standard deviation). To determine the difference between the defined groups,  $\chi^2$  test was used with the significance level set at  $p < 0.05$ . The Kaplan-Meier survival analysis was used to determine the rate of pulp vitality preservation.

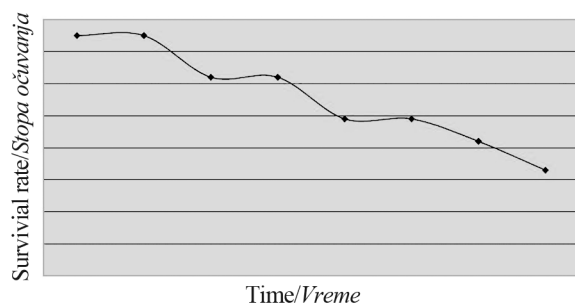
### Results

The most frequent type of injuries in permanent teeth were isolated fracture injuries (84, i.e. 51.8%), followed by isolated dislocation injuries (44, i.e. 27.2%) and combination of dislocation-fracture injuries (34 i.e. 20%). In the sample of 314 teeth, the most frequent type of injuries in permanent teeth was fractures (54.5%). Dislocation was less common (45.5%).

The initial examination and the check-up 7 days after the injury revealed 74 (out of 314) non vital teeth.

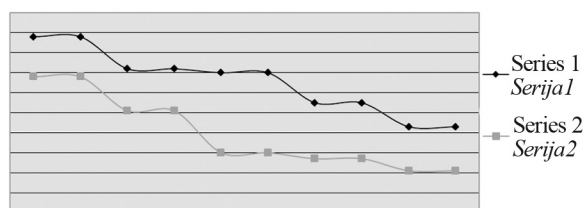
The pulp vitality loss was recorded in 115 out of 302 examined teeth, 137 out of 276 teeth, 152 of the 254 and 160 from 248 after one month, three months, six months and one year, respectively; whereas 66 teeth could not be included completely in testing because 53 patients were not available for all the check-ups. Having been analyzed, the rate of pulp vitality preservation was found to be 0.76 seven days after injury, 0.62 a month after injury, 0.50 three months after injury, 0.41 six months after injury and 0.32 one year after injury. The results of the Kaplan-Meier survival analysis of the rate of pulp vitality preservation after traumatic dental injuries are shown in **Graph 1**.

We analyzed the rate of pulp vitality preservation in relation to the type of dental injuries and noted the following results: of 74 teeth which were found to have lost pulp vitality during the first examination, 26 were with fracture, and 48 with dislocation trau-



**Graph 1.** Pulp vitality survival rate after traumatic dental injuries

**Grafikon 1.** Stopa očuvanja vitalnosti pulpe nakon povređivanja



**Graph 2.** Pulp vitality survival rate in regard to injury type

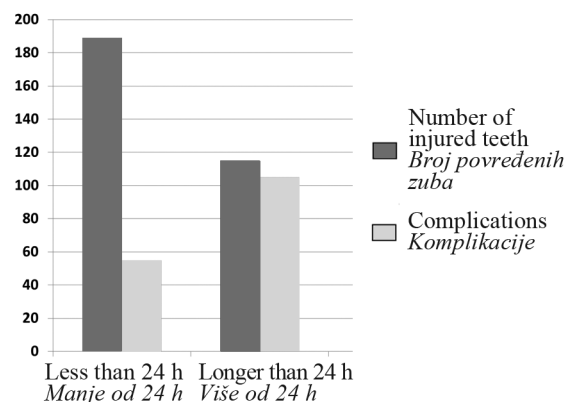
**Grafikon 2.** Stopa očuvanja vitalnosti pulpe u odnosu na vrstu povrede

matic dental injuries. A considerably lower rate of pulp vitality preservation after dislocation injuries in relation to the tooth fracture was statistically significant ( $p < 0.05$ ,  $\lambda^2$  test).

The rates of pulp vitality preservation in fractures and dislocation injuries were compared over the entire period and the results are presented in **Graph 2**.

Kaplan-Meier survival analysis revealed a statistically significant difference between the two curves ( $p < 0.05$ ).

Though different kinds of traumas have different optimal times for treatment, a period of 24 hours was considered as optimal. Consequently, 189 teeth



**Graph 3.** Optimal treatment time

**Grafikon 3.** Optimalno vreme tretmana

were treated in optimal time, and complications occurred in 55 of them, whereas 105 complications occurred in 115 teeth which had been treated 24 hours after trauma. The results are presented in **Graph 3**.

### Discussion

One of the basic drawbacks of this research lies in the study design. Longitudinal monitoring of patients is impossible in retrospective studies, so the percentage of respondents' dropout is high. Therefore, all the shortcomings of retrospective studies should be taken into account when the obtained results are being interpreted. The drawbacks of retrospective studies are presented in the majority of contemporary research which dealt with these issues [8-9]. On the other hand, retrospective analyses enable a complete analysis of a particular phenomenon on a sufficiently large sample of respondents.

This research included all cases of traumatic dental injuries referred to the Department of Dentistry of Vojvodina, Ward of Pediatric and Preventive Dentistry in the period from 2005 to 2010. The age of patients ranged from 6 to 18 years.

The results of this research are fully consistent with the majority of published epidemiological studies dealing with traumatic dental injuries, which reported a significantly higher incidence of injuries in boys than in girls and of fractures compared to dislocation dental injuries [9].

The analysis of treatment procedures in traumatic dental injuries leads to the conclusion that endodontic treatment is postponed even when the initial examination does not give a positive result with electric test. That is a reason why the survival analyses were performed taking into account the check-ups scheduled 7 days and a month after the initial examination. This approach is completely justified because there is evidence in literature that the pulp sensitivity returns after some time since the pulp is in a state of "local shock" immediately after the injury or several days afterwards and the negative response of the pulp does not mean the permanent loss of pulp vitality and indications for endodontic therapy [10,11].

In cases with persistent negative response, the endodontic treatment is almost always postponed until a definite sign of infection shows in the pulp, which is seen on radiograph as illumination in the periapical region [12].

The data analysis corroborates the fact that the pulp vitality loss is unavoidable in a relatively high percentage of injured teeth, regardless of the type and time of conducted treatment. The pulp vitality is preserved in only a half of the injured teeth three months after injury. Such a high rate of pulp necrosis is significantly higher in comparison with most of the published studies [8,13]. The reasons for such results should be sought in a big dissipation of the sample (66 injured teeth) and in the assumption that the majority of patients with complications complained

of them and asked for help, while those without symptoms often missed checkups.

We analyzed the pulp vitality preservation with regard to the type of dental injuries. There are no similar findings in literature; however, a significantly higher rate of pulp vitality preservation was recorded in our research after a dental fracture compared with dislocation injuries. The reasons for this finding are complex. The time elapsed between trauma and emergency care is a significant factor for the forecast of the pulp vitality preservation. Dental injuries are reasonably considered as emergency situations in dentistry, and treatment should be started as soon as possible. This is especially important in complex dislocation injuries and the fractures of the crowns with open pulp, where it is important to stop the bleeding as quickly as possible, to reposition the tooth, or to apply overlays directly on the open pulp. The explanation for a much higher incidence of pulp vitality preservation can be found in the nature of the injury.

In a dental fracture, the site of action of force is localized to a single isolated area of the tooth, and the clinician has no dilemma as to which treatment must be undertaken. In young permanent teeth with the exposed pulp after fracture and unfinished root development, surgical procedures of direct pulp capping methods and methods of vital amputation of the pulp tissue are most frequently used to preserve the tooth vitality and further development of root [14,15]. On the other hand, injuries in which the pulp vitality is rarely preserved (avulsion, high intrusion, extru-

sion of teeth) account for a great number of dislocation dental injuries. It is impossible to estimate the intensity of the "shock" in which the pulp is, thus, the treatment of root canal is sometimes delayed even in situations when it is practically impossible to establish revascularization. Our results show that in the case of dislocation of permanent teeth, the decision was made to postpone the endodontic treatment two to three months after dental injury. Endodontic therapy was indicated in cases when the pulp vitality was negative six to nine weeks after dental injury.

Although the pulp of young permanent teeth has a significantly greater reparative potential both for revascularization and for dentin genesis, the time elapsed between trauma and emergency care is often too long, which leads to irreversible inflammatory changes in the pulp of young permanent teeth and cause pulp necrosis and other complications. Our results are in full compliance with quotes from other studies [5,15,16].

### Conclusion

According to the obtained results we can conclude that loss OF the pulp vitality after traumatic dental injuries to permanent teeth is present in 68% of cases. The rate of loss of pulp vitality is greater after dislocation injury compared with fractures of dental hard tissues. The application of timely treatment is essential for the pulp vitality preservation.

### Literatura

- Zerman N, Cavalleri G. Traumatic injuries to permanent incisors. *Endod Dent Traumatol* 1993;9:61-4.
- Schatz JP, Joh JP. A retrospective study of dentoalveolar injuries. *Endod Dent Traumatol* 1994;10:11-4.
- Borsse'n E, Holm AK. Traumatic dental injuries in a cohort of 16-year-olds in northern Sweden. *Endod Dent Traumatol* 1997;13:276-80.
- Soprowski NJ, Allred EN, Needlmann HL. Luxation injuries of primary anterior teeth: prognosis and related correlates. *Pediatr Dent* 1994;16:96-101.
- Beloica B, Vulović M, Duggal M, Dimitrijević B. Povrede zuba. 2. proš. izd. Beograd: Stomatološki fakultet, Univerzitet u Beogradu; 2007.
- Beloica D. Povrede zuba. Beograd: Kuća štampe; 2007.
- Krasner P, Rankow HJ. New philosophy for the treatment of avulsed teeth. *Oral Surg Oral Med Oral Pathol* 1995;79:616-23.
- Hecova H, Tzigkounakis V, Merglova V, Netolicky J. A retrospective study of 889 injured permanent teeth. *Dent Traumatol* 2010;26(6):466-75.
- Blagojević D, Petrović B, Marković D. Possibilities of preventing traumatic dental injuries: a prospective study. *Med Pregl* 2005;58(11-12):567-71.
- Turkistani J, Hanno A. Recent trends in the management of dentoalveolar traumatic injuries to primary and young permanent teeth. *Dent Traumatol*. 2011;27(1):46-54.
- Mesaros SV, Trope M. Revascularization of traumatized teeth assessed by laser Doppler flowmetry: case report. *Endod Dent Traumatol*. 1997;13(1):24-30.
- Wigen TI, Agnalt R, Jacobsen I. Intrusive luxation of permanent incisors in Norwegians aged 6-17 years: a retrospective study of treatment and outcome. *Dent Traumatol* 2008;24:612-8.
- Oginni AO, Adekoya-Sofowora CA, Kolawole KA. Evaluation of radiographs, clinical signs and symptoms associated with pulp canal obliteration: an aid to treatment decision. *Dent Traumatol*. 2009;25(6):620-5.
- McDonald RE. Management of traumatic injuries to the teeth and supporting tissue. In: McDonald RE, ed. *Dentistry for the child and adolescent*. St. Louis: C.V. Mosby; 1974.
- Cvek M. Endodontic treatment of traumatized teeth. In: Andreasen JO, ed. *Traumatic injuries of the teeth*. 2<sup>nd</sup> ed. Copenhagen: Munksgaard; 1981.
- Flores MT, Andersson L, Andreasen JO, Bakland LK, Malmgren B, et al. Guidelines for the management of traumatic dental injuries. 1: fractures and luxations of permanent teeth. *Dent Traumatol* 2007;23(2):66-71.

Rad je primljen 14. IX 2012.

Recenziran 29. X 2012.

Prihvaćen za štampu 20. XII 2012.

BIBLID.0025-8105:(2013):LXVI:3-4:149-152.