

CASE REPORT

UDC: 616.314-053.2::616.314-001-06-08
DOI: 10.2298/VSP1308781C

Use of mineral trioxide aggregate in the treatment of traumatized teeth in children – Two case reports

Upotreba mineralnog trioksidnog agregata u lečenju povreda zuba kod dece

Bojana Četenović*, Dejan Marković*, Bojan Petrović†, Tamara Perić*,
Vukoman Jokanović‡

*Department of Paediatric and Preventive Dentistry, Faculty of Dentistry, University of Belgrade, Belgrade, Serbia; †Dentistry Clinic of Vojvodina, Faculty of Medicine, University of Novi Sad, Novi Sad, Serbia; ‡Vinča Institute for Nuclear Sciences, University of Belgrade, Belgrade, Serbia

Abstract

Introduction. Dental injuries in immature permanent teeth often result in endodontic complications. Apexification technique using calcium hydroxide is associated with certain flaws, such as long treatment time, the possibility of tooth fracture and incomplete calcification. The use of an apical plug employing mineral trioxide aggregate (MTA) is an alternative treatment option. **Case report.** We reported the successful treatment of 4 maxillary incisors (in a 7-year-old boy and a 10-year-old girl) with open apices and periapical lesions. Apical portions of the canals were filled with MTA plugs in both cases. Coronal parts of the root canals were filled with gutta-percha and sealer. Clinical findings were clear 6 months after the definite obturation with no pathological changes on the radiographs in both cases. **Conclusion.** The use of MTA for apical plugging appears to be a valid treatment option in traumatized immature teeth with endodontic complications.

Key words:

tooth fractures; root canal therapy; minerals; child.

Apstrakt

Uvod. Povrede zuba nezavršenog razvoja korena često su praćene endodontskim komplikacijama. Tehnika apeksifikacije u kojoj se koristi kalcijum-hidroksid povezuje se sa brojnim problemima, kao što su dugotrajnost lečenja, mogućnost frakture korena i neadekvatna kalcifikacija apeksne regije. Stvaranje apeksne barijere korišćenjem mineralnog trioksidnog agregata (MTA) predstavlja alternativu konvencionalnoj tehnici apeksifikacije. **Prikaz slučaja.** U radu su prikazana dva slučaja uspešnog lečenja hroničnog apeksnog parodontitisa na maksimalnim sekutićima (ukupno četiri) nezavršenog razvoja korena, prvi kod 7-godišnjeg dečaka, a drugi kod 10-godišnje devojčice. U oba slučaja apikalni deo korena zuba napunjen je MTA cementom. Koronarne partije korena zuba napunjene su gutaperkom i pastom. Šest meseci nakon lečenja nije bilo ni kliničkih ni radiografskih znakova patoloških promena. **Zaključak.** Upotreba MTA kao apeksne barijere pokazuje potencijal validne terapijske opcije kada su u pitanju povređeni zubi nezavršenog razvoja korena sa endodontskim komplikacijama.

Ključne reči:

zub, prelomi; zub, lečenje korenskog kanala; minerali; deca.

Introduction

The goal of endodontic treatment of traumatized immature teeth with periapical lesions is to achieve bone healing and form an adequate seal in the apical area¹. Apexification technique using calcium hydroxide is still the most widely accepted, but it is associated with certain difficulties, such as long treatment time, the possibility of tooth fracture and incomplete calcification²⁻⁵.

Mineral trioxide aggregate (MTA) has been used in paediatric dentistry as a pulp capping agent in young permanent teeth, as a pulpotomy medicament in primary and permanent teeth, as an apical barrier in immature non-vital teeth, in the coronal fragment of fractured roots, and as a repair material for perforation and resorptive defects^{6,7}.

The aim of this study was to present therapeutic application of MTA in the treatment of immature traumatized teeth in children.

Case report 1

A 7-year-old boy was referred to a control examination after the trauma he had experienced two months before. On that occasion the boy was diagnosed with enamel and dentine fracture without pulp involvement of permanent right central and lateral maxillary incisors, and extrusion and fracture of enamel and dentine without pulp involvement of permanent left central maxillary incisor (Figure 1a). Left central incisor was repositioned and the composite splint placed from left to right upper first primary molars. After removal of the splint, composite restorations were made. During the clinical examination after two months a buccal sinus tract in the apical part of vestibulum between the right central incisor and lateral incisor was noticed. The patient did not have any symptoms (Figure 1b).

central incisor after a month (Figure 1c). During the next 3 months, calcium hydroxide dressing was replaced monthly with the same canal. After 3 months, the same endodontic treatment was initiated on the left central incisor because of the appearance of dentoalveolar abscess (Figure 1d). During the therapy, the odontometry was performed (Figures 1e and f). Six months after the therapy was initiated, the teeth were obturated with MTA in the apical third, and the coronal part of the root canal was filled with a canal sealer and gutta-percha two days after placement of MTA (Figure 1g). After setting the materials, temporary fillings were removed and the coronal restorations were made with a composite material. The teeth were asymptomatic clinically and radiographies did not show pathological changes at the control examinations after one and six months (Figure 1h).

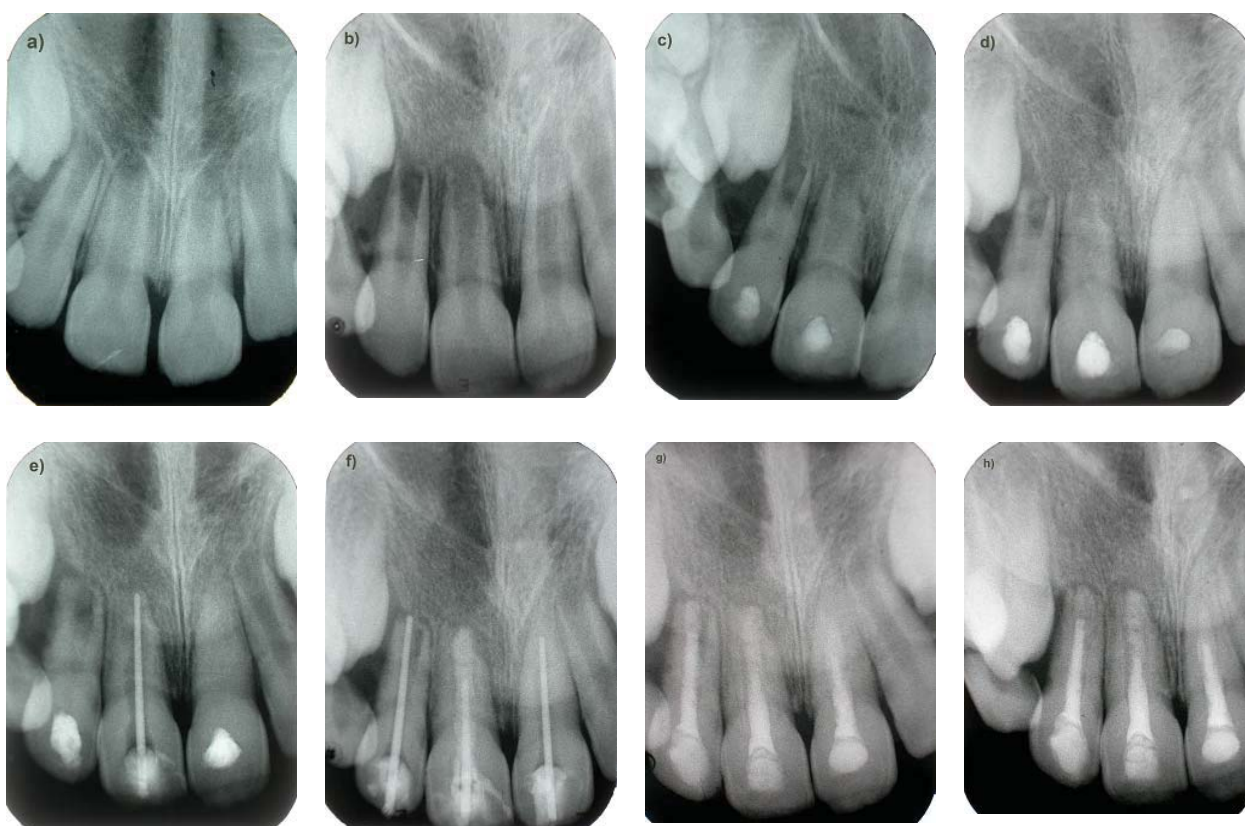

Fig. 1 – a) Radiographic view immediately after trauma; b) Radiographic view after 2 months; c) View after 4 months, calcium hydroxide dressing; d) Radiographic view after 6 months calcium hydroxide dressing; e) Odontometry of the tooth 11; f) Odontometry of the teeth 12, 21; placement of MTA in the apical third of the tooth 11; g) Definitive obturation with MTA, root canal sealer and gutta-percha; h) Radiographic follow-up after 6 months.

The initial treatment included trepanation, removal of the necrotic tissue, biomechanical debridement of the root canal with copious irrigation (1% sodium hypochlorite and saline), placement of the calcium hydroxide dressing into the root canal and temporary filling of the right lateral incisor. The same therapy regiment was used on the right

Case report 2

A 10-year-old girl without any complaint was referred for endodontic treatment of the permanent left central maxillary incisor which had been traumatized 4 years ago. Periapical radiography showed a large periapical lesion (Figure

2a). Clinical examination showed tenderness to percussion, while the vitality test (thermal pulp test) was negative. The therapy included trepanation, removal of the necrotic tissue, biomechanical debridement of the root canal with copious irrigation (1% sodium hypochlorite and saline) and drainage during two following days. After that period, calcium hydroxide dressing was placed into the root canal and the access cavity was closed with a temporary filling. Further therapy included replacement of calcium hydroxide each month (Figure 2b) during a 4 month period. The tooth was definitely obturated with the MTA apical plug, and the remaining portion of the root canal was filled with a canal sealer and gutta-percha 2 days after MTA placement (Figure 2c). After setting the materials, coronal restoration was made with a composite material. At the control examination after 3 months, the patient did not report any difficulties, and the tooth was asymptomatic clinically and radiographically (Figure 2d).

of MTA of 4 mm is the most effective in preventing apical leakage when compared with lesser thickness of the same material, which makes a 4 mm MTA layer the most adequate as a root-end filling material ¹⁰.

Dental trauma in permanent teeth is a very frequent clinical finding in children and adolescents. Most of these injuries happen before a complete root formation and can result in pulp inflammation and its necrosis, and consequent root resorption which compromises the further process of apexogenesis. Treatment of endodontic complications at that age is a challenge because of very thin walls of the root canal, a large pulp chamber and a widely open apex ².

A successful apexification depends on the creation of a calcified barrier from the cells that migrate from the surrounding periapical tissue and then differentiate influenced by specific cell signals into the cells that form the cement or the osteodentin matrix. The remains of the Hertwig sheath in this process are of a crucial importance because

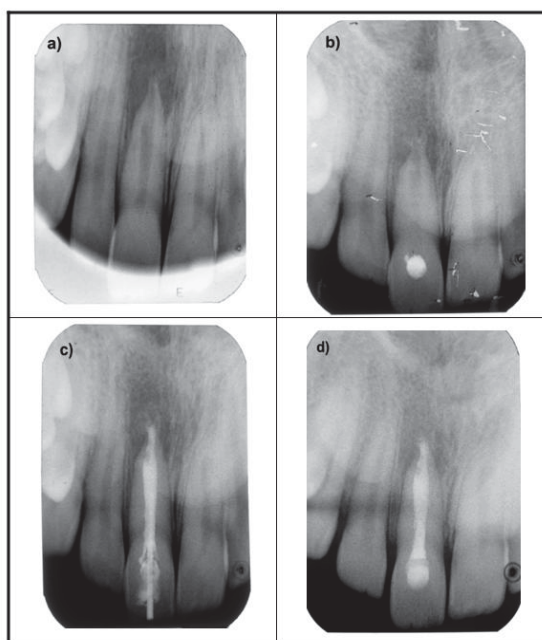


Fig. 2 – a) Radiographic view at the first visit, large periapical lesion; b) Radiographic view after 1 month, calcium hydroxide dressing; c) Radiographic view of completed root canal obturation (MTA, sealer and gutta-percha); d) Radiographic follow-up at 3 months, demonstrating osseous repair of periapical lesion.

Discussion

Mineral trioxide aggregate was developed and used for the first time at the Loma Linda University, California, USA, in the late 1990s, as a root-end filling material in surgical endodontic treatment ⁷. MTA is a mixture of Portland cement (3 CaO·SiO₂ and 2 CaO·SiO₂) and bismuth oxide and contains trace amounts of CaO, SiO, MgO, K₂SO₄ and Na₂SO₄ ⁶. In contrast to Portland cement, MTA is composed of smaller and more uniform particles and contains lower levels of potentially toxic heavy metals (Mg and Sr), oxide Fe, Al and K ^{6, 7}. MTA displays better marginal adaptation than amalgam and zinc oxide–eugenol-based root canal sealers ^{8, 9}. It has been shown that a layer

they can stay vital even after a complete necrosis of the pulp and initiate the growth of the root after endodontic treatment ². The traditional apexification technique with calcium hydroxide has been proved to be successful in forming a calcified barrier and confirmed throughout many years of practice ^{3–5}. However, treatment with calcium hydroxide comprises a great number of visits during a long period of time (3–21 months), the tendency towards cervical fracture of the treated tooth, and increased risk of reinfection of the root canal ^{4–5}.

The use of MTA as a technique of apexification has so far been documented in rare studies ^{11–13} and demands further research. The first case in the present paper confirms that MTA acts as an apical barrier which enables regeneration of

the periapical tissue and favours the apical obturation of the infected immature teeth. Radiographs of the cases presented in this study document the positive outcome of the therapy after the use of MTA and a definite obturation of the endodontic space. Positive reparatory processes are not compromised even in the case of slightly extruded material in the periapical space and, as Mente et al.¹¹ reported, that is a proof that MTA does not cause a strong inflammatory reaction of the periapical tissue and it is not an obstacle for its reparation after the therapy.

There is not enough reports, that is no consistency in the final results when we talk about antibacterial and antifungal activity of MTA¹⁴, and that is why before the definite obturation of the root canal with MTA, the application of calcium

hydroxide is recommended to eliminate the root canal flora. Finally, the high price of MTA cannot be neglected, which presents a limiting factor for its everyday clinical use in the dental practice.

Conclusion

MTA is an effective therapy when it comes to young infected teeth that have suffered trauma, especially in the case of teeth with immature root development. Advantages of this material are a significant decrease in therapy duration and good apical plugging. In addition to that, having stated the advantages, further clinical research with a long observational period is still needed.

R E F E R E N C E S

1. *Al Ansary MA, Day PF, Duggal MS, Brunton PA.* Interventions for treating traumatized necrotic immature permanent anterior teeth: inducing a calcific barrier and root strengthening. *Dent Traumatol* 2009; 25(4): 367–79.
2. *Ghose LJ, Baghdady VS, Hikmat YM.* Apexification of immature apices of pulpless permanent anterior teeth with calcium hydroxide. *J Endod* 1987; 13(6): 285–90.
3. *Anderson JO, Farik B, Munksgaard EC.* Long-term calcium hydroxide as a root canal dressing may risk of root fracture. *Dent Traumatol* 2002; 18(3): 134–7.
4. *Andreasen JO, Munksgaard EC, Bakland LK.* Comparison of fracture resistance in root canals of immature sheep teeth after filling with calcium hydroxide or MTA. *Dent Traumatol* 2006; 22(3): 154–6.
5. *Hatibovic-Kofman S, Raimundo L, Zheng L, Chong L, Friedman M, Andreasen JO.* Fracture resistance and histological findings of immature teeth treated with mineral trioxide aggregate. *Dent Traumatol* 2008; 24(3): 272–6.
6. *Jokanovic V, Colovic B, Zivkovic S, Zivojinovic V, Markovic D.* Mineral Trioxide Aggregate as Material of Choice in Endodontic Therapy. *Serbian Dent J* 2011; 58(2): 97–107.
7. *Torabinejad M, Hong CU, McDonald F, Pitt Ford TR.* Physical and chemical properties of a new root-end filling material. *J Endod* 1995; 21(7): 349–53.
8. *Fridland M, Rosado R.* MTA solubility: a long term study. *J Endod* 2005; 31(5): 376–9.
9. *Shipper G, Grossman ES, Botha AJ, Cleaton-Jones PE.* Marginal adaptation of mineral trioxide aggregate (MTA) compared with amalgam as a root-end filling material: a low-vacuum (LV) versus high-vacuum (HV) SEM study. *Int Endod J* 2004; 37(5): 325–36.
10. *Valois RA, Costa DE Jr.* Influence of the thickness of mineral trioxide aggregate on sealing ability of root-end fillings in vitro. *Oral Surg Oral Med Oral Pathol* 2004; 97: 108–11.
11. *Mente J, Hage N, Pfefferle T, Koch MJ, Dreyhaupt J, Staehle HJ, et al.* Mineral trioxide aggregate apical plugs in teeth with open apical foramina: a retrospective analysis of treatment outcome. *J Endod* 2009; 35(10): 1354–8.
12. *Koh ET, Torabinejad M, Pitt Ford TR, Brady K, McDonald F.* Mineral trioxide aggregate stimulates a biological response in human osteoblasts. *J Biomed Mater Res* 1997; 37(3): 432–9.
13. *Koh ET, McDonald F, Pitt Ford TR, Torabinejad M.* Cellular response to mineral trioxide aggregate. *J Endod* 1998; 24(8): 543–7.
14. *Al-Hazaimi K, Al-Shanal TA, Naghsbandi J, Oglesby S, Dimon JS, Rotstein I.* Antibacterial effect of two mineral trioxide aggregate (MTA) preparations against *Enterococcus faecalis* and *Streptococcus sanguis* in vitro. *J Endod* 2006; 32(11): 1053–6.

Received on December 13, 2011.

Revised on May 9, 2012.

Accepted on May 10, 2012.