

Direct pulp capping with novel nanostructural materials based on calcium silicate systems and hydroxyapatite

Marijana Popović Bajić¹, Violeta Petrović¹, Vanja Opačić Galić¹, Vesna Danilović¹, Vukoman Jokanović², Branislav Prokić³, Bogomir Bolka Prokić³, Slavoljub Živković¹

¹Department for Restorative Dentistry and Endodontics, University of Belgrade, School of Dental Medicine, Belgrade, Serbia;

²University of Belgrade, Institute for Nuclear Sciences "Vinča", Belgrade, Serbia;

³Department for Surgery, Orthopedic and Ophthalmology, Faculty of Veterinary Medicine, University of Belgrade, Belgrade, Serbia

SUMMARY

Introduction Direct pulp capping is an important therapeutic method that has goal to provide formation of dentin bridge and healing process of the pulp. The aim of this study was to investigate the effects of new nanostructural materials based on calcium silicate systems and hydroxyapatite on exposed dental pulp in Vietnamese pigs.

Material and Methods The study was conducted on 30 teeth of two Vietnamese pigs (*Sus scrofa verus*). On buccal surfaces of incisors, canines and first premolars, class V cavities were prepared with a small round bur and pulp horn was exposed. In the first experimental group (10 teeth) the perforation was covered with new nanostructural material based on calcium silicate systems (CS). In the second experimental group, the perforation was covered with compound of calcium silicate systems and hydroxyapatite (HA-CS) (10 teeth). In the control group, exposed pulp was covered with Pro Root MTA[®] (Dentsply Tulsa Dental, Johnson City, TN, USA) (10 teeth). All cavities were restored with glass ionomer cement (GC Fuji VIII, GC Corporation, Tokyo, Japan). Observation period was 28 days. After sacrificing the animals, histological preparations were done to analyze the presence of dentin bridge, inflammatory reaction of the pulp, pulp tissue reorganization and the presence of bacteria.

Results Dentin bridge was observed in all teeth (experimental and control groups). Inflammation of the pulp was mild to moderate in all groups. Neoangiogenesis and many odontoblast like cells responsible for dentin bridge formation were detected. Necrosis was not observed in any case, neither the presence of Gram-positive bacteria in the pulp.

Conclusion Histological analysis indicated favorable therapeutic effects of new nanostructural materials based on calcium silicate systems and hydroxyapatite for direct pulp capping in teeth of Vietnamese pigs.

Keywords: direct pulp capping; calcium silicate; hydroxyapatite; MTA; dentin bridge

INTRODUCTION

Direct pulp capping and preservation of pulp vitality are very important therapeutic methods, especially in young patients and teeth with complex multi canal systems [1, 2]. Numerous studies have confirmed calcium hydroxide as gold standard for direct pulp capping since its introduction in dental practice in 1920 [2]. High pH provides stimulating effect on odontoblasts that initiate production of tertiary dentin and pulp vitality preservation. However, the success rate of calcium hydroxide as direct pulp capping medicament in published papers varies from 31% to 100% [3–6]. Due to inadequate bond of calcium hydroxide to exposed pulp that degrades over time, porosity of new dentin bridge and appearance of internal resorption there is need to find more efficient material [3, 7, 8].

In the past twenty years, great attention was given to mineral trioxide aggregate ProRoot MTA[®] (Dentsply Tulsa Dental, Johnson City, TN, USA) for direct pulp capping and it has been shown to induce complete dentin bridge

formation with no signs of pulp inflammation [9, 10]. Numerous studies have confirmed its biocompatibility, antimicrobial effect, good sealing ability and good physical and chemical properties [11, 12]. It is hydrophilic and therefore can be used in wet operating field and the presence of blood. It has also been confirmed that the thickness of dentinal bridge increased after pulp capping using MTA compared to calcium hydroxide [13, 14, 15]. MTA shows excellent properties as material for direct pulp capping and successfully replaces calcium hydroxide. It does not cause local necrosis of the pulp, while chronic inflammation of the pulp occurs [15]. MTA causes functional and cytological changes in pulp cells as well as their transformation to odontoblast like cells that produce reparative dentin on the surface of the pulp [16, 17]. However, MTA is non-stable as powder immediately after package opening, and other disadvantages include high price on the market and long setting time. The manufacturer specifies setting time of 10 minutes, but study of Torabinejad et al. [18] founds setting time between 2 and 4 hours. Con-

temporary research aimed to find material for direct pulp capping that would have all good properties of MTA, but also overcome its limitations.

Hydroxyapatite is one of the most commonly used calcium phosphate materials in medicine and dentistry. Biocompatibility of hydroxyapatite is closely related to its chemical composition, similar to dental and bony tissues. However, inferior mechanical properties limit the use of hydroxyapatite as an endodontic material. Recent studies have focused on new and modified formulations of calcium-phosphate-based biomaterials with improved mechanical and favorable biological properties [19–23].

Recently, two non-commercial new materials based on calcium silicates and hydroxyapatite have been synthesized using original recipe of V. Jokanović. One material is a calcium silicate system that consists of tricalcium and dicalcium silicates (CS) and the other one is a mixture of this calcium silicate system and hydroxyapatite in 1:2 ratio (HA-CS). Barium sulphate is added for radiopacity. These materials are synthesized using two combined techniques – a hydrothermal sol-gel method and self-propagating combustion waves. This way two nanostructural materials containing agglomerates, several micrometers in size, formed by smaller particles, 117-447 nm in size, that contain even smaller building blocks, 20 nm-sized crystallites were obtained [24]. Particle size affects cement hydration and consequently setting time and final quality of the cement. Nanoparticles improve particle activity and shorten setting time to 10 minutes (CS) and 15 minutes (HA-CS) [24].

The aim of this study was to examine the effect of new nanostructural materials based on active calcium silicate systems and hydroxyapatite (CS and HA-CS) on direct pulp capping of exposed pulp in Vietnamese pigs.

MATERIAL AND METHODS

The research was conducted at the Faculty of Veterinary Medicine, University of Belgrade, with the approval of the Ethics Committee of the School of Dental Medicine, University of Belgrade. The experiment included 30 teeth of two Vietnamese pigs (*Sus scrofa verus*), aged 24 months and weight about 25 kg. The study procedure complied with the protocol of the European Good Laboratory Practice (86/609/EEC) that involved the implementation of main principles of asepsis and antisepsis, conducting the experiment in the minimum required time without physical and mental suffering of animals (International Organization for Standardization, 1997). ProRoot MTA® (Dentsply Tulsa Dental, Johnson City, TN, USA) was used as control material.

Experimental procedure

All animals were premedicated with atropine in the dose of 0.03-0.04 mg/kg, and after 15 minutes they were introduced to general anesthesia using xylazine in the dose 1.5-2 mg/kg and ketamine 20-25 mg/kg intramuscularly.

After rubber dam placement, the teeth were cleaned with 70% ethanol.

On the buccal surfaces of incisors, canines and first premolars class V cavities were prepared using round carbide burs and continuous cooling with saline. Using a small round bur pulp chamber was exposed and bleeding controlled with sterile cotton pellet. Material was prepared and applied on the perforation. Teeth in the right quadrants of upper jaws in both experimental animals (6 incisors, two canines and 2 premolars) received CS. The same number of teeth in left quadrants of upper jaws in both animals received HA-CS. MTA was applied in the right quadrants of lower jaws in both Vietnamese pigs on 6 incisors, two canines and two premolars. All cavities were restored with glass ionomer cement (GC Fuji VIII, GC Corporation, Tokyo, Japan). At the end of the procedure, the animals were given an analgesic dose of butorphanol in the dose of 0.1-0.2 mg/kg. After recovery the animals were kept in individual cages in breeding system. Observational period was 28 days.

After 4 weeks animals were sacrificed after introducing general anesthesia and i.v. administration of sodium phenobarbital in the dose of 100 mg/kg. The jaws were cut into block sections and tissue was fixed and prepared for microscopic analysis.

Histological procedure

Tissue for histological analysis was taken from every block of the experimental sample including the tooth and surrounding bone. Samples were collected respecting the ISO criteria (Technical Report 7405) 28 days after the exposure of the pulp and direct capping. The material for histological analysis was fixed in 10% formalin, decalcified in 10% formic acid (pH=5) and molded in paraffin. Serial sections were made in mesio-distal direction in the thickness of 4 µm. The samples were stained with hematoxylin and eosin, by method of Goldner and Gram (for the microscopic identification of bacteria) and analyzed using light microscope.

Histological criteria for the evaluation of pulp reaction were used by the methodology of Shayegan et al. [25]. Formation of dentin bridge (A) (thickness, localization, structure, continuity with surrounding dentin), morphological reorganization of pulp cells (B), inflammatory reaction of pulp (C) (chronic or acute, intensity and localization of inflammation) and presence of bacteria (D) were analyzed. These parameters were monitored according to the International Organization for Standardization (International Organization for Standardization) and published criteria by Mjör in 1983 [26].

RESULTS

Histological analysis showed that dentin bridge was formed in all samples of the experimental and control groups (Table 1). Newly formed dentin had characteristics of reparative dentin with or without small number of ir-

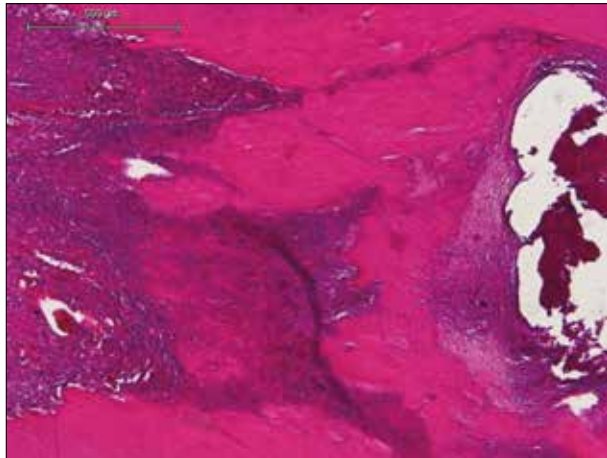
Table 1. Histological analysis of dental pulp after application of the test materials**Tabela 1.** Rezultati histološke analize stanja zubne pulpe nakon primene testiranih materijala

Material Materijal	A. Dentin bridge Dentinski mostić				B. Tissue reorganization Reorganizacija tkiva				C. Pulp inflammation Inflamacija pulpe				D. Bacterial presence Prisustvo bakterija			
	0	1	2	3	0	1	2	3	0	1	2	3	0	1	2	3
CS	0	5	1	4	1	9	0	0	0	8	2	0	6	4	0	0
HA-CS	0	3	1	6	1	9	0	0	0	7	1	0	5	5	0	0
MTA	0	6	0	4	2	8	0	0	0	7	3	0	7	3	0	0


CS – calcium silicate

HA-CS – hydroxyapatite and calcium silicate

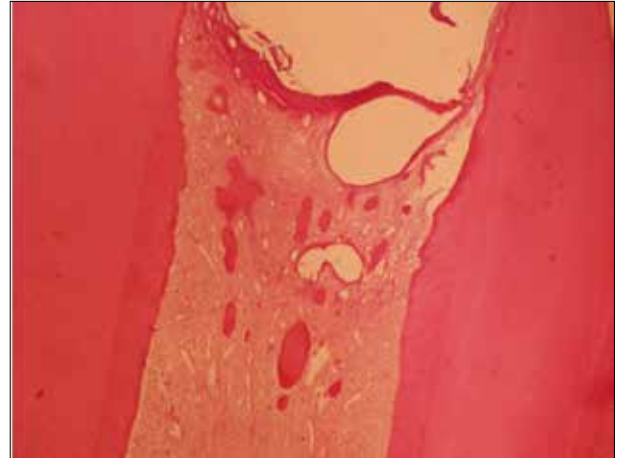
MTA – mineral trioxide aggregate

**Figure 1.** Complete dentin bridge after direct pulp capping with HA-CS. Newly formed dentin completely closes preparation region of the pulp chamber and it is very similar to original dentin. Particles of HA-CS in the area of perforation are visible (HE, 40x).

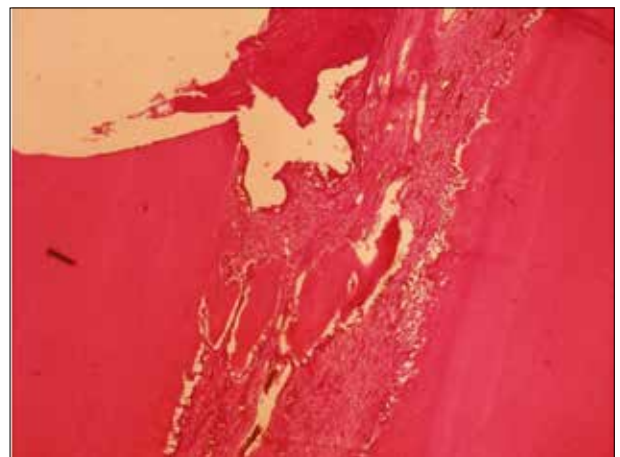
Slika 1. Kompletan dentinski most nakon direktnog prekrivanja pulpe materijalom HA-CS. Novostvoreni dentin potpuno zatvara predeo perforacije komore pulpe i nalik je pravom dentinu. Na slici se mogu uočiti ostaci materijala HA-CS u predelu perforacije cavuma dentis (HE, 40x).

**Figure 2.** Complete dentin bridge after direct pulp capping with CS. Newly formed dentin completely closes the preparation region of the pulp chamber. Particles of HA-CS are visible in the area of perforation (Goldner trichrome, 40x)

Slika 2. Kompletan dentinski most nakon direktnog prekrivanja pulpe materijalom CS. Novostvoreni dentin potpuno zatvara predeo perforacije komore pulpe. Na slici se mogu uočiti ostaci materijala HA-CS u predelu perforacije cavuma dentis (Goldner trihrom, 40x)

**Figure 3.** Dentin islets after direct pulp capping with CS. Newly formed dentin is in the form of dentin islands and tends to close perforation of cavum dentis. Completely preserved pulp tissue without inflammatory reaction can be seen (HE, 40x).

Slika 3. Dentinska ostrvca nakon direktnog prekrivanja pulpe materijalom CS. Novostvoreni dentin u vidu dentinskih ostrvaca teži da zatvori perforaciju cavuma dentis. Vidi se potpuno očuvano pulpno tkivo bez zapaljenske reakcije (HE, 40x).

**Figure 4.** Dentin islets after direct pulp capping with HA-CS. Three dentin islets that almost completely closed cavum dentis and signs of neoangiogenesis in the form of newly created blood vessels can be seen (HE, 40x).

Slika 4. Dentinska ostrvca nakon direktnog prekrivanja pulpe materijalom HA-CS. Na slici se mogu uočiti tri dentinska ostrvca koja skoro u potpunosti zatvaraju perforaciju cavuma dentis i znaci neoangiogeneze u vidu novostvorenih krvnih sudova (HE, 40x).

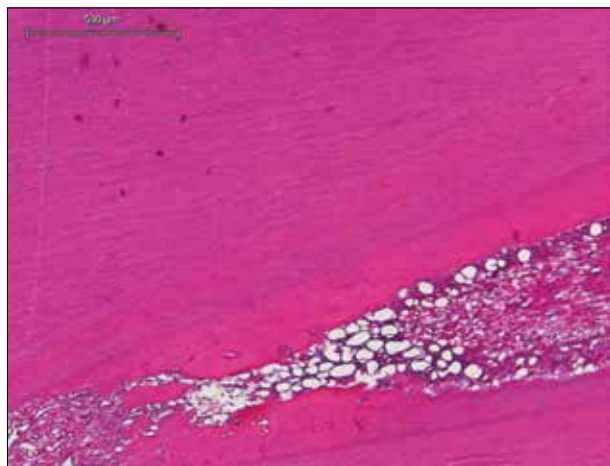


Figure 5. Lateral dentin bridge after direct pulp capping with HA-CS. Newly laterally deposited dentin that narrows pulpal space and mild inflammatory reaction with the presence of inflammatory cells can be found in the area of the perforation only (HE, 40×).

Slika 5. Lateralni dentinski most nakon direktnog prekrivanja pulpe materijalom HA-CS. Na slici se može videti novostvoreni dentin lateralno deponovan koji sužava pulpni prostor. Blaga inflamatorna reakcija sa prisutnim ćelijama zapaljenja samo u predelu perforacije (HE, 40×).

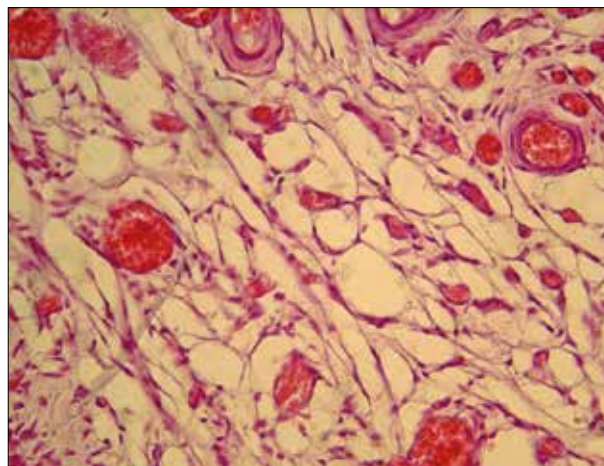


Figure 6. Signs of neoangiogenesis and stasis in dental pulp. This finding was probably related to the chemical properties of the capping material and mechanical trauma during cavity preparation, rather than the presence of bacterial infection (HE, 400×).

Slika 6. Znaci neoangiogeneze i staze u pulpnom tkivu. Ovakav nalaz je verovatno posledica hemijskog sastava materijala za direktno prekrivanje i mehaničke traume tokom preparacije, pre nego posledica prisustva bakterija (HE, 400×).

regular dentinal tubules that were in continuity with surrounding dentin. Complete dentin bridge that closed pulp perforation was noted in 6 cases with HA-CS (Figure 1). Complete dentin bridge was noted in 4 cases with CS and 4 teeth with control material (MTA) (Figure 2). Odontoblast like cells associated with newly formed dentin were found below complete dentin bridge. The original odontoblasts were positioned peripherally. They were identified through their regular palisade arrangement, eosinophilic cytoplasm and basal nucleus alignment. Incomplete dentin bridge in the form of dentin islets was observed in 5 teeth in the group of CS (Figure 3) and 3 teeth in the group with HA-CS (Figure 4). In the control group dentin islets were noted in 6 teeth. Continuous reparative dentin that extends along the lateral walls of dentin was recorded in 1 case in the group of CS and 1 case in the group of HA-CS (Figure 5), while this form of dentin was not registered in the samples with control material (MTA).

Fully preserved pulp tissue was observed in only one case in each experimental group and two cases with MTA (Figure 3). Pulp disorganization characterized by the appearance of odontoblast like cells and their hyperactivity was observed in most samples (9 teeth in each experimental group and 8 teeth in the control group), where in the central part of the pulp the presence of venous stasis, hemorrhage and inflammation was observed (Figure 5). In most of these cases neoangiogenesis with proliferation of existing and creation of new blood vessels was observed indicating healing process and complete revascularization (Figure 6). Complete disorganization of the pulp tissue was not registered in the samples of either experimental or control groups. Necrosis was not observed in any case.

Histological analysis after 4 weeks revealed that the experimental pulp capping materials in most cases caused mild to moderate chronic inflammation of pulp tissue (Figure 5). Severe inflammation or abscesses were not

observed in any sample. Mild inflammation was present in 8 samples in the group with CS and 7 samples in the group with HA-CS and MTA (Figure 5). Moderate inflammation with cellular proliferation present both in coronal and radicular pulp was observed in 2 teeth of the CS group and 1 tooth in the HA-CS group. Similar number of inflammatory cells was registered in 3 samples after direct pulp capping with the control material (MTA).

Gram staining did not detect any gram-positive bacteria in the pulp of all samples. Small number of bacteria in dentinal tubules was observed in 4 teeth with CS, 3 teeth with HA-CS, while bacteria in dentin tubules were registered in 3 samples with MTA.

DISCUSSION

The current experimental study was performed on permanent teeth of Vietnamese pigs that are by their morphology very similar to human teeth. Previous studies with new materials were conducted on teeth in dogs [17, 27], deciduous and permanent teeth of pigs [25, 28] as well as monkeys [29]. An important advantage in working with animals is that experiment can be carried out on large number of teeth for the same time period and the effect of various materials can be checked at the same time.

Results of the current study showed similar findings in the control and experimental groups. The process of reparative dentinogenesis and complete or partial closure of perforations with dentin bridge was considered good therapeutic result. Dentin bridge was observed in all teeth where perforations were capped using new synthesized nanostructural materials based on calcium silicate systems and hydroxyapatite. Similar results were confirmed by the study of Laurent et al. [30], where favorable therapeutic effect of calcium silicate systems was explained

by significant release of TGF- β 1 from the pulp cells that stimulated odontoblasts to increase their activity and activate reparative dentinogenesis.

Results of the current study where the pulp was capped with MTA also showed the presence of dentin bridge in all samples, which is consistent with similar experimental study in pigs done by Shayegana et al. [25].

In most teeth of both groups, odontoblasts were observed just below dentin bridge with major or minor structural changes that ranged from mild to complete disorganization. It is likely that these cells are not true odontoblasts, but odontoblast like cells (although for definitive identification additional immunohistochemical analysis is required). These cells, similarly to true odontoblasts have elongated shape, palisade orientation and basal nucleus alignment [31]. They have ability to produce extracellular matrix that after mineralization becomes complete or incomplete dentin bridge or islands that tend to establish contact with side dentin walls to close and preserve exposed pulp.

In most samples in the MTA group reorganization of the tissue below the perforation was observed (hyperactivity of odontoblast like cells and altered cell morphology compared to odontoblasts). This is also confirmed by the study of Tziafas et al. [17] performed on dogs. Correlation between the number of odontoblast like cells, the thickness of the bridge and preservation of deeper parts of the pulp was found. With increased number of these cells, the thickness of dentin bridge is increasing and radicular part of the pulp remains vital [32]. In the experimental groups and in the group with MTA necrosis was not observed in any sample. In the experimental study of Tabarsi et al. [27] on dogs after direct capping with MTA necrosis was present in 22.7% of samples. Different findings of these two studies can be explained by the fact that in the study of Tabarsi et al. MTA was placed after pulpotomy was performed whereas in the current study only small exposed surface of the pulp was covered with MTA.

In the most teeth of both experimental groups mild inflammation was observed, suggesting biocompatibility of the materials [33]. Acute inflammation and necrosis of the pulp was not observed in any sample. Good marginal seal achieved with glass ionomer cements and aseptic conditions as well as good immune status of experimental animals can explain this.

The results of our study demonstrated the presence of inflammatory cells in the coronal and radicular part of the pulp. In the control group where pulp was capped with MTA only few samples showed the presence of lymphocytes, plasma cells and macrophages, which is consistent with the findings of other authors [25, 27].

Therapeutic effects were similar in the experimental and control groups, indicating that new nanostructured materials based on calcium silicate cements and hydroxyapatite have favorable effects on reparative activities of the pulp primarily due to their physical and chemical properties.

After application of new materials (CS and HA-CS) and MTA neoangiogenesis was observed, indicating regenerative processes in the pulp and successful tissue remodel-

ing. Similar results obtained by both tested materials can be explained by similar chemical composition (dicalcium and tricalcium silicate make the most of the material). On the other hand Murray et al. suggested that for dentinogenesis the most important is preservation of pulp and odontoblasts, absence of infection and necrosis but not the type of material [31].

CONCLUSION

Reparation of pulp exposure was successful in the experimental and control groups. In most teeth reparative dentinogenesis resulted in dentin bridge formation and preservation of functional and morphological integrity of the pulp. Histological analysis indicated favorable therapeutic effects of new nanostructured materials based on active calcium silicate systems and hydroxyapatite that were similar to MTA after direct pulp capping of pulp in Vietnamese pigs.

REFERENCES

1. Witherspoon DE, Small JC, Harris GZ. Mineral trioxide aggregate pulpotomies: a case series outcomes assessment. *J Am Dent Assoc.* 2006; 37:610–8. [DOI: 10.14219/jada.archive.2006.0256] [PMID: 16739540]
2. McDonald R, Avery D, Dean J. Treatment of deep caries, vital pulp exposure and pulpless teeth. In: *Dentistry for the Child and Adolescent.* 8th ed. St. Louis: Mosby Co; 2004. p. 389–412.
3. Schröder U. A 2-year follow-up of primary molars, pulpotomized with a gentle technique and capped with calcium hydroxide. *Scand J Dent Res.* 1978; 86(4):273–8. [DOI: 10.1111/j.1600-0722.1978.tb00628.x] [PMID: 279959]
4. Waterhouse PJ. Formocresol and alternative primary molar pulpotomy medicaments: a review. *Endod Dent Traum.* 1995; 11(4):157–62. [PMID: 7588337]
5. Waterhouse PJ, Nunn JH, Withworth JM. An investigation of the relative efficacy of Buckley's Formocresol and calcium hydroxide in primary molar vital pulp therapy. *Br Dent J.* 2000; 188(1):32–6. [PMID: 10697342]
6. Percinoto C, Castro AM, Pinto LMCP. Clinical and radiographic evaluation of pulpotomies employing calcium hydroxide and trioxide mineral aggregate. *Gen Dent.* 2006; 54(4):258–61. [PMID: 16903198]
7. Heilig J, Yates J, Siskin M, McKnight J, Turner J. Calcium hydroxide pulpotomy for primary teeth: a clinical study. *J Am Dent Assoc.* 1984; 108(5):775–8. [DOI: 10.14219/jada.archive.1984.0049] [PMID: 6588119]
8. Tunc ES, Saroglu I, Sari S, Günhan O. The effect of sodium hypochlorite application on the success of calcium hydroxide pulpotomy in primary teeth. *Oral Surg Oral Med Oral Pathol Oral Radiol Endod.* 2006; 102(2):22–6. [DOI: 10.1016/j.tripleo.2005.12.013] [PMID: 16876040]
9. Faraco IM Jr, Holland R. Histomorphological response of dogs dental pulp capped with white mineral trioxide aggregate. *Braz Dent J.* 2004; 15:104–8. [DOI: 10.1590/S0103-64402004000200004]
10. Simon S, Cooper P, Smith A, Picard B, Ifi CN, Berdal A. Evaluation of a new laboratory model for pulp healing: preliminary study. *Int Endod J.* 2008; 41(9):781–90. [DOI: 10.1111/j.1365-2591.2008.01433.x] [PMID: 18798922]
11. Parirokh M, Torabinejad M. Mineral trioxide aggregate: a comprehensive literature review – Part I: Chemical, physical and antibacterial properties. *J Endod.* 2010; 36(1):16–27. [DOI: 10.1016/j.joen.2009.09.006] [PMID: 20003930]

12. Torabinejad M, Parirokh M. Mineral trioxide aggregate: comprehensive literature review – Part II: Leakage and biocompatibility investigations. *J Endod.* 2010; 36(2):190–202. [DOI: 10.1016/j.joen.2009.09.010] [PMID: 20113774]
13. Aeinehchi M, Eslami B, Ghanbari M, Saffar AS. Mineral trioxide aggregate (MTA) and calcium hydroxide as pulp-capping agents in human teeth: a preliminary report. *Int Endod J.* 2003; 36(3):225–31. [DOI: 10.1046/j.1365-2591.2003.00652.x] [PMID: 12657149]
14. Camilleri J, Pitt Ford TR. Mineral trioxide aggregate: a review of the constituents and biological properties of the material. *Int Endod J.* 2006; 39(10):747–54. [DOI: 10.1111/j.1365-2591.2006.01135.x] [PMID: 16948659]
15. Nair PNR, Duncan HF, Pitt Ford TR, Luder HU. Histological, ultrastructural and quantitative investigations on the response of healthy human pulps to experimental capping with mineral trioxide aggregate: a randomized controlled trial. *Int Endod J.* 2008; 41(2):128–50. [DOI: 10.1111/j.1365-2591.2007.01329.x] [PMID: 17956562]
16. Andelin WE, Shabahang S, Wright K, Torabinejad M. Identification of hard tissue after experimental pulp capping using dentin sialoprotein (DSP) as a marker. *J Endod.* 2003; 29(10):646–50. [DOI: 10.1097/00004770-200310000-00008] [PMID: 14606787]
17. Tziafas D, Pantelidou O, Alvanou A, Belibasakis G, Papadimitriou S. The dentinogenic effect of mineral trioxide aggregate (MTA) in short-term capping experiments. *Int Endod J.* 2002; 35(3):245–54. [DOI: 10.1046/j.1365-2591.2002.00471.x] [PMID: 11985676]
18. Torabinejad M, Pitt Ford TR, McKendry DJ, Abedi HR, Miller DA, Kariyawasam SP. Histologic assessment of mineral trioxide aggregate as a root-end filling in monkeys. *J Endod.* 1997; 23(4):225–8. [DOI: 10.1111/j.1365-2591.2009.01556.x] [PMID: 9594770]
19. Huan Z, Chang J. Calcium phosphate silicate composite bone cement: self-setting properties and in vitro bioactivity. *J Mater Sci Mater Med.* 2009; 20(4):833–41. [DOI: 10.1007/s10856-008-3641-9] [PMID: 19034622]
20. Khashaba RM, Moussa MM, Chutkan NB, Borke JL. The response of subcutaneous connective tissue to newly developed calcium phosphate-based root canal sealers. *Int Endod J.* 2011; 44(4):342–52. [DOI: 10.1111/j.1365-2591.2010.01836.x] [PMID: 21272042]
21. Damas BA, Wheeler MA, Bringas JS, Hoen MM. Cytotoxicity comparison of mineral trioxide aggregates and EndoSequence bioceramic root repair materials. *J Endod.* 2011; 37(3):372–5. [DOI: 10.1016/j.joen.2010.11.027] [PMID: 21329824]
22. Modareszadeh MR, Di Fiore PM, Tipton DA, Salamat N. Cytotoxicity and alkaline phosphatase activity evaluation of EndoSequence root repair material. *J Endod.* 2012; 38(8):1101–5. [DOI: 10.1016/j.joen.2012.04.014] [PMID: 22794214]
23. Chen YZ, Lu XY, Liu GD. A novel root-end filling material based on hydroxyapatite, tetracalcium phosphate and polyacrylic acid. *Int Endod J.* 2013; 46(6):556–64. [DOI: 10.1111/iej.12028] [PMID: 23190302]
24. Opačić-Galić V, Petrović V, Živković S, Jokanović V, Nikolić B, Knežević-Vukčević J, et al. New nanostructural biomaterials based on active silicate systems and hydroxyapatite: characterization and genotoxicity in human peripheral blood lymphocytes. *Int Endod J.* 2013; 46(6):506–16. [DOI: 10.1111/iej.12017] [PMID: 23173688]
25. Shayegan A, Petein M, Abbeele AV. The use of beta-tricalcium phosphate, white MTA, white Portland cement and calcium hydroxide for direct pulp capping of primary pig teeth. *Dent Traum.* 2009; 25(4):413–9. [DOI: 10.1111/j.1600-9657.2009.00799.x] [PMID: 19519859]
26. Mjör IA. Biological and clinical properties. In: Mjör IA, editor. *Dental Materials, Biological Properties and Clinical Evaluation.* Boca Raton: CRC Press; 1983. p. 91–121.
27. Tabarsi B, Parirokh M, Eghbal MJ, Haghdoost AA, Torabzadeh H, Asgary S. A comparative study of dental pulp response to several pulpotomy agents. *Int Endod J.* 2010; 43(7):565–71. [DOI: 10.1111/j.1365-2591.2010.01711.x] [PMID: 20456516]
28. Nakamura Y, Hammarström L, Matsumoto K, Lyngstadaas SP. The induction of reparative dentine by enamel preteins. *Int Endod J.* 2002; 35(5):407–17. [DOI: 10.1046/j.1365-2591.2002.00556.x] [PMID: 12059910]
29. Danilović V, Petrović V, Marković D, Aleksić Z. Histological evaluation of platelet rich plasma and hydroxyapatite in apexogenesis: study on experimental animals. *Vojnosanit Pregl.* 2008; 65(2):128–34. [DOI: 10.2298/VSP0802128D] [PMID: 18365669]
30. Laurent P, Camps J, About I. Biodentine™ induces TGF-β1 release from human pulp cells and early dental pulp mineralization. *Int Endod J.* 2012; 45(5):439–48. [DOI: 10.1111/j.1365-2591.2011.01995.x] [PMID: 22188368]
31. Murray PE, Hafez AA, Smith AJ, Windsor LJ, Cox CF. Histomorphometric analysis of odontoblast-like cell numbers and dentine bridge secretory activity following pulp exposure. *Int Endod J.* 2003; 36(2):106–16. [DOI: 10.1046/j.1365-2591.2003.00632.x] [PMID: 12657154]
32. Orhan EO, Maden M, Senguüven B. Odontoblast-like cell numbers and reparative dentine thickness after direct pulp capping with platelet-rich plasma and enamel matrix derivative: a histomorphometric evaluation. *Int Endod J.* 2012; 45(4):317–25. [DOI: 10.1111/j.1365-2591.2011.01977.x] [PMID: 22007726]
33. Petrović V, Opačić-Galić V, Jokanović V, Jovanović M, Basta Jovanović G, Živković S. Biocompatibility of a new nanomaterial based on calcium silicate implanted in subcutaneous connective tissue of rats. *Acta veterinaria.* 2012; 62:697–708. [DOI: 10.2298/AVB1206697P]

Direktno prekrivanje pulpe novim nanostrukturnim materijalima na bazi kalcijum-silikatnih sistema i hidroksiapatita

Marijana Popović Bajić¹, Violeta Petrović¹, Vanja Opačić Galić¹, Vesna Danilović¹, Vukoman Jokanović², Branislav Prokić³, Bogomir Bolka Prokić³, Slavoljub Živković¹

¹Univerzitet u Beogradu, Stomatološki fakultet, Klinika za bolesti zuba, Beograd, Srbija;

²Institut za nuklearne nauke „Vinča“, Univerzitet u Beogradu;

³Univerzitet u Beogradu, Fakultet veterinarske medicine, Katedra za hirurgiju, Beograd, Srbija

KRATAK SADRŽAJ

Uvod Direktno prekrivanje pulpe je važan terapijski postupak koji ima zadatak da obezbedi zatvaranje pulpne komore i omogući proces zarastanja. Cilj ovog rada je bio da se ispita efekat novih nanostrukturnih materijala na bazi kalcijum-silikatnih sistema i hidroksiapatita na eksponiranu pulpu zuba vijetnamskih svinja.

Materijal i metode rada Istraživanje je sprovedeno na 30 zuba kod dve vijetnamske svinje (*Sus scrofa verus*). Na vestibularnim površinama sekutića, očnjaka i prvih premolara urađene su preparacije kaviteta V klase, pri čemu je malim okruglim svrdlom napravljena namerna eksploracija komore pulpe. U prvoj eksperimentalnoj grupi (10 zuba) perforacija je prekrivana novim nanostrukturnim materijalom na bazi kalcijum-silikatnih sistema (CS). U drugoj eksperimentalnoj grupi (10 zuba) perforacija je prekrivana smešom kalcijum-silikatnog sistema i hidroksiapatita (HA-CS). U kontrolnoj grupi (10 zuba) perforacija je prekrivana sa MTA® (Dentsply Tulsa Dental, Džonson Siti, Tenesi, SAD). Svi kaviteti su restaurirani glas-jonomer cementom (GC Fuji VIII, GC Corporation, Tokio, Japan). Opservacioni period iznosio je 28 dana. Nakon žrtvovanja životinja napravljeni su histološki preparati na kojima su analizirani postojanje dentinskog mostića, inflamatorna reakcija pulpe, reorganizacija pulpnog tkiva i prisustvo bakterija.

Rezultati Na svim zubima eksperimentalnih grupa i kontrolne grupe zabeleženo je stvaranje dentinskog mostića. Zapaljenje pulpe je bilo blago do umereno i u eksperimentalnim i u kontrolnoj grupi. Uočeni su znaci neoangiogeneze i mnoštvo ćelija sličnih odontoblastima koje su odgovorne za stvaranje dentinskog mostića. Nekroza nije zabeležena ni u jednom slučaju, kao ni prisustvo gram-pozitivnih bakterija u pulpi.

Zaključak Histološka analiza je ukazala na povoljne terapijske efekte novih nanostrukturnih materijala na bazi kalcijum-silikatnih sistema i hidroksiapatita u direktnom prekrivanju pulpe zuba vijetnamskih svinja.

Ključne reči: direktno prekrivanje pulpe; kalcijum-silikati; hidroksiapatit; MTA; dentinski mostić

UVOD

Direktno prekrivanje pulpe i očuvanje vitaliteta pulpe je izuzetno značajan terapijski postupak, posebno kod karijesnih zuba mladih osoba i zuba s komplikovanim višekanalnim sistemima [1, 2]. Brojna istraživanja su potvrdila da kalcijum-hidroksid predstavlja zlatni standard u direktnom prekrivanju pulpe još od momenta njegovog uvođenja u stomatološku praksu 1920. godine [2]. Za to su odgovorni visoka pH vrednost ovog preparata i stimulatívni efekat na odontoblaste, koji dovodi do stvaranja terciarnog dentina i očuvanja vitaliteta pulpe. Ipak, procenat uspešnosti primene kalcijum-hidroksida u publikovanim radovima je neujednačen – od 31% do 100% [3–6]. Zbog neodgovarajuće veze kalcijum-hidroksida sa eksponiranom pulpom, degradacije tokom vremena, poroznosti novostvorenog dentinskog mostića i pojave internih resorpcija, postoji potreba za pronalaženjem efikasnijih materijala [3, 7, 8].

Poslednjih dvadesetak godina velika pažnja se poklanja mineral-trioksid agregatu ProRoot MTA® (Dentsply Tulsa Dental, Džonson Siti, Tenesi, SAD), čija je jedna od indikacija i direktno prekrivanje pulpe, jer dovodi do stvaranja kompletnog dentinskog mostića i bez znakova inflamacije pulpe [9, 10]. Mnoge studije su potvrdile njegovu biokompatibilnost, antimikrobni efekat, dobro zaptivanje i dobre fizičke i hemijske osobine [11, 12]. Izuzetno je hidrofilan i zbog toga se može koristiti i u vlažnim uslovima i uz prisustvo krvi. Potvrđeno je takođe da je debljina novostvorenog dentinskog mostića veća posle prekrivanja pulpe sa MTA nego pri korišćenju kalcijum-hidroksida

[13, 14, 15]. MTA pokazuje odlične osobine kao materijal za direktno prekrivanje zubne pulpe i uspešno zamenjuje kalcijum-hidroksid, jer ne prouzrokuje lokalnu nekrozu pulpe, dok se hronično zapaljenje zubne pulpe ređe pojavljuje [15]. MTA izaziva funkcionalne i citološke promene u ćelijama pulpe, kao i njihovu transformaciju u ćelije slične odontoblastima, koje izgrađuju fibrodentin, odnosno reparativni dentin na površini eksponirane pulpe [16, 17]. Nedostaci su mu nestabilnost praha neposredno nakon otvaranja, visoka cena na tržištu i dugo vreme vezivanja. Iako proizvođač navodi vreme vezivanja od 10 minuta, studija Torabinedžada (Torabinejad) i saradnika [18] utvrdila je da je vreme vezivanja između dva i četiri sata. Aktuelna istraživanja su usmerena ka pronalaženju materijala za direktno prekrivanje pulpe zuba koji bi zadržao sve dobre osobine MTA, ali i prevazišao njegove mane.

Hidroksiapatit je materijal na bazi kalcijum-fosfata koji se veoma često koristi u medicini i stomatologiji. Biokompatibilnost hidroksiapatita je usko povezana sa njegovim hemijskim sastavom koji je veoma sličan zubnim i koštanim tkivima. Ipak, loše mehaničke osobine hidroksiapatita onemogućavaju njegovu primenu u endodonciji. Skorašnje studije su se bavile ispitivanjima novih formulacija kalcijum-fosfata, koje su ukazale na povoljne mehaničke i biološke osobine ovih materijala [19, 20, 21, 22, 23].

Poslednjih godina na Institutu za nuklearna istraživanja u Vinči su sintetisana dva nova eksperimentalna materijala na bazi kalcijum-silikata po originalnoj recepturi V. Jokanovića i saradnika. Prvi kalcijum-silikatni sistem predstavljao je kombi-

naciju trikalcijum i dikalcijum silikata (CS), a drugi smešu CS i hidroksiapatita u odnosu 1:2 (HA-CS). Oba materijala su u svom sastavu imala barijum-sulfat kao rendgen-kontrastno sredstvo.

Radi se o materijalima koji su sintetisani kombinacijom dve tehnike: hidrotermalnom sol-gel metodom i metodom samosagorevajućih talasa. Na taj način dobijeni su materijali koji u svom sastavu imaju tri veličine čestica: aglomerati (veličine nekoliko mikrometara), partikule (veličine 117–447 nanometara) i kristaliti (veličine svega 20 nanometara) [24]. Čestice nanometarskih dimenzija omogućile su veću aktivnost čestica, a samim tim i bolju hidrataciju cementa i kraće vreme vezivanja (CS – 10 min., HA-CS – 15 min.) [24].

Cilj ovog rada je bio da se proverí efekat novih materijala na bazi aktivnih kalcijum-silikatnih sistema i hidroksiapatita (CS i HA-CS) nakon prekrivanja eksponirane pulpe zuba vijetnamskih svinja.

MATERIJAL I METODE RADA

Eksperimentalno istraživanje obavljeno je na Fakultetu veterinarske medicine Univerziteta u Beogradu uz saglasnost Etičkog komiteta Stomatološkog fakulteta Univerziteta u Beogradu. U eksperiment je bilo uključeno 30 zuba kod dve vijetnamske svinje (*Sus scrofa verus*) starosti 24 meseca i telesne mase 25 kg. Tokom rada poštovan je protokol Evropske dobre laboratorijske prakse (86/609/EEC), koji podrazumeva primenu glavnih principa asepsa i antiseptičke – realizaciju eksperimenta u minimalnom potrebnom vremenu bez fizičkog i duševnog bola životinja (Međunarodna organizacija za standardizaciju, 1997). Kao kontrolni materijal korišćen je ProRoot MTA® (Dentsply Tulsa Dental, Džonson Siti, Tenesi, SAD), čiji su efekti na pulpu već poznati.

Eksperimentalni postupak

Kod životinja je izvršena premedikacija atropinom u dozi 0,03–0,04 mg/kg i.m., a nakon 15 minuta životinje su uvedene u opštu anesteziju davanjem ksilazina u dozi 1,5–2 mg/kg i.m. i ketamina u dozi 20–25 mg/kg i.m. Nakon anesteziranja i postavljanja koferdam-gume radi izolacije, zubi su očišćeni sedamdesetoprocentnim etanolom.

Na vestibularnim površinama sekutića, očnjaka i prvih premolara okruglim karbidnim borerom urađena je preparacija kaviteta V klase uz stalno hlađenje fiziološkim rastvorom. Potom je malim okruglim borerom eksponirana komora pulpe, a krvarenje je kontrolisano sterilnim kuglicama vate. Zatim je na perforaciju aplikovan prethodno pripremljen materijal. Na zubima desnog kvadranta gornje vilice kod obe vijetnamske svinje (ukupno šest sekutića, dva očnjaka i dva premolara) postavljen je CS. Na istom broju zuba u levom kvadrantu gornje vilice obe vijetnamske svinje postavljen je HA-CS. MTA je kao kontrolni materijal postavljen na istom broju zuba u donjoj vilici sa desne strane kod obe vijetnamske svinje (šest sekutića, dva očnjaka i dva premolara). Svi kaviteti su restaurirani glasjonomer-cementom (GC Fuji VIII, GC Corporation, Tokio, Japan). Opservacioni period je iznosio 28 dana. Posle prestanka dejstva anestezije životinjama je dat analgetik butorfanol u dozi 0,1–0,2 mg/kg,

a nakon oporavka životinje su čuvane i gajene u individualnim kavezima u farmским uslovima.

Posle četiri nedelje životinje su žrtvovane uvođenjem u opštu anesteziju i davanjem pentobarbiton-natrijuma i.v. u dozi od 100 mg/kg. Vilice su isečene na blok-sekcije i tkivo je fiksirano i pripremano za mikroskopsku analizu.

Histološki postupak

Tkivo za histološku analizu uzeto je u bloku i svaki uzorak je sadržao eksperimentalni zub i okolnu kost. Uzorci su prikupljeni poštujući ISO kriterijume (Technical Report 7405) 28 dana nakon eksponiranja pulpe i direktnog prekrivanja. Materijal za histološku analizu je fiksiran u desetoprocentnom formalinu, dekalifikovan u desetoprocentnoj mravljoj kiselini (pH = 5) i kalupljen u parafinu. Na staklenim pločicama su napravljene serijske sekcije u meziodistalnom smeru debljine 4 µm. Preparati su bojeni hematoksilin-eozinom metodom po Goldneru (Goldner) i metodom po Gramu (Gram) zbog mikroskopske identifikacije bakterija. Materijal je analiziran pod svetlosnim mikroskopom.

Histološki kriterijumi za procenu reakcije pulpe su korišćeni u skladu s metodologijom Šajegana (Shayegan) i saradnika [25]. Analizirani su dentinski mostić (A) (debljina, lokalizacija, struktura, kontinuitet s okolnim dentinom), morfološka reorganizacija ćelija pulpe (B) (hronična ili akutna, intenzitet i lokalizacija zapaljenja) inflamatorna reakcija pulpe (C) i prisustvo bakterija (D). Ovi parametri praćeni su zahvaljujući Međunarodnoj organizaciji za standardizaciju (International Organization for Standardization) i objavljenim kriterijumima Mjora (Mjör) [26] iz 1983. godine.

REZULTATI

Rezultati histoloških analiza su pokazali da je dentinski mostić stvoren kod svih uzoraka i u eksperimentalnim i u kontrolnoj grupi (Tabela 1). Novostvoreni dentin imao je odlike reparativnog dentina sa pravilno postavljenim dentinskim kanalićima ili s malim brojem nepravilnih dentinskih kanalića, koji su bili u kontinuitetu s okolnim dentinom. Kompletan dentinski mostić, koji je potpuno zatvarao pulpni prostor u predelu perforacije, zabeležen je u šest uzorka na kojima je primenjen HA-CS (Slika 1). U četiri uzorka nakon primene CS i istom broju uzoraka kontrolne grupe uočeno je takođe prisustvo kompletnog dentinskog mostića (Slika 2). Ispod novostvorenog dentina zabeležene su ćelije slične odontoblastima, koje su u vezi s novonastalim tubularnim dentinom. Originalni odontoblasti su bili pozicionirani periferno. Oni su prepoznati zahvaljujući njihovom regularnom palisadnom rasporedu, eozinofilnoj citoplazmi i bazalno postavljenim jedrom. Nepotpun dentinski mostić u vidu dentinskih ostrvaca uočen je kod pet zuba u grupi u kojoj je primenjen CS (Slika 3) i kod tri zuba u grupi gde je primenjen HA-CS (Slika 4). U kontrolnoj grupi dentinska ostrvca su bila zabeležena u šest uzoraka. Kontinuiran reparativni dentin koji se prostire duž lateralnih zidova dentina uočen je u po jednom uzorku eksperimentalnih grupa (Slika 5), a takav vid dentina nije registrovan u uzorcima kontrolne grupe (MTA).

Potpuno očuvano pulpno tkivo zabeleženo je samo u po jednom uzorku eksperimentalnih grupa i u dva uzorka kontrolne grupe (Slika 3). Dezorganizacija pulpnog tkiva u vidu pojave ćelija sličnih odontoblastima i njihove hiperaktivnosti uočena je kod najvećeg broja uzoraka (po devet zuba u eksperimentalnim i osam u kontrolnoj grupi), kod kojih su u centralnom delu pulpe uočeni venska staza, krvarenje i zapaljenje (Slika 5). U većini ovih uzoraka uočeni su znaci neoangiogeneze s proliferacijom postojećih i stvaranjem novih krvnih sudova, što je ukazivalo na proces zarastanja i potpunu revaskularizaciju (Slika 6). Potpuna dezorganizacija pulpnog tkiva i nekroza nisu zabeležene ni u jednom uzorku kako eksperimentalnih grupa tako i kontrolne grupe.

Rezultati histoloških analiza nakon četiri nedelje pokazali su da je posle prekrivanja pulpe eksperimentalnim materijalima u najvećem broju uzoraka zabeleženo blago ili umereno hronično zapaljenje (Slika 5). Izrazita upala sa mnoštvom ćelija zapaljenja i pojava apscesa nisu zabeleženi ni u jednom uzorku. Blago zapaljenje je ustanovljeno u osam uzoraka nakon prekrivanja zubne pulpe materijalom CS i u po sedam uzoraka nakon primene HA-CS i MTA (Slika 5). Umereno zapaljenje kod kojeg ćelijska infiltracija zahvata koronarnu i deo radikalne pulpe uočeno je kod dva zuba iz grupe u kojoj je primenjen CS i kod jednog zuba nakon prekrivanja sa HA-CS. Sličan broj ćelija zapaljenja je registrovan kod tri uzorka nakon direktnog prekrivanja pulpe kontrolnim materijalom (MTA).

Bojenjem preparata po Gramu uočen je potpuni izostanak gram-pozitivnih bakterija u pulpi svih uzoraka. Mali broj bakterija u dentinskim kanalićima zabeležen je kod četiri zuba nakon primene CS, pet zuba nakon primene HA-CS, dok su u kontrolnoj grupi bakterije u dentinskim kanalićima uočene u tri uzorka.

DISKUSIJA

Ovo eksperimentalno istraživanje je realizovano na stalnim zubima vijetnamskih svinja koji su po svojoj morfologiji veoma slični humanim zubima. Dosadašnje studije sa novim materijalima vršene su na zubima pasa [17, 27], mlečnim i stalnim zubima svinja [25, 28], odnosno na zubima majmuna [29]. Značajna prednost u radu s eksperimentalnim životinjama je u tome što se eksperiment može realizovati na velikom broju zuba i u istom vremenskom intervalu može proveravati efekat različitih materijala.

Rezultati ove studije su pokazali slične rezultate na zubima u kontrolnoj i eksperimentalnoj grupi. Proces reparativne dentinogeneze, tj. potpuno ili delimično zatvaranje perforacione rane dentinskim mostićem, u ovom istraživanju smatrao se dobrim terapijskim rezultatom. Kod svih zuba kod kojih je pulpa prekrivena novosintetisanim nanostrukturnim materijalima na bazi kalcijum-silikatnih sistema i hidroksiapatita uočen je dentinski mostić. Slične rezultate potvrdila je i studija Lorena (Laurent) i saradnika [30], gde autori povoljan terapijski efekat kalcijum-silikatnih sistema objašnjavaju značajnim povećanjem oslobađanja TGF- β 1 iz ćelija pulpe, koji deluje stimulatивно na odontoblaste i pojačava njihovu sekretornu aktivnost, odnosno reparativnu dentinogenezu.

U kontrolnoj grupi, u kojoj je direktno na pulpu aplikovan MTA, takođe je uočen dentinski mostić u svim uzorcima, što

je u saglasnosti sa sličnom eksperimentalnom studijom na svinjama Šajegana i saradnika [25].

U najvećem broju zuba obe grupe na mestu eksponirane pulpe, ispod novostvorenog dentinskog mostića, uočeni su odontoblasti s manjim ili većim strukturnim promenama, koje su varirale od vrlo blagih do potpune dezorganizacije. Verovatno je da to zapravo i nisu odontoblasti, već ćelije slične odontoblastima (iako su za njihovu konačnu identifikaciju potrebne dodatne imunohistohemijske analize). One, kao i pravi odontoblasti, imaju izdužen oblik, palisadnu orijentaciju i bazalno postavljena jedra [31]. Imaju sposobnost stvaranja i lučenja vancelijskog matriksa, čijom mineralizacijom nastaje reparativni dentin u vidu potpunog ili nepotpunog dentinskog mostića, odnosno ostrvaca koja teže da uspostave kontakt sa bočnim zidovima dentina i tako zatvore i sačuvaju eksponiranu pulpu.

U najvećem broju uzoraka iz grupe MTA primećena je reorganizacija tkiva ispod perforacije u vidu hiperaktivnosti ćelija sličnih odontoblastima i izmenjene morfologije ćelija u odnosu na odontoblaste. Ovo potvrđuju i rezultati studije na psima Cjafasa (Tziafas) i saradnika [17]. Uočena je i povezanost između broja ćelija sličnih odontoblastima, debljine mostića i očuvanosti dubljeg dela tkiva pulpe. S povećanjem broja ovih ćelija raste debljina dentinskog mostića, pri čemu pulpa u radiksnom delu zadržava svoj fiziološki izgled [32]. U grupi zuba na kojima su primenjeni CS i HA-CS kao i kontrolni materijal MTA nekroza nije uočena ni u jednom uzorku. U eksperimentalnoj studiji na psima Tabarsija (Tabarsi) i saradnika [27], posle direktnog prekrivanja pulpe, nekroza je uočena u 22,7% uzoraka. Drugačiji nalazi se mogu objasniti činjenicom da je u njihovoj studiji urađen postupak pulpotomije i postavljen MTA, a ne direktno prekrivanje manje površine eksponirane pulpe kao u našoj studiji.

Primenom eksperimentalnih materijala kod najvećeg broja zuba utvrđeno je blago zapaljenje, što govori u prilog biokompatibilnosti materijala [33]. Akutno zapaljenje i nekroza pulpe takođe nisu zapaženi ni u jednom ispitivanom uzorku. To se može objasniti dobrim rubnim zatvaranjem kaviteta glasonomer-cementom i aseptičnim uslovima rada, ali i dobrim imunološkim stanjem eksperimentalnih životinja.

Rezultati naše eksperimentalne studije su otkrili ćelije zapaljenja i u koronarnom i u radiksnom delu pulpe. Kod uzoraka kontrolne grupe u kojoj je primenjen MTA u samo nekoliko uzoraka uočeni su limfociti, plazmociti i makrofagi, što je u saglasnosti s nalazima drugih autora [25, 27].

Budući da je terapijski efekat bio vrlo sličan u eksperimentalnim i u kontrolnoj grupi, to ukazuje na činjenicu da i novi nanostrukturni materijali na bazi kalcijum-silikatnih sistema i hidroksiapatita imaju povoljno dejstvo na reparatorne aktivnosti pulpe zuba vijetnamskih svinja zahvaljujući, pre svega, svojim fizičkim i hemijskim osobinama.

Nakon primene novih materijala (CS i HA-CS) i MTA došlo je i do neoangiogeneze u pulpi, što ukazuje na regenerativne procese u pulpi i uspešnu remodelaciju tkiva. Slični rezultati dobijeni primenom ovih materijala mogu se objasniti sličnim hemijskim sastavom, jer oba materijala u najvećem procentu sadrže dikalcijum i trikalcijum-silikat. Naravno, o ovome ima i drugačijih mišljenja. Tako Mari (Murray) i saradnici [31] smatraju da su za započinjanje procesa dentinogeneze najvažniji očuvanost pulpe i odontoblasta, te nepostojanje infekcije i nekroze, a ne vrsta materijala.

ZAKLJUČAK

Reparacija veštački izazvanih oštećenja pulpe zuba eksperimentalnih životinja u eksperimentalnoj i u kontrolnoj grupi bila je vrlo efikasna. Kod većine zuba proces reparativne dentinogeneze je praćen stvaranjem dentinskog mostića i očuva-

njem funkcionalnog i morfološkog integriteta pulpe. Histološka analiza je ukazala na povoljne terapijske efekte novih nanostrukturnih materijala na bazi aktivnih kalcijum-silikatnih sistema i hidroksiapatita u direktnom prekrivanju pulpe zuba vijetnamskih svinja. Reakcija pulpe bila je slična onima koje je izazvao MTA.