



Assessment of implant stability by resonant frequency analysis

Procena stabilnosti implantata analizom rezonantne frekvencije

Vitimir S. Konstantinović*, Filip Ivanjac*, Vojkan Lazić†, Igor Djordjević†

*Clinic for Maxillofacial Surgery, †Clinic for Prosthodontics, Faculty of Dentistry,
University of Belgrade, Belgrade, Serbia

Key words:
dental implants; osseointegration; biomechanics.

Ključne reči:
implantati, stomatološki; oseointegracija; biomehanika.

Implant stability

Implant stability is a principal precondition for the success of implant therapy. Implant stability can be primary or secondary and depends on different factors¹⁻⁴.

Primary implant stability.

It is a frictional force between the bone and the implant. Stability is achieved during implant insertion in the bone site which is the result of biomechanical bone-implant relation³⁻⁷. Primary stability depends on: bone quality, bone amount, surgical technique, implant design and surface⁸⁻¹⁰.

Bone quality

The hardness of compact bone is about 10 times higher than cancellous (trabecular) bone, thanks to both its density and mineralization. The higher bone density gives the higher primary implants stability values¹¹⁻¹³. Considering that cancellous bone has lower biomechanical values, some authors like to name it 'lower quality bone', which is not quite exact and correct term. It is better to name it – 'low density bone'. The most important parameter is the quality of bone that can be classified by its density based on panoramic radiography¹⁴.

Bone is then classified as: type 1 – compact bone; type 2 – thick layer of compact bone which overlays trabecular bone; type 3 – thin layer of cortical bone which overlays dense trabecular bone; type 4 – thin layer of cortical bone which overlays low density trabecular bone (Figure 1).

Regardless bone density, particular concern should be carried out with patients at risk, like patients after radiotherapy^{15,16}.

Implant stability can also be differentiated by the location in the jaw bone region. Higher values of primary stability are achieved in the regions with higher bone density (measured by computed tomography – CT), such are intercanine and molar regions. In case of higher bone density, a high value of primary stability will be achieved^{17,18}.

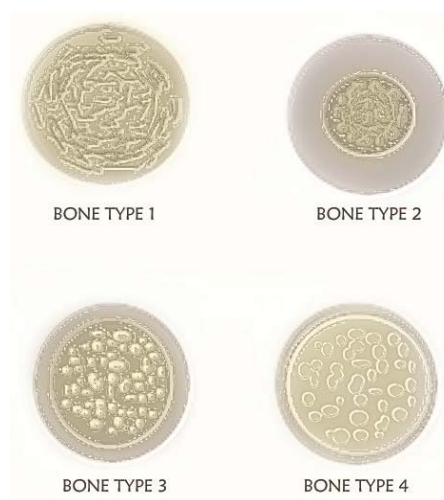


Fig.1 – Bone type scheme, drawn by Dr. Filip Ivanjac, inspired by Lekholm and Zarb¹⁴.

There are similar results for the relationship bone density/implant stability, as well as for the resistance during implant insertion in other publications suggesting that bone density measured by CT can predict implant stability¹⁹⁻²².

Bone amount

Bone amount is an important factor in implant therapy. The lack of alveolar bone is a limiting factor for implantation. When there is no sufficient bone quantity at least of 10 mm in length, the implantologist have to choose to use more suitable implants, generally smaller and shorter ones, which could jeopardize implant stability¹².

Surgical technique

Surgical technique plays an important role in implant stability as well as in outcome of implant therapy. Surgical trauma is a risk factor which damages bone tissue¹⁹⁻²⁵. Pri-

mary stability also depends on drill diameter: smaller-diameter drills often give higher values of primary stability.

Implant design

Implant macro and micro design can have influence on implant stability. In other words, it depends on the available implant surface. Increase in implant surface could be achieved by plasma coating, sanding, laser treating and applying crystals of calcium phosphate. These procedures can enlarge the surface up to 10 times. A larger implant surface provides both higher primary stability values and consequently better osseointegration. Implants longer than 10 mm have better primary stability. Root shaped implants have a better force distribution on periimplant tissue, and cylindrical implants show the highest primary stability values, so they are more often used^{26,27}.

Secondary implant stability

After implantation, surrounding tissue responds to trauma by bone remodelling which could last from 12 to 18 months. However, the term 'secondary stability' usually refers to the period of 3–6 months after implantation. Implants placed into the cancellous bone as well as in the compact bone modify their stability during the time. Changes occur in cancellous bone which adopts compact bone characteristics in the areas close to the implant surface, which further makes an implant more stable^{12,13,26,27}.

In compact bone, implant stability is decreased during the time because of a mild bone resorption, so implant stability values both in compact bone and cancellous bone after a time period are closer, nearly equal^{28–30}.

Sometimes, secondary stability values are lower than primary stability values. Decrease in stability is the result of mild resorption in marginal bone. Some authors deny this fact by achieving high values in resonance frequency quotient after one-year period follow-up. On the other hand, increase of primary stability values is due to bone remodelling, which is influenced by external and internal factors like general health, tobacco and drugs use, or radiotherapy^{14,31}.

Secondary stability depends on bone remodelling process on the implant-bone interface which is influenced by both implant surface and healing time^{28,30}.

Osseointegration

Per Ingvar Branemark³², Swedish doctor, was the first researcher to scientifically prove (in 1969) that a direct structural and functional contact between the live bone and a functionally loaded implant is possible. This process is defined by the term 'osseointegration'. Subsequently, it has been known that osseointegration depends on healing abilities, reparation and remodelling of bone tissue. A relation between the bone and an implant is defined as a functionally ankylotic link^{21,28,31–34,44}.

Osseointegration is a histological term meaning direct bone apposition on the surface of the implant without insertion of soft tissue. It is achieved by bone remodelling during the initial healing period when implant is not loaded in order to ensure smooth bone formation on the implant surface. The

process of osseointegration increases bone density, prevents micromovement and the formation of fibrous scar tissue around the implant. Osseointegration is most intense in the first two weeks after implantation. Good osseointegration clinically means a stable marginal bone around the implant with no mobility^{28,31–38}.

Implant stability is a combination of the mechanical and biological stability: mechanical stability is the result of compression of bone tissue during implantation; biological stability is the result of newly formed bone cells, which are created on the implant surface during the osseointegration process.

Mechanical stability which is usually high occurs immediately after placing an implant into the bone. However, it decreases with time.

Biological stability does not appear immediately after implantation. It becomes noticeable after the formation of new bone cells on the implant surface. This stability increases over time –secondary stability. As a result of osseointegration, the initial mechanical stability is partly replaced by biological stability. The final implant stability is a combination of these two stabilities^{5–9,31}.

Assessment of implant stability

Various methods are used for implant stability testing. Surgeon's subjective assessment of implant stability is based on the resistance during bone preparation and insertion of the implant. However, this method of perception cannot be objectively expressed^{20,39–44}.

Insertion torque resistance. Insertion torque is a measure of the resistance that occurs during implantation. It depends on bone strength and density, as well as on implant properties. The disadvantage of this method is its depending on the implant sharpness and the presence of fluid during preparation which may differ in results. The greater the sharpness of the implant or the more fluid in the implant site during preparation, the less resistance. Another disadvantage is that the force of implant placement does not count^{20,44}.

Percussion test. It includes percussion of the cervical part of the implant by the handle of the instrument. A conclusion on implant stability is made by the presence of resonant sound. Also, there are electrical devices that are based on the same principle like "perio test" such is - dental mobility checker^{43,44}.

Implant loosening test. This is a reverse torque test. Opposite torque test is most often used to measure the secondary implant stability. Implants which show mobility during this test should be considered to be removed. This method is not in use, because testing can lead to gaps caused by microcracks in the implant and bone interface, which can result in implant failure³⁸.

Measurement of the lateral mobility. Micromovement of an implant in vestibulo-oral or mesiodistal direction (Figure 2) is more reliable than measuring rotational mobility of the implant. Rotationally mobile implants can be laterally stable, which is a good prognostic sign for successful osseointegration^{30,42}.

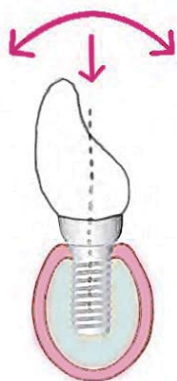


Fig. 2 – Graphic scheme of implant micromovement directions, drawn by Dr Filip Ivanjac inspired by Sennerby et al⁴.

Besides, there are techniques such as ultrasonic implant stability testing, as well as the analysis of the resonant frequency (RFA). The bottom line is to measure implant stability in a non-invasive manner without damage to the implant-bone interface. As the success of implant therapy is often associated with biomechanical factors, implant stability assessment provides valuable information that can guide further clinical procedures³⁹⁻⁴².

History of resonance frequency analysis

Resonant frequency analysis (RFA) reflects the implant stability. RFA has been used in clinical research for over 10 years. Coefficient (ratio) of implant stability (implant stability quotient – ISQ) is the result of resonant frequency analysis. RFA is an implant stability analysis method where a very low value of lateral bending force is applied mimicking clinical conditions of implant loading, only in a much smaller proportion. It measures micromovement of an implant in its seat, based on the reflected frequency¹⁻⁹.

The first studies about RFA were conducted by Meredith et al.¹ in 1996. They launched a device for measuring implant stability (Ostell[®]).

Parallely, in Taipei (Taiwan) a similar system – Implomates[®] Bio Tech One system, was introduced. In the initial studies, Meredith et al.^{1,3} used kilo Hertz (kHz) to measure implant stability in the range of 3500–8500 kHz. Shortly afterwards, ISQ with the values of 1–100, which correlates with the frequency in kHz, was established (1 is the lowest and 100 is the highest stability value).

A newer generation is a device invented by Ostell Mentor[®]. It functions as an electronic resonant fork, which translates kHz into ISQ. This is a portable device that emits a signal of 5–10 Ncm through a transducer and calculates ISQ value, which is based on the reflected signal. The first resonant frequency of the transducer (fixed to the implant or abutment) is analyzed. The disadvantage of this method were values depending on the direction of setting up the transducer. With the new generation of Ostell Mentor[®] devices the transducer is multidirectional. The signal that the device transmits is 5–15 kHz frequency with a power amplitude of 1 V. The reflected resonant signal is read by the analyzer (de-

tor) of frequency and compared with the original signal frequency. The acceptable range of values for the implant stability is 55–85 ISQ units, with the average value of 70 ISQ units¹⁻⁹.

RFA frequency depends on three main factors: transducer design (transmitter), implant tightness and its relationship with the surrounding bone and the effective length above the marginal bone level. The effective length is the sum of the length of the transducer and the abutment, which can vary. In the first and second generation, Ostell Mentor[®] devices were relatively large and connected by cables to the computer. Data was recorded on the hard disk. The results were not comparable to each other, because each transducer had its own frequency, so different transducers had to be calibrated before measuring. The new (third) generation of Ostell Mentor[®] is a small, portable, wireless device that operates on batteries. The transducer is calibrated by the manufacturer. The result obtained by measuring is a ISQ. It uses a cylindrical metal bar – ‘smart peg’. On one end it has a screw which is attached with the implant and a miniature magnet on its top, which is excited by magnetic signals from the transducer of the device. ‘Smart peg’ vibrates in two directions positioning on 90 degrees one to another, in the direction of the highest value of resonant frequency, and the direction of the lowest value, thus making a single coefficient – ISQ. A better support and stability in the bone, gives the greater value of resonant frequency. There are transmitters for different implant systems and abutments. In this way, all the measurements are comparable regardless of the type of implant or abutment. Each result is stored in a memory card in the tabular form. Data can be transferred to a computer using a cable or wireless infrared connection^{4,8,9,19,45,46}.

Transducer orientation affects measurement of resonant frequency. There may be variations up to 10 ISQ units if the probe is set in parallel rather than perpendicular direction to the alveolar ridge. The new generation device measures the highest and the lowest frequency, whenever there is a difference of 3 ISQ units. Up to 10 units higher values of coefficient are obtained by a new generation of wireless technology device which measures the vibrations in the mesiodistal direction. Lower values are obtained using the old technique, the bucco-oral direction. This value is lower because of the thinner bone, which provides less support. The results are lower also because of different orientation of the transducer in the older generation devices. Resonance frequency analysis can provide a significant information about the relation implant/bone at any stage of treatment⁴⁻⁹.

The importance of RFA method is in the fact that it helps the implantologist choosing when to load an implant. Also, it can indicate situations when it is necessary to relieve the overloaded implant.

High values of primary stability (ISQ 70 and higher), have no tendency to significantly increase over time. High primary (mechanical) stability decreases with time due to osteoclastic activity. It is replaced by biological stability, which increases because of the osseointegration process. However, slightly lower and low values of primary stability are increased by the process of bone remodelling and osseointegration^{4,9,18,26,45}.

Primary stability of ISQ values of 55 and below, could be considered as a warning sign in order to increase the stability of the implant (wider implant diameter) and time for osseointegration^{25, 27}.

Resonant frequency analysis is the most objective and reliable method of measuring the lateral micromobility of an implant during any stage of implant therapy^{4, 19, 26, 45}. It is clinically proven that implant stability plays an important role in the future treatment and provides an insight into the outcome of implant therapy³⁻⁷. The ability to determine the level of implant stability in different stages of treatment is not only necessary, but an important source of information for further proceedings in therapy^{19, 26}.

Implant stability determines the loading protocol: immediate implant loading with low primary stability would jeopardize the result of implant therapy. In such a case, a conventional (late) loading protocol is recommended. On the other hand, when primary stability is high, immediate loading protocol could be performed.

Implant stability could also give information on possible implant unloading. Sennerby and Meredith⁴ suggest that implant stability determines adequate time to replace immediately loaded temporary prosthesis with permanent. Low values of secondary stability can suggest that the implant has been overloaded with possible failure. In that situation unloading of the implant could help in stability regaining (Figures 3 and 4)^{19, 26, 42, 46}.

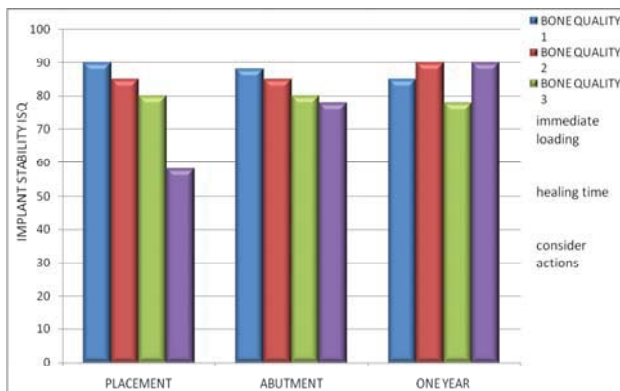


Fig. 3 – Assessment of actions regarding implant stability during the time, drawn by Dr. Filip Ivanjac, inspired by Sennerby et al.²⁶.

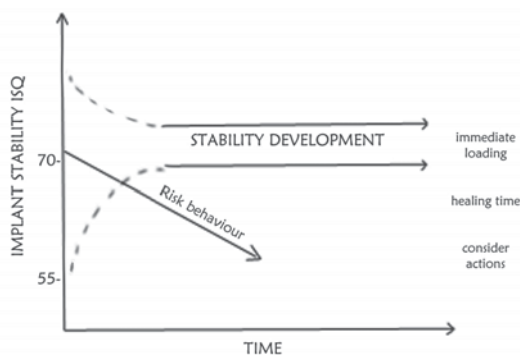


Fig. 4 – Risk behaviour regarding of implant stability and time, drawn by Dr. Filip Ivanjac, inspired by Sennerby et al.²⁶.

A period of 2 to 4 weeks after implant placement is referred as “critical”. In that period implant stability reduces. It is a transient period between the primary and secondary stability^{26, 47} (Figure 5). Osteoclastic activity leads both to bone resorption and primary stability reducing. Decrease in implant stability is created by the weakened bone which is partially absorbed. The bone integrity was compromised by implant placement after which remodelling occurs⁴⁷.

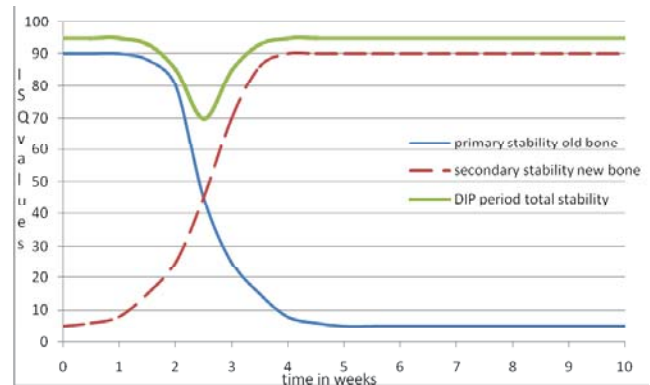


Fig. 5 – Implant dip period, drawn by Dr. Filip Ivanjac, inspired by Sennerby et al.²⁶.

Bone remodelling occurs on the third day after implantation. Adequate stabilization and mineralization of newly formed bone takes place about 160 days after beginning of bone remodelling. Time for complete bone mineralization is up to 12 months^{33, 47}.

Clinical success of endosteal implants depends on optimal relation of implant-bone interface. A direct connection of the entire surface of the implant and surrounding bone tissue cannot be obtained. Root-shaped implants obtain the best results, where direct bone-implant connection is achieved in 56–85% of implant surface⁴⁸. Furthermore, root-shaped implants have better force distribution on peri-implant tissue, and cylindrical implants show the highest primary stability values²⁷. Cylindrical shape implants show the average 72 ISQ, while tapered implants show slightly lower values on the average of 68 ISQ, depending on the system^{26, 27}.

Conclusion

Resonant frequency analysis is probably the most objective and reliable method of measuring implant micromobility in various stages of implant therapy. Implant stability is clinically proven to play an important role in the efficiency of treatment, providing the insight into implant therapy outcome.

Implant therapy success depends on biomechanical stability factors data. Good implant stability reduces the risk of failure. Recent researches have shown that high values of resonant frequency analysis indicate therapy success with a minimal probability of failure.

On the other hand, low values of resonant frequency analysis point to possible complications, such as loosening of

the implant, peri-implantitis and poor distribution of force in the surrounding tissue. Since implants failure is often associated with biomechanical factors, assessment of implant stability gives a valuable information. High values of resonant frequency analysis, as well as adequate surgical implantation technique and implant system chosen, could guarantee predictability of implant supported restoration. Generally, the values of implant stability quotient below 55 or 45 (regarding different implant systems) can be taken as a warning for primary stability. In order to increase stability, for example, using of wider and/or longer implant or particular bone condensing techniques could be helpful. A low resonant frequency analysis value in osseointegrated and loaded im-

plants, indicates both disintegration and consecutive resorption of bone tissue around the implant.

Implant stability measuring using resonant frequency analysis is a modern, non-invasive and a relatively precise technique, which provides both information on implant stability in the bone and a reliable guidance to further course of implant therapy.

Acknowledgement

This study was supported by the Ministry of Education, Science and Technological Development of the Republic of Serbia (Project No. 41008).

R E F E R E N C E S

- Meredith N, Alleyne D, Cawley P. Quantitative determination of the stability of the implant-tissue interface using resonance frequency analysis. *Clin Oral Implants Res* 1996; 7(3): 261–7.
- Meredith N. Assessment of implant stability as a prognostic determinant. *Int J Prosthodont* 1998; 11(5): 491–501.
- Konstantinović V. Contemporary implantology - challenges, possibilities, limits. *Srp Arh Celok Lek* 2008; 136(Suppl 2): 123–8. (Serbian)
- Sennerby L, Meredith N. Implant stability measurements using resonance frequency analysis: biological and biomechanical aspects and clinical implications. *Periodontology* 2000 2008; 47(1): 51–66.
- Sennerby L, Meredith N. Resonance frequency analysis: measuring implant stability and osseointegration. *Compend Contin Educ Dent* 1998; 19(5): 493–8, 500, 502; quiz 504.
- Friberg B, Sennerby L, Linden B, Grondahl K, Lekholm U. Stability measurements of one-stage Branemark implants during healing in mandibles. A clinical resonance frequency analysis study. *Int J Oral Maxillofac Surg* 1999; 28(4): 266–72.
- Scortecchi G, Miscb C, Benner K. Implants and restorative dentistry. London: Dunitz; 2001.
- Sunden S, Grondahl K, Grondahl HG. Accuracy and precision in the radiographic diagnosis of clinical instability in Branemark dental implants. *Clin Oral Implants Res* 1995; 6(4): 220–6.
- Quesada-Garcia MP, Prados-Sanchez E, Olmedo-Gaya MV, Munoz-Soto E, Gonzalez-Rodriguez MP, Vallecillo-Capilla M. Measurement of dental implant stability by resonance frequency analysis: A review of the literature. *Med Oral Patol Oral Cir Bucal* 2009; 14(10): 538–46.
- Friberg B, Sennerby L, Meredith N, Lekholm U. A comparison between cutting torque and resonance frequency measurements of maxillary implants. A 20-month clinical study. *Int J Oral Maxillofac Surg* 1999; 28(4): 297–303.
- Turkyilmaz I, Tözüm TF, Tumer C, Ozbek EN. Assessment of correlation between computerized tomography values of the bone, and maximum torque and resonance frequency values at dental implant placement. *J Oral Rehabil* 2006; 33(12): 881–8.
- Ikumi N, Tsutsumi S. Assessment of correlation between computerized tomography values of the bone and cutting torque values at implant placement: a clinical study. *Int J Oral Maxillofac Implants* 2005; 20(2): 253–60.
- Friberg B, Jisander S, Widmark G, Lundgren A, Ivanoff C, Sennerby L, et al. One-year prospective three-center study comparing the outcome of a “soft bone implant” (prototype Mk IV) and the standard Branemark implant. *Clin Implant Dent Relat Res* 2003; 5(2): 71–7.
- Lekholm U, Zarb GA. Patient selection and preparation. In: Brånemark PI, Zarb GA, Albrektsson T, editors. *Tissue Integrated Prostheses: Osseointegration in Clinical Dentistry*. Chicago, USA: Quintessence; 1985. p. 199–209.
- Konstantinović VS, Lazić VM, Stefan I. Nasal epithesis retained by basal (disk) implants. *J Craniofac Surg* 2010; 21(1): 33–6.
- Ibde S, Kopp S, Gundlach K, Konstantinović VS. Effects of radiation therapy on craniofacial and dental implants: a review of the literature. *Oral Surg Oral Med Oral Pathol Oral Radiol Endod* 2009; 107(1): 56–65.
- Ibde S, Dimitroff Y, Konstantinović VS, Ibde A. Temporary gain of stability in basal implants through vertical bone screws. *CMF Impl Dir* 2011; 6(2): 17–23.
- Sennerby L, Ericson LE, Thomsen P, Lekholm U, Astrand P. Structure of the bone-titanium interface in retrieved clinical oral implants. *Clin Oral Implants Res* 1991; 2(3): 103–11.
- Konstantinović V. Aspekte der implantologischen Versorgung mit BOI im Bereich des Sinus maxillaris. *ZMK* 2003; 19: 568–75.
- Ostman P, Hellman M, Sennerby L. Direct Implant Loading in the Edentulous Maxilla Using a Bone Density-Adapted Surgical Protocol and Primary Implant Stability Criteria for Inclusion. *Clin Implant Dent Relat Res* 2005; 7(Suppl 1): 60–9.
- Schroeder A, van der Zypen E, Stich H, Sutter F. The reactions of bone, connective tissue, and epithelium to endosteal implants with titanium-sprayed surfaces. *J Maxillofac Surg* 1981; 9(1): 15–25.
- Schwartz Z, Boyan BD. Underlying mechanisms at the bone-biomaterial interface. *J Cell Biochem* 1994; 56(3): 340–7.
- Ibde S, Konstantinović V, Čutilo B. Der “kleine. Reifenwechsel”: Austausch eines BOI unter der vorhandenen festsitzenden Versorgung. *Dent Implantol* 2002; 6: 358–61.
- Raghavendra S, Wood MC, Taylor TD. Early wound healing around endosseous implants: a review of the literature. *Int J Oral Maxillofac Implants* 2005; 20(3): 425–31.
- Kavita P, Bansi B, Rizvan S. Clinical evaluation of primary stability and osseointegration of endosseous root form implants of different dimensions using periostest. *Indian J Appl Res* 2013; 3(3): 281–3.
- Sennerby L. The implant stability quotient whitebook: the relationship between reliable diagnostics and safe, successful dental implant procedures [livro on line]. Available from: <http://www.osstell.com/filearchi-ve/4/4009/25045-01%20EN%20ISQ%20Whitebook%20lr.pdf>.
- Bilhan H, Geckili O, Mumcu E, Bozdogan E, Simbiuloğlu E, Kutay O. Influence of surgical technique, implant shape and diameter on the primary stability in cancellous bone. *J Oral Rehabil* 2010; 37(12): 900–7.

28. Meredith N. A Review of Nondestructive Test Methods and Their Application to Measure the Stability and Osseointegration of Bone Anchored Endosseous Implants. *Crit Rev Biomed Eng* 1998; 26(4): 275–91.
29. Cassetta M, Ricci L, Lezzi G, Dell'Aquila D, Piattelli A, Perrotti V. Analisis de frecuencia de resonancia de implantes insertados con un procedimiento de injerto simultaneo. *Rev Int Odont Restaur Periodon* 2012; 16(5): 548–57.
30. Konstantinović V, Todorović V, Lazjić V. Possibilities of reconstruction and implant-prosthetic rehabilitation following mandible resection. *Vojnosanit Pregl* 2013; 70(1): 80–5.
31. Esposito M, Hirsch J, Lekholm U, Thomsen P. Biological factors contributing to failures of osseointegrated oral implants, (I). Success criteria and epidemiology. *Eur J OralSci* 1998; 106(1): 527–51.
32. Branemark PI, Hansson BO, Adell R, Breine U, Lindstrom J, Hallen O, et al. Osseointegrated implants in the treatment of the edentulous jaw. Experience from a 10-year period. *Scand J Plast Reconstr Surg Suppl* 1977; 16: 1–132.
33. Adell R, Lekholm U, Rockler B, Brånemark PI. A 15-year study of osseointegrated implants in the treatment of the edentulous jaw. *Int J Oral Surg* 1981; 10(6): 387–416.
34. Ihde S, Konstantinović V. Comparison and definition of the pathological phenomena occurring after a tooth replacement and possible therapeutic stages implying basal and crestal implants. *Implantodontie* 2005; 14: 176–85.
35. Parel SM, Tjellström A. The United States and Swedish experience with osseointegration and facial prostheses. *Int J Oral Maxillofac Implants* 1991;6(1): 75–9.
36. Atsumi M, Park S, Wang H. Methods used to assess implant stability: current status. *Int J Oral Maxillofac Implants* 2007; 22(5): 743–54.
37. Friberg B. On bone quality and implant stability measurements [thesis]. Sweden: University of Gothenburg; 1999.
38. Sullivan DY, Sherwood RL, Collins TA, Krogh PH. The reverse-torque test: a clinical report. *Int J Oral Maxillofac Implants* 1996; 11(2): 179–85.
39. Sánchez SA, Muñoz JI, López MJ. Medición de la estabilidad de los implantes mediante análisis de frecuencia de resonancia. *Rev Int Prótesis Estomatol* 2011; 13(4): 291–302.
40. Cútolí CC, García NM. Carga inmediata en implantes dentales. *Rev Esp Cir Oral y Maxifac* 2005; 27(5): 255–65.
41. Huang H, Pan L, Lee S, Chin C, Fan K, Ho K. Assessing the implant/bone interface by using natural frequency analysis. *Oral Surg Oral Med Oral Pathol Oral Radiol Endod* 2000; 90(3): 285–91.
42. Sennerby L, Meredith N. Analisi della Frequenza di Risonanza (RFA). Conoscenze attuali e implicazioni cliniche. In: Chiapasco M, Gatti C, editors. *Osteointegrazione e Carico Immediato. Fondamenti Biologici e Applicazioni Cliniche*. Milano: Mason, Spa; 2002. p.19–32.
43. Stamatović N, Matic S, Tatic Z, Petković-Curčin A, Vojvodić D, Rakić M. Impact of dental implant insertion method on the peri-implant bone tissue: Experimental study. *Vojnosanit Pregl* 2013; 70(9): 807–16.
44. Boronat-López A, Peñarrocha-Diago M, Martínez-Cortissoz O, Minguéz-Martínez I. Resonance frequency analysis after the placement of 133 dental implants. *Med Oral Patol Oral Cir Bucal* 2006; 11(3): 272–6.
45. Gapski R, Wang H, Mascarenhas P, Lang NP. Critical review of immediate implant loading. *Clin Oral Implants Res* 2003; 14(5): 515–27.
46. Fischer K, Bäckström M, Sennerby L. Immediate and early loading of oxidized tapered implants in the partially edentulous maxilla: a 1-year prospective clinical, radiographic, and resonance frequency analysis study. *Clin Implant Dent Relat Res* 2009; 11(2): 69–80.
47. Ihde S, Konstantinović V. Immediate Loading of Dental Implants: Where is the dip. *Craniomaxillofac Implant Dir* 2007; 2(4): 145–54.
48. Lazjić Z, Bubalo M, Matic S, Stamatović N. Local application of concentrated trombocytes and the level of osseointegration of dental titanium implants: a histomorphometrical analysis. *Vojnosanit Pregl* 2006; 63(8): 731–6. (Serbian)

Received on August 1, 2013.

Revised on November 22, 2013.

Accepted on December 25, 2013.