



ORIGINAL ARTICLE / ORIGINALNI RAD

Endodontic treatment of traumatized teeth with chronic periapical lesions using antibiotic paste and mineral trioxide aggregate obturation – a preliminary study

Bojana Četenović¹, Dejan Marković², James Gutmann³, Tamara Perić², Vukoman Jokanović¹

¹University of Belgrade, Vinča Institute of Nuclear Sciences, Belgrade, Serbia;

²University of Belgrade, School of Dental Medicine, Clinic for Pediatric and Preventive Dentistry, Belgrade, Serbia;

³Texas A&M University, Baylor College of Dentistry, Dallas, TX, USA

SUMMARY

Introduction/Objective The purpose of this study was to assess effectiveness of endodontic root canal procedures in traumatized permanent teeth with necrotic pulps and chronic periapical lesions after definitive obturation with mineral trioxide aggregate (MTA) products. Adobe Photoshop CS (San Jose, CA, USA) image-analysis software was used for healing assessment.

Methods Twenty-seven traumatized single-rooted permanent teeth diagnosed with necrotic pulps and chronic periapical lesions were treated with non-surgical procedure using a tri-antibiotic paste and calcium hydroxide as intra-canal medication. Definitive obturation was performed with ProRoot MTA (Dentsply Tulsa Dental Specialties, Tulsa, OK, USA) or MTA⁺ CerKamed (Cerkamed, Stalowa Wola, Poland). Control follow-ups were done three, six, 12, and 24 months following the completion of treatment.

Results The positive clinical outcome was recorded in 24 (88.9%) cases, while radiographic success was present in 26 (96.3%) cases. A statistically significant decrease in the sizes of periapical lesions was consistently observed at follow-up periods ($p < 0.001$). There was no statistically significant difference between the two tested MTA materials ($p > 0.05$).

Conclusion The MTA products were effective for the root canal obturation and appeared to contribute to the significant reduction or complete regression of periapical lesions in teeth treated. The presented procedure may be proposed for everyday clinical practice.

Keywords: calcium hydroxide; chronic periapical lesions; dental injuries; MTA

INTRODUCTION

Traumatic tooth injuries are common in children and adolescents [1]. Large numbers of these injuries result in endodontic complications such as pulp inflammation, pulp necrosis, root resorption, obliteration of the root canal and development of periapical lesions [2]. Failure to comply with the recommendations of International Association of Dental Traumatology, with respect to clinical and radiographic follow-ups of injured teeth for a longer period of time, often results in a large number of unobserved endodontic complications, unless accompanied by subjective symptoms, like swelling or crown discoloration [3].

For decades, calcium hydroxide formulations have been a material of choice in the treatment of teeth with chronic periapical lesions because of their hygroscopic nature and strong antimicrobial activity [4]. In addition to their use as an inter-appointment intra-canal medicament, they have been proposed for pulp capping, pulp amputation, as well as in the treatment of root perforations, resorptive processes and fractured roots [4]. However, a

possible shortcoming of the use of calcium-hydroxide product is the fact that its use lasts over relatively long period of time; also, there is a possibility of dentin weakening and susceptibility to root fracture [5]. Furthermore, it places a demand on the clinician to place a permanent type of restoration to prevent these possible adverse outcomes.

In the early 1990s, mineral trioxide aggregate (MTA) was presented as a material of choice for surgical root-end fillings [6]. Presently, MTA in all its variants and commercial products, is used in many endodontic and oral surgical procedures with considerable success [6, 7, 8]. MTA achieves good apical sealing, sets even in the presence of moisture and exhibits favorable biocompatibility and bioactivity [9, 10, 11]. Despite its use in various endodontic procedures and apparent advantages of the MTA when used as an apical plug, success in the management of traumatized teeth with chronic periapical lesions has minimal research support [8, 12].

The aim of this study was to assess the effectiveness of endodontic root canal procedures in traumatized permanent teeth with necrotic

Received • Примљено:
March 1, 2018

Revised • Ревизија:
December 6, 2018

Accepted • Прихваћено:
December 24, 2018

Online first: March 14, 2019

Correspondence to:

Bojana ČETENović
University of Belgrade
Vinča Institute of Nuclear Sciences
PO Box 522
11001 Belgrade, Serbia
bcetenovic@vin.bg.ac.rs

pulps and chronic periapical lesions, using tri-antibiotic paste and definitive obturation with MTA products. Healing was assessed by using the Photoshop CS (Adobe, San Jose, CA, USA) image-analysis software.

METHODS

Patients

The study involved 24 patients with a history of tooth trauma, 11 males and 13 females (mean age 13.30 ± 2.83), who came to the University Clinic, between January 2011 and July 2013, due to spontaneous or provoked pain, discomfort during chewing, numbness, or observed swelling. Based on the patients' subjective symptoms, clinical examination, vitality testing and analysis of periapical radiographs, acute exacerbation of necrotic pulp with chronic apical periodontitis was diagnosed, and the need for root canal treatment was determined.

Initially, during the patient screening process, periapical surgical treatment was recommended for all of the patients by their general dentist, and an oral surgery specialist also confirmed this recommendation. Upon personal request by the patients for a second opinion, an additional examination was conducted at the University Clinic.

Inclusion criteria for this study were healthy patients with non-vital tooth with chronic periapical lesions without root resorption, horizontal or vertical root fractures; exclusion criteria were unrestorable tooth, horizontal or vertical root fractures, and root resorption.

Attending parents were provided with a thorough written explanation of proposed non-surgical root canal procedures, their limitations, possible complications, length of the treatment, and observation period. Prior to the patients' participation in this study, written consent was obtained from the parents. This study was approved by the Ethics Committee and registered at the website www.clinicaltrials.org (NCT02625298).

Root canal treatment

Root canal procedures were performed on 27 single-rooted traumatized permanent teeth (18 with mature and nine with immature root development). Following access opening in each tooth, the root canals were gently debrided with a crown-down manual technique using K-files (Dentsply, Maillefer, Switzerland) according to the radiographically determined working lengths. K-files were only used to remove the necrotic tissue and the softened predentinal layer without excessive removal of mineralized dentin, as this might further weaken already thin walls of the root canals, especially those with immature apical development. Subsequently, reshaping of the canal system, followed by a minor curettage of the periapical area through the canal using barbed broaches, was made in order to partially destruct the periapical lesion and provoke bleeding. Irrigation was performed using 2% NaOCl (Chloraxid, Cerkamed, Stalowa Wola, Poland), 0.2% solution of chlorhexidine-

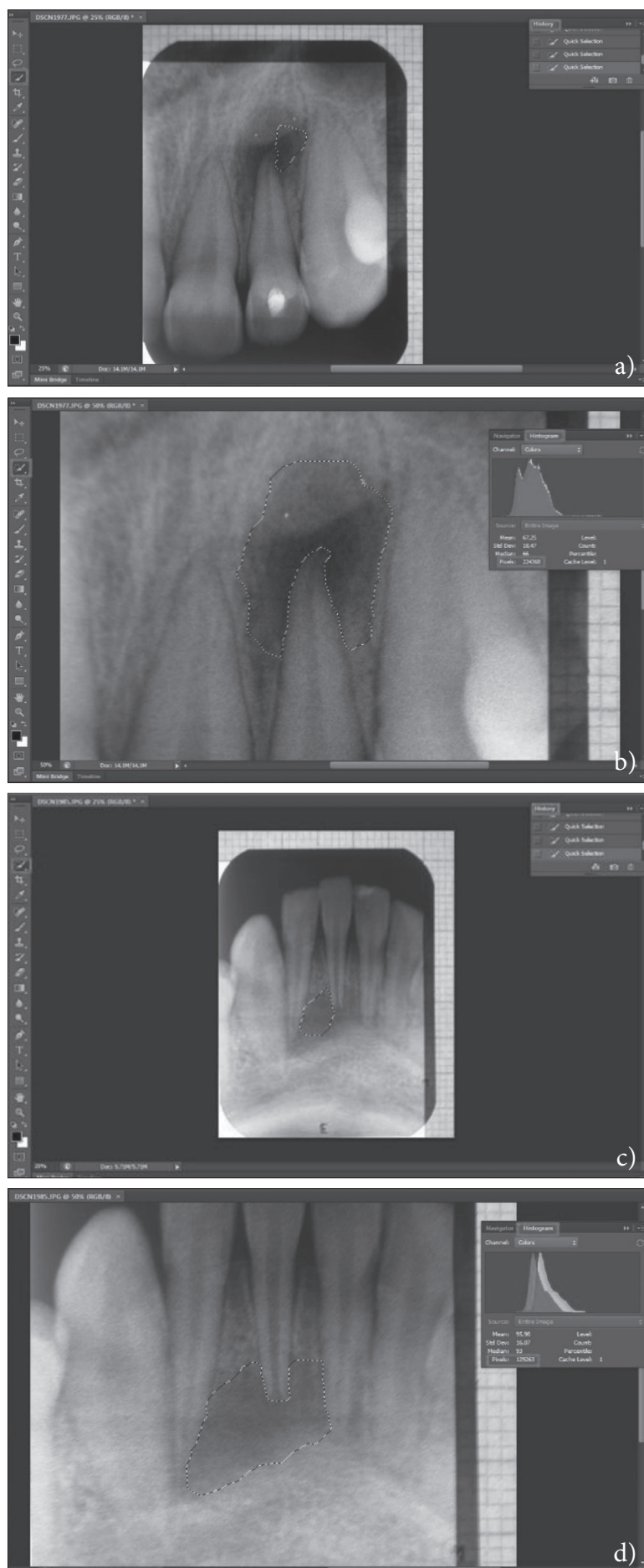
digluconate (Curasept 220, Curadent Swiss GmbH, Kriens, Switzerland) and 40% citric acid solution. The canals were then dried with sterile paper points and filled with calcium hydroxide paste (UltraCal XS, Ultradent Products Inc., South Jordan, UT, USA), which was left in the root canals for at least four weeks, with the maximum of six weeks (UltraCal XS, Ultradent Products Inc., South Jordan, UT, USA). Following this initial disinfection, triple-antibiotics paste (consisting of 200 mg of ciprofloxacin, 500 mg of metronidazole, and 100 mg of minocycline, with macrogol ointment and propylene glycol as carriers) was placed into the canal using a lentula, for a period of seven days. Subsequently, the apical thirds of the root canals were obturated either with ProRoot MTA (Dentsply Tulsa Dental Specialties, Tulsa, OK, USA) or MTA⁺ (Cerkamed) by forming an apical plug 3–5 mm thick. The correct placement of the apical plug was assessed radiographically, and the moist cotton pellet was left in the root canal. The following day, the remaining canal space was filled with a sealer (Acroseal, Septodont, Saint-Maur des Fosses, France) and gutta-percha points (Guttapercha, VDW GmbH, Munich, Germany) using a lateral compaction technique. Coronal parts of root canal systems were sealed using glass-ionomer cement (Fuji IX, GC Int., Tokyo, Japan) with a minimum thickness of 1.5–2 mm. Enamel and dentin conditioning was performed with a self-etching adhesive system (GC G-BOND, GC Int.) and restored using a composite material (Gradia Direct, GC Int.) placed incrementally.

Clinical evaluation

Clinical evaluation of the performed endodontic treatment was done according to data obtained from patients' histories and clinical examinations. The positive clinical outcome comprised the absence of spontaneous or provoked pain, chewing without discomfort, absence of numbness or tenderness to percussion and/or palpation, and absence of tooth mobility, tooth crown discoloration or abscess, and/or sinus tract formation.

Radiographic analysis

Radiological assessment of the outcomes was performed according to the analysis of post treatment radiographs. Periapical radiographs, used for the initial assessment and diagnosis, were defined as the initial radiographs. Further progress in radiographic examination followed the procedures and requirements of the procedures rendered; the post treatment radiographs, made after definitive root canal obturation, were defined as the baseline radiograph (0 m), while the following control radiographs were secured at three, six, 12, and 24 months subsequent to obturation. Uniformity in radiographic exposures was provided with a silicone stabilizer for the purpose of positioning the X-ray tube. All radiographic images were taken using a periapical film (Kodak, Carestream Health Inc., Rochester, NY, USA) with a GE 1000 unit (General Electric, Milwaukee, WI, USA) at 90 kVp, 10 mA, and 0.12 seconds exposure time. The exposed films were developed



in an automatic processor (Dent-X 9000, Dent-X Co., Elmsford, NY, USA) using five minutes of dry-to-dry time.

Radiographs were photographed using a digital camera Kodak EasyShare Max (Z990) with a millimeter measurer in order to obtain the interpretation of sizes of periapical lesions during the conversion of pixels to mm^2 by digital data processing in Adobe Photoshop CS 6 software. Before the radiological assessment analysis, the brightness of the images was enhanced to facilitate observation of the periapical radiolucency. Using a histogram scale, the number of pixels for each lesion was noted (Figure 1 a–d). As the surface area of the image was known, and therefore the number of its pixels was also known, using the proportion, the size of the lesion was measured in mm^2 . Criteria for radiographic assessment are presented in Table 1.

Table 1. Criteria for radiographic assessment

Success	<ul style="list-style-type: none"> • Decrease in size of the periapical lesion as compared with the previous radiograph • Measured value of the periapical lesion less than 3 mm^2 at the recall time of 24 months • No evidence of continuing root resorption • No evidence of root fracture
Uncertain outcome	<ul style="list-style-type: none"> • The size of periapical lesion remained the same
Failure	<ul style="list-style-type: none"> • Evidence that an existing periapical lesion has increased in size • Signs of continuing root resorption • Evidence of root fracture

Randomization and statistical analysis

Patients and clinicians were blinded to the treatment protocol (double-blinded randomization). One examiner (B.C.) randomized the entire sample using odd numbers. Two experienced and calibrated dentists (D.M. or T.P.) performed the radiological analysis independently. Inter-examiner and intra-examiner agreement scores were determined using the kappa

Figure 1. Analysis of radiographs using Adobe Photoshop CS 6 software:

- marking the clear boundaries of periapical lesion step by step using the Quick Selection button;
- determining the pixels of the marked periapical lesion using the Histogram;
- marking clear boundaries of the periapical lesion step by step using the Quick Selection button;
- determining the pixels of the marked periapical lesion using the Histogram

statistics. Data analysis was performed using the linear mixed model. The level of significance was set at $p < 0.05$, and the data was processed using IBM SPSS Statistics, version 20.0 (IBM Corp. Armonk, NY, USA).

RESULTS

Analysis of the patients' data history showed that none of the participants attended all of the control examinations designated by dental trauma protocols. Following an injury, 19 (79.2%) patients attended the first control examination, while after the third, sixth, and 12th month, this number decreased to 13 (54.2%), 10 (41.7%), and five (20.8%), respectively.

Mean time from the incidence of trauma to the occurrence of endodontic complication was 14.01 ± 2.69 months. A total sample consisted of three (11.1%) mandibular central incisors, 16 (59.3%) maxillary central incisors, seven (25.9%) maxillary lateral incisors and one mandibular first premolar (3.7%). Root canal procedures in this study lasted five to seven weeks (5.41 ± 0.67). The positive clinical outcome was recorded in 24 (88.9%) cases, while radiographic success was present in 26 (96.3%) cases (Tables 2 and 3). In one case (3.7%), due to the presence of a sinus tract and vertical root fracture, a single tooth was extracted, while two other cases (7.4%), with crown discolorations, were treated by carbamide peroxide as intracoronary bleaching agent.

The kappa statistics for intra-examiners' reliability ranged 0.69–0.89, while inter-examiners' reliability ranged 0.72–0.86. Statistically significant decreases in the values of the periapical lesions were recorded in all observation periods ($F = 115.966$, $p < 0.001$; Table 3). There were no statistically significant differences between the two used MTA materials ($F = 1.089$; $p = 0.306$), as well as between the teeth with mature and immature roots, regarding positive treatment outcomes ($p > 0.001$).

DISCUSSION

This study, in a certain sense, highlights the advantages of endodontic treatment in the initial management of traumatized teeth with chronic periapical periodontitis, as the initial suggestion was to perform periapical surgery in all the presented patients. On the other hand, results of the present study also show the importance of regular control follow-ups after tooth trauma, recommended by the relevant professional associations as control radiographs were made in two cases (8.3%) at the first control examination, after six months in three cases (12.5%), and no radiographs were made 12 months after the injuries [1, 3].

Trauma was identified as the etiological factor for pulp necrosis and chronic periapical lesions in all of the cases. The most predominant dental injuries were contusions in 13 (48.1%) cases, complicated crown fractures in five (18.5%) cases, while subluxations, uncomplicated crown fracture, as well as uncomplicated crown fractures in combination with teeth intrusions were present in three (11.1%) cases.

Management of teeth with necrotic pulps and chronic periapical lesions ranges from endodontic procedures and surgical approach to tooth extraction depending on the nature of the periapical lesion [13]. In this regard, an estimation of the volume of a periapical lesion is essential. Therefore, the main criterion for evaluation of the size of bone defects in the present study was the analysis of their 2D-radiograph reproductions as is common in daily practice. Using different tools in Adobe Photoshop CS software, the periapical radiolucency can be measured easily and with sufficient precision [14]. Ideally, cone-beam computed tomography evaluations might have provided a different outcome; however, their availability was not feasible at the time of this study, and also implies much higher effective dose of radiation ($61\text{--}134 \mu\text{Sv}$) compared to conventional dental radiography ($0.65\text{--}9.5 \mu\text{Sv}$) [14].

While there may be a significant correlation between the size of a periapical lesion and its true nature, the only

Table 2. Clinical status and outcome

Chewing discomfort (%)	Yes	No	48.1	51.9	7.4	92.6	0	100	0	100	0	100	0	100
Abscess/sinus tract (%)	Yes	No	48.1	51.9	0	100	0	100	3.7	96.3	0	100	0	100
Tooth discoloration (%)	Yes	No	-	-	-	-	0	100	0	100	3.7	96.3	3.7	96.3
Tooth mobility (%)	Yes	No	11.1	88.9	0	100	0	100	0	100	0	100	0	100
Numbness (%)	Yes	No	14.8	85.2	0	100	0	100	0	100	0	100	0	100
Percussion/ palpation tenderness (%)	Yes	No	92.6	7.3	7.4	92.6	0	100	0	100	0	100	0	100
Spontaneous/provoked pain (%)	Yes	No	37	63	0	100	0	100	0	100	0	100	0	100
Radiographic assessment intervals			Initial		Baseline		3 months		6 months		12 months		24 months	

Table 3. Radiographic status and outcome

Time	Success	Uncertain outcome	Failure	Measured values of PL (mm ²) (MV \pm SD)
Initial	-	-	-	35.87 ± 0.24^a
Baseline	27 (100%)	0	0	$17.04 \pm 0.20^{a,b}$
3 months	26 (96.3%)	1 (3.7%)	0	$12.28 \pm 0.40^{b,c}$
6 months	26 (96.3%)	0	1 (3.7%)	$9.65 \pm 0.21^{c,d}$
12 months	26 (96.3%)	0	0	$6.52 \pm 0.17^{d,e}$
24 months	26 (96.3%)	0	0	0.31 ± 0.05^e

PL – periapical lesions, MV – mean value, SD – standard deviation;

^{a,b,c,d,e} statistically significant differences between measured values of PL ($p < 0.001$)

reliable proof of a correct diagnosis becomes possible after histopathological analysis [15, 16]. According to Nair [17], if the periapical lesion is completely separated from the apex of the tooth, it's less probably to be resolved without surgical treatment, but if it is in direct communication with the root canal, it may react favorably to a conservative form of management [18].

Integrity of the periapical area has been the subject of numerous studies in terms of both, instrumentation and medication. Bender [19] indicated that there are studies that claim that jeopardizing integrity of a periapical lesion may lead to an exacerbation of a chronic periapical process; however, Bhaskar [20] suggested that curettage of the periapical area may be useful in destruction or partial elimination of the affected tissue, and in initiating the reparatory processes. In the present study, this therapeutic procedure proved to be effective, though without any clear conclusions whether or not the outcome was due to the apical instrumentation, local pressure reduction, or provoked bleeding.

Numerous studies have shown that the use of calcium hydroxide in the treatment of periapical lesions is efficient, without significant differences between radiographically evaluated small (up to five mm) and large lesions [21, 22]. Although calcium hydroxide formulations possess powerful activity against a wide range of oral pathogens, they have limited effect against *E. faecalis* and *C. Albicans* [4]. As the use of the triple antibiotics may overcome the shortcomings of calcium hydroxide pastes, this was the main aim of its use in the present study, although for a shorter period of time than previously recommended [23, 24].

Annamalai and Mungara [25] reported complete absence of periapical radiolucency that was present at the beginning of the treatment in 13/30 teeth with immature roots obturated with MTA. Using the periapical index score and the decrease in size of the apical lesion with at least 12 months follow-up, Simon et al. [26] demonstrated that the healing occurred in 81% of cases. Similar results were obtained by Holden et al. [27] and Sarris et al. [28]. The present results are in concordance with previous studies, which can also be explained by the fact that MTA-based materials possess a very similar chemical composition. Us-

ing MTA in this study as a root-end closure, both in teeth with complete and in those with incomplete root development, was undertaken because of the enhanced sealing ability of MTA, thereby reducing microleakage [6, 11], which is very important because the presence of residual microorganisms in dentinal tubules is considered the main reason for endodontic treatment failure.

Despite the broad scope of indications, there is still paucity of clinical studies on the use of MTA-based products *in vivo* when used in a manner similar to the present study. Furthermore, according to a literature search, there is a limited number of studies that followed the processes of repair and potential regeneration of chronic periapical lesions of traumatized permanent teeth obturated with MTA-based materials [29]. Even when the clinical situation indicates that a surgical intervention is necessary, continuous reduction of a periapical lesion over time following non-surgical intervention is a beneficial outcome. Moreover, other less invasive and successful options exist when necessary, like decompression of large periapical lesions [30].

CONCLUSION

Treatment of teeth with chronic periapical lesions, as a result of a complication of the previous tooth trauma, should be initiated with endodontic approach. Products based on MTA represent effective agents for apical root canal obturation and contribute to significant reduction or complete regression of periapical lesions. The presented procedure may be proposed for everyday clinical practice as it is easy to perform.

ACKNOWLEDGEMENT

This study was supported by the Ministry of Education, Science and Technological Development of the Republic of Serbia (No. 172026).

Conflict of interest: None declared.

REFERENCES

1. Diangelis AJ, Andreasen JO, Ebeleseder KA, Kenny DJ, Trope M, Sigurdsson A, et al. International Association of Dental Traumatology guidelines for the management of traumatic dental injuries: 1. Fractures and luxation of permanent teeth. *Dent Traumatol.* 2012; 28(1):2–12.
2. Glendor U, Halling A, Andersson L, Eilert-Petersson E. Incidence of traumatic tooth injuries in children and adolescents in the county of Västmanland, Sweden. *Swed Dent J.* 1996; 20(1-2):15–28.
3. Andersson L, Andreasen JO, Day P, Heithersay G, Trope M, Diangelis AJ, et al. International Association of Dental Traumatology guidelines for the management of traumatic dental injuries: 2. Avulsion of permanent teeth. *Dent Traumatol.* 2012; 28(2):88–96.
4. Mohammadi Z, Dummer PM. Properties and applications of calcium hydroxide in endodontics and dental traumatology. *Int Endod J.* 2011; 44(8):697–730.
5. Andreasen JO, Ban Farik B, Munksgaard EC. Long-term calcium hydroxide as a root canal dressing may increase risk of root fracture. *Dent Traumatol.* 2002; 18(3):134–7.
6. Srinivasan V, Waterhouse P, Whitworth J. Mineral trioxide aggregate in paediatric dentistry. *Int J Paediatr Dent.* 2009; 19(1):34–47.
7. Kottoor J, Velmurugan N. Revascularization for a necrotic immature permanent lateral incisor: a case report and literature review. *Int J Paediatr Dent.* 2013; 23(4):310–6.
8. Četenović B, Marković D, Petrović B, Perić T, Jokanović V. Use of mineral trioxide aggregate in the treatment of traumatized teeth in children—Two case reports. *Vojnosanit Pregl.* 2013; 70(8):781–4.
9. da Silva GN, Braz MG, de Camargo EA, Salvadori DM, Ribeiro DA. Genotoxicity in primary human peripheral lymphocytes after exposure to regular and white mineral trioxide aggregate. *Oral Surg Oral Med Oral Pathol Oral Radiol Endod.* 2006; 102(5):e50–4.

10. Guven G, Cehreli ZC, Ural A, Serdar MA, Basak F. Effect of mineral trioxide aggregate cements on transforming growth factor beta1 and bone morphogenetic protein production by human fibroblasts in vitro. *J Endod.* 2007; 33(4):447–50.
11. Chng HK, Islam I, Yap AU, Tong YW, Koh ET. Properties of a new root-end filling material. *J Endod.* 2005; 31(9):665–8.
12. Cohn SA. Treatment choices for negative outcomes with non-surgical root canal treatment: non-surgical retreatment vs. surgical retreatment vs. implants. *Endod Topics.* 2005; 11(1):4–24.
13. Van der Borden WG, Wang X, Wu MK, Shemesh H. Area and 3-dimensional volumetric changes of periapical lesions after root canal treatments. *J Endod.* 2013; 39(10):1245–9.
14. Carvalho FB, Gonçalves M, Tanomaru-Filho M. Evaluation of chronic periapical lesions by digital subtraction radiography by using Adobe Photoshop CS: a technical report. *J Endod.* 2007; 33(4):493–7.
15. Zain RB, Roswati N, Ismail K. Radiographic evaluation of lesion sizes of histologically diagnosed periapical cysts and granulomas. *Ann Dent.* 1989; 48(2):3–5.
16. Becconsall-Ryan K, Tong D, Love RM. Radiolucency inflammatory jaw lesions: a twenty-year analysis. *Int Endod J.* 2010; 43(10):859–65.
17. Nair PN. New perspectives on radicular cysts: do they heal? *Int Endod J.* 1998; 31(3):155–60.
18. Simon JHS. Incidence of periapical cysts in relation to the root canal. *J Endod.* 1980; 6(11):845–8.
19. Bender IB. A commentary on General Bhaskar's hypothesis. *Oral Surg Oral Med Oral Pathol.* 1972; 34(3):469–76.
20. Bhaskar SN. Nonsurgical resolution of radicular cysts. *Oral Surg Oral Med Oral Pathol.* 1972; 34(3):458–68.
21. Lin LM, Ricucci D, Lin J, Rosenberg PA. Nonsurgical root canal therapy of large cyst-like inflammatory periapical lesions and inflammatory apical cysts. *J Endod.* 2009; 35(5):607–15.
22. Maalouf EM, Gutmann JL. Biological perspectives on the non-surgical endodontic management of periradicular pathosis. *Int Endod J.* 1994; 27(3):154–62.
23. Trope M. Treatment of immature teeth with non-vital pulps and apical periodontitis. *Endod Topics.* 2006; 14(1):51–9.
24. Windley W 3rd, Teixeira F, Levin L, Sigurdsson A, Trope M. Disinfection of immature teeth with a triple antibiotic paste. *J Endod.* 2005; 31(6):439–43.
25. Annamalai S, Mungara J. Efficacy of Mineral Trioxide Aggregate as an Apical Plug in Non-Vital Young Permanent Teeth: Preliminary Results. *J Clin Pediatr Dent.* 2010; 35(2):149–55.
26. Simon S, Rilliard F, Bernal A, Machtou P. The use of mineral trioxide aggregate in one-visit apexification treatment: a prospective study. *Int Endod J.* 2007; 40(3):186–97.
27. Holden DT, Schwartz SA, Kirkpatrick TC, Schindler WG. Clinical outcomes of artificial root-end barriers with mineral trioxide aggregate in teeth with immature apices. *J Endod.* 2008; 34(7):812–7.
28. Sarris S, Tahmassebi JF, Duggal MS, Cross IA. A clinical evaluation of mineral trioxide aggregate for root-end closure of non-vital immature permanent incisors in children—a pilot study. *Dent Traumatol.* 2008; 24(1):79–85.
29. Witherspoon DE, Small JC, Regan JD, Nunn M. Retrospective analysis of open apex teeth obturated with mineral trioxide aggregate. *J Endod.* 2008; 34(10):1171–6.
30. Gutmann JL, Ferreyra S. Alternative and contemporary management of large periradicular lesions. *ENDO (Lond Engl).* 2010; 4(2):127–44.

Ендодонтско лечење трауматизованих зуба са хроничним периапикалним лезијама применом антибиотске пасте и оптурације минералним триоксидним агрегатом – прелиминарна студија

Бојана Ћетеновић¹, Дејан Марковић², Џејмс Гатман³, Тамара Перић², Вукоман Јокановић¹

¹Универзитет у Београду, Институт за нуклеарне науке „Винча“, Београд, Србија;

²Универзитет у Београду, Стоматолошки факултет, Клиника за педијатријску и превентивну стоматологију, Београд, Србија;

³Универзитет „А&М Тексас“, Колеџ „Бејлор“, Далас, Тексас, САД

САЖЕТАК

Увод/Циљ Сврха ове студије била је процена ефикасности ендодонтског третмана трауматизованих сталних зуба са некротичном пулпом и хроничним периапикалним лезијама после дефинитивне оптурације минералним триоксидним агрегатом (МТА). Софтвер за анализу слике *Adobe Photoshop CS* коришћен је за процену регенерације.

Метод Двадесет и седам трауматизованих једнокорених сталних зуба са некротичном пулпом и хроничним периапикалним лезијама третирани су нехируршким процедурама помоћу триантибиотске пасте и калцијум-хидроксида као интраканалног медикамента. Дефинитивна оптурација изведена је помоћу *ProRoot* МТА или МТА⁺ *Cerkamed*. Контролни прегледи обављени су три, шест, 12 и 24 месеца после завршетка лечења.

Резултати Позитиван клинички исход забележен је у 24 (88,9%) случаја, док је радиографски успех био присутан у 26 (96,3%) случаја. Статистички значајно смањење величине периапикалних лезија примећено је у свим периодима ($p < 0,001$). Није било статистички значајне разлике између два тестирана МТА материјала ($p > 0,05$).

Закључак МТА производи су ефикасни у оптурацији коренских канала и чини се да доприносе значајном смањењу или потпуној регресији периапикалних лезија у третираним зубима. Приказана методологија може бити предложена за свакодневну клиничку праксу.

Кључне речи: калцијум-хидроксид; хроничне периапикалне лезије; повреде зуба; МТА