



Effects of calcitonin and calcium medication in treatment of edentulous osteoporotic mandible

Efekti primene kalcitonina i kalcijuma u lečenju bezubih pacijenata sa osteoporoznim mandibulama

Srdjan D. Poštić

Clinic of Dental Prosthetic, Faculty of Dental Medicine, University of Belgrade, Belgrade, Serbia

Abstract

Background/Aim. In addition to damage of the bones that support the remaining teeth, degradation of osteoporotic oral bones also lead to a consequent reduction of supporting tissues and the loss of dentures retention. The aim of this study was to assess the clinical and radiographic outcomes following injection of a calcitonin and calcium solution into the buccal aspects of edentulous mandibles.

Methods. The experimental group of 67 edentulous patients diagnosed with osteoporosis, and the control group of 19 nonosteoporotic edentulous patients were treated with the calcitonin and calcium once solution per month. Mandibular bone density was measured from panoramic radiographs, supplemented by T scores of skeletal density in the experimental group. **Results.** After the therapy, measurements showed moderate increases in bone density, compensating for up to 4% of the total loss of minerals and solidity of denture-bearing areas of osteoporotic mandibles. Osteoporosis affected women earlier than men in this study. **Conclusion.** Application of a calcitonin and calcium solution is a suitable method of preprosthetic therapy for edentulous osteoporotic patients.

Key words:

osteoporosis; mandible; mouth, edentulous; calcitonin; calcium; treatment outcome.

Apstrakt

Uvod/Cilj. Degradacija osteoporoznih viličnih kostiju vodi ka oštećenju kostiju koje podržavaju preostale zube, ali i posledičnoj redukciji potpornog tkiva i gubitku retencije proteze. Cilj rada bio je da se procene klinički i radiografski parametri posle tretmana bezubih mandibula rastvorom kalcitonina i kalcijuma ubrizganog u bukalne recesuse. **Metode.** Ispitnu grupu činilo je 67 bezubih pacijenata sa dijagnostikovanom osteoporozom, a kontrolnu grupu 19 bezubih pacijenata sa normalnom gustinom kosti (bez osteoporoze). Svi ispitanici dobijali su rastvor kalcitonina i kalcijuma jednom mesečno. Gustina kosti mandibule merena je na osnovu ortopantomograma svih ispitivanih pacijenata, uz komplementarni T-nalaz gustine skeleta na sistemskom nivou kod pacijenata iz ispitne grupe. **Rezultati.** Po završenoj terapiji utvrđen je umeren porast gustine kosti, čime je nadoknađeno oko 4% ukupnog gubitka mineralnih supstanci u regionima nosećeg tkiva osteoporoznih mandibula. Osteoporoza je zahvatala kosti žena ranije od kostiju muškaraca u ovoj studiji. **Zaključak.** Primena rastvora kalcitonina sa kalcijumom predstavlja kvalitetan metod medikacije i preprostetske pripreme bezubih pacijenata obolelih od osteoporoze.

Ključne reči:

osteoporoza; mandibula; bezubost; kalcitonin; kalcijum; lečenje, ishod.

Introduction

Osteoporotic microstructural degradation and macroscopic reduction of the oral bones have been described in the literature¹. Degradation of osteoporotic oral bones has been reported not only to damage the bone supporting the remaining teeth, but also to lead to a consequent reduction of supporting tissues and the loss of dentures retention². Analysis of the bone layer appearance on panoramic radiographs was used to assess changes in any parameters of turnover of jaw bones^{3–5}.

Calcitonin accelerates influx of calcium, improving bone mineral content and bone density⁶. For this research it was speculated that these positive effects on osteopenic and osteoporotic bones could finally be achieved in the mandible, as well as in other human bones.

Considering various data available on multiple drug therapy and possible effects of systemic medication, it could be of particular importance to focus on dependable approaches to oral treatment of osteoporosis.

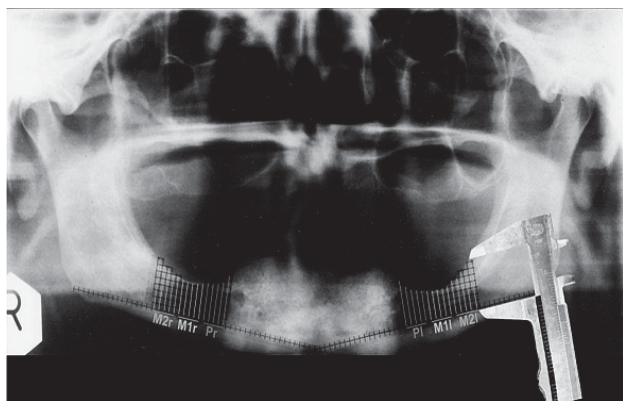
The aim of this study was to assess the effectiveness of local jaw therapy with calcitonin and calcium, used within

preprosthetic and prosthetic therapy of selected edentulous osteoporotic patients.

Methods

The study included 67 edentulous patients – 11 men, aged 64–80 (mean age 71 years) and 56 women, aged 55–79 (mean age 56 years) in the experimental group, and 19 edentulous patients – 9 men, aged 55–65 (mean age 59 year), and 10 women, aged 40–55 (mean age 53.5 year), with well-pronounced edentulous ridges and with normal bone density, as the controls. Edentulous patients were selected based on a questionnaire concerning previous medical treatments for osteoporosis, skeletal density, history of fractures of any bones, postmenopausal periods in women, calcium and microelements of blood-plasma, as well as oral status of bone consistency or reduction. No patients had any malignancy or manifest destructions in the mouth.

Skeletal density analysis was performed on a scanner (Lunar DPX-L, GE Healthcare, Piscataway, NJ) and T scores of the patients were obtained, indicating low bone density and systemic osteoporosis in the experimental group. Scanning was done for at least three of lumbar vertebral bodies in the regions of L1-L4 lumbar vertebrae of the experimental group patients. Panoramic radiographs (Orthopantomograph 10-serial no. 01492, Siemens, Germany) of every patient in the experimental group were focused on degradations in the osteoporotic jaw (Figure 1a) at baseline. Panoramic radiographic finding of a patient from the control group before application of calcitonin and calcium solution is shown in



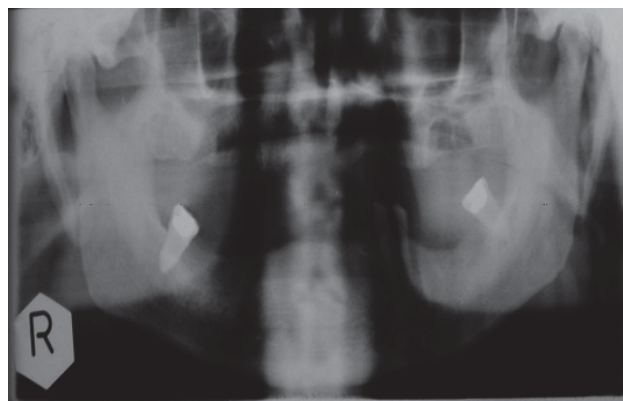
a)

submucosally adjacent to the mandibular bone surfaces (Figure 2). A total of 5 doses were applied to both the right and

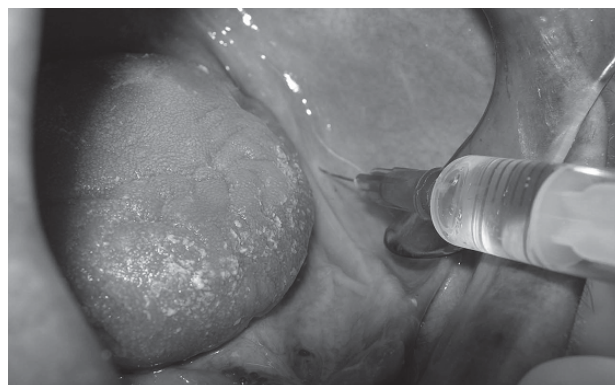

Fig. 2 – Submucosal injection of a calcitonin and calcium solution in the buccal aspect of osteoporotic mandible of the experimental group patient.

left sides of the osteoporotic mandible at monthly intervals, to each patient of both groups. This treatment was administered over a 4-month period. The final separate dose of calcitonin and calcium solution was applied only to each patient of the experimental group at recalls, after 4 months, but not later than 6 months of follow-up. For the patients of the control group calcitonin and calcium was applied after tooth extractions to consolidate the buccal bone and accelerate recovery of post-extraction wounds, but also for preventing bone loss and to compare increments of bone densities between the control group and the experimental group. Pano-



b)

Fig. 1 – a) A grid positioned in the regions of particular interest for panoramic radiograph of osteoporotic edentulous mandible and the determined regions – Pr, M1r, M2r, Pl, M1r, M2r (Pr – region of missing premolar to the right side of the mandible; M1r – region of missing the 1st molar to the right side of the mandible; M2r – region of missing the 2nd molar to the right side of the mandible; Pl – region of missing premolar to the left side of the mandible; M1l – region of missing the 1st molar to the left side of the mandible; M2l – region of missing the 2nd molar to the left side of the mandible); b) – Panoramic radiograph of the control group patient before application of calcitonin and calcium solution.

Figure 1b). Calcitonin (Miacalcic, Novartis, Switzerland, and Huber, Galenika A.D., Serbia), and calcium (Calcium-gluconate Sterop, Belgium; Calcium-Sandoz, 10% calcium gluconas amp., Sandoz Switzerland) were used locally to improve solidity of edentulous mandibles. After local anesthetic application, up to 1.5 mL of a solution containing calcitonin and calcium (2 : 1 ration in one dose) was injected

panoramic radiographs of the patients were taken after each application of the solution (Figure 3). Complete dentures (CD) were fabricated for each patient of both groups. All of the patients had complete dentures during the experimental period. During the period of application of the solution containing calcitonin and calcium, a digital densitometer (DT II 05, U.K.) was used to analyse the bone density of mandibu-

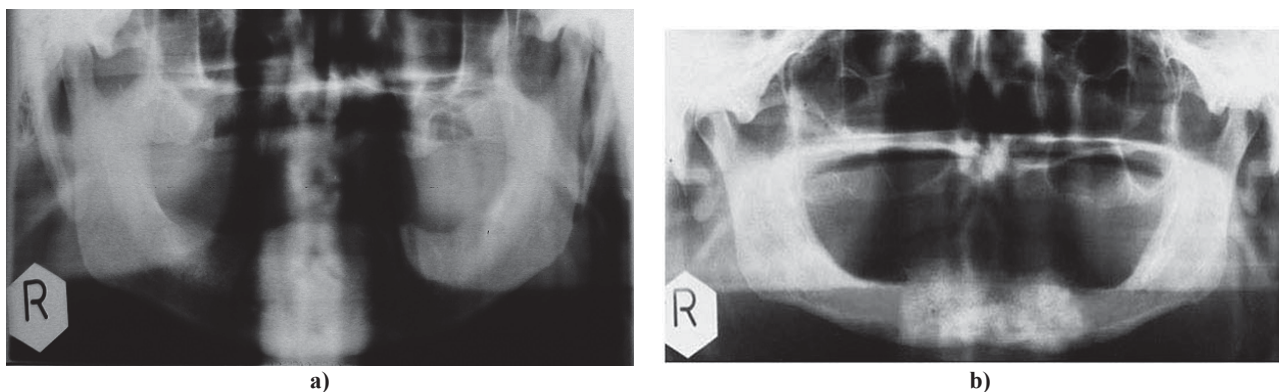


Fig. 3 – a) Panoramic radiograph of the control group patient after application of calcitonin and calcium solution; b) – Panoramic radiograph of a patient, exposing a local increment in density edentulous mandible (for comparisson see Fig. 1).

lar segments on panoramic radiographs. Measurements of the density of the mandibles were taken over the 4 month period of application of solution. Numerical values of bone density on radiograph were shown on digital densitometer representing intensity of entry of focused beam of light into the determined region of dental panoramic radiographs, and these values were expressed in arbitrary units of U/mm^2 .

The Student's *t*-test, ANOVA, Pearson's correlation coefficient and calculation of the incremental trend were used for mandibular density analysis.

Results

Before administration of the calcitonin and calcium solution, T-scores from DPX scanning were up to -2.6 for the men and women of the experimental group.

The results of medication for osteoporotic oral bones were favourable in this study. The incremental changes in density of mandibular segments were compared between the experimental and the control group at each time point, as well as between the experimental group and the control group during the therapy.

with R 1.0065 (0.65%), M2r ($p < 0.05$) with R 1.0062 (0.62%) and M2l ($p < 0.05$) with R 1.0060 (0.60%). Density increased further after the 2nd month of application and was significantly increased for Pr ($p < 0.05$) with R 1.0087 (0.87%), for Pl ($p < 0.05$) with R 1.0084 (0.84%), for M1r ($p < 0.05$) with R 1.0074 (0.74%), for M1l ($p < 0.05$) with R 1.0073 (0.73%), M2r ($p < 0.05$) with R 1.0066 (0.66%) and M2l ($p < 0.05$) with R 1.0065 (0.65%). Mandibular density comparison at baseline and after the 3rd month of application showed that it was a significant change in density for Pr ($p < 0.01$) with R 1.0117 (1.17%), for Pl ($p < 0.01$) with R 1.0114 (1.14%), for M1r ($p < 0.01$) with R 1.007 (1.07%), for M1l ($p < 0.01$) with R 1.0094 (0.94%), M2r ($p < 0.05$) with R 1.0083 (0.83%) and M2l ($p < 0.05$) with R 1.0079 (0.79%).

Following application of the calcium and calcitonin solution, the increase in density was significant for Pr, Pl ($p < 0.01$), M1r, M1l, M2r and M2l segments ($p < 0.05$), with respect to the baseline (Table 1), compensating for up to 4% of the total loss of jaw bone mineral in the experimental group. In the control group, a statistically small increase in bone density ($p < 0.05$) was observed in a premolar and the 1st missing molar regions (Table 1).

Table 1
Mandibular bone density in the control and experimental groups at baseline and after administration of calcitonin with ionized calcium solution

Segment	Control group				Correlation coefficient	Experimental group			
	Digital value of density			Correlation coefficient		Digital value of density			Correlation coefficient
	before therapy	after therapy	<i>p</i>			before therapy	after therapy	<i>p</i>	
Pr	1.01 ± 0.6	1.83 ± 0.7	< 0.05	0.578	-1.42 ± 0.8	0.21 ± 0.7	< 0.01	0.814	
Pl	1.03 ± 0.8	1.92 ± 0.4	< 0.05	0.542	-1.40 ± 0.9	0.19 ± 0.6	< 0.01	0.793	
M1r	0.83 ± 0.8	1.79 ± 0.8	< 0.05	0.528	-1.34 ± 0.8	-0.24 ± 0.9	< 0.05	0.637	
M1l	0.79 ± 0.9	1.76 ± 0.9	< 0.05	0.519	-1.33 ± 0.7	-0.21 ± 0.9	< 0.05	0.619	
M2r	1.61 ± 0.5	1.83 ± 0.3	> 0.05	0.394	-1.11 ± 0.9	0.61 ± 0.5	< 0.05	0.593	
M2l	1.52 ± 0.8	1.85 ± 0.3	> 0.05	0.367	-1.11 ± 0.4	0.62 ± 0.6	< 0.05	0.607	

Numerical values of density are in arbitrary units (U/mm^2) showing the intensity of light beam entry through the determined region of dental radiograph.

When mandibular density was compared in the experimental group at baseline and after the 1st month of the therapy, differences were significant for the segments Pr ($p < 0.05$) with tempo and range of increment of density (R) 1.0080 (0.80%), for Pl ($p < 0.05$) with R 1.0078 (0.78%), for M1r ($p < 0.05$) with R 1.0067 (0.67%), for M1l ($p < 0.05$)

Discussion

In the dental literature there are few reports on treatment and local medication for osteoporotic oral bones.

Based on convincing medical studies on patients, with systemic osteoporosis, the two foremost treatment approaches

could be described: the first related to application of bisphosphonates^{7,8}, while the second considered calcitonin as the primary accelerator of calcium influx to the bone^{6,7}.

Making an allowance for various facts derived from studies conducted on patients undergoing systemic therapy with bisphosphonates, and a few studies on local application of bisphosphonates, as well as for the fact that certain interruptions of immune-response were described as a possible complication of extended bisphosphonate usage⁹, therapy with a solution containing only calcitonin and calcium, administered locally to osteoporotic jaws, seemed a rational option.

Calcitonin has been recognized as the primary substance that strongly regulates the influx of calcium⁶. Calcium influx should have been provided by mobilization of calcium ions in plasma, as well as by exchanging calcium ions from pharmacological calcium gluconate and calcium gluconas. Respecting the fact that human osteoporotic mandible may not be very well provided with plentiful blood supply, it was assumed that calcium ions in blood vessels of the mandible would not have provided sufficient calcium influx to prevent osteoporotic degradation. Furthermore, additional sources of calcium ions, directed towards credible local storage in close proximity to the mandible, should have a beneficial effect.

In the dental literature, there were few reports on the local application of calcitonin and calcium to hard oral tissues *in vivo*.

On the strength of the results of this study, it appears that the solution of calcitonin and calcium should be applied to the edentulous ridge prior to positioning of a denture onto supporting tissues.

Careful selection of patients concerning the absence of infectious diseases, malignancy, serious kidney problems or blood diseases, is of ultimate priority when considering local application of calcitonin and calcium solution to oral bones.

Repeated application of calcitonin and calcium solution to jaw bone layers may significantly improve the mineral

content of bone, bone density, the condition of the bone and the potential of the area to support dentures. Osteoporotic edentulous mandibles should be the first of all oral bones to benefit from a solution containing calcitonin and calcium. Additionally, respecting the levels of concentration of calcium ions applied, osteoporotic maxillary bone could be treated with a solution of the same kind, over a prolonged period of remedial use.

A probable contraindication for local oral application of calcitonin and ionized calcium in solution should be a very intensive reduction of edentulous ridges with the alveolar crest positioned under the superficial surface of the mylohyoid muscle of the edentulous mouth floor.

Calcitonin accelerated influx of calcium into the mandibles of all the patients in both groups.

Since osteoporosis frequently affects women, mandible osteoporosis is likely to affect women rather than men. The use of calcitonin and calcium for osteoporotic toothless patients should be considered the priority for local oral care. In spite of the limited value of local application, calcitonin and calcium should be the prerequisite foundation for positive bone remodelling and turnover of segments of the jaw. Regardless the absence of macroscopically distinct bone regeneration, local application of calcitonin with calcium could be crucial for success at the first point of positive bone remodelling and turnover, and for laying the foundation for later restorative procedures in oral rehabilitation of osteoporotic patients.

Conclusion

The use of calcitonin and calcium solution should be considered the priority in preprosthetic and prosthetic therapy of edentulous osteoporotic patients. This medication compensated for the loss of mineral from the jaw. Application of a calcitonin and calcium solution seems to be a suitable method of preprosthetic therapy for edentulous osteoporotic patients.

R E F E R E N C E S

1. *Kleerekoper M.* Osteoporosis prevention and therapy: preserving and building strength through bone quality. *Osteoporos Int* 2006; 17(12): 1707–15.
2. *von Wovern N.* General and oral aspects of osteoporosis: a review. *Clin Oral Invest* 2001; 5(2): 71–82.
3. *Horner K, Devlin H.* Clinical bone densitometric study of mandibular atrophy using dental panoramic tomography. *J Dent* 1992; 20(1): 33–7.
4. *Yaşar F, Akgünlü F.* The differences in panoramic mandibular indices and fractal dimension between patients with and without spinal osteoporosis. *Dentomaxillofac Radiol* 2006; 35(1): 1–9.
5. *Mohammad AR, Alder M, McNally MA.* A pilot study of panoramic film density at selected sites in the mandible to predict osteoporosis. *Int J Prosthodont* 1996; 9(3): 290–4.
6. *Chesnut CH 3rd, Azria M, Silverman S, Engelhardt M, Olson M, Mindeholm L.* Salmon calcitonin: a review of current and future therapeutic indications. *Osteoporos Int* 2008; 19(4): 479–91.
7. *Postic S.* Therapy and prosthetic management of edentulous osteoporotic mandibles. Belgrade: Zadužbina Andrejevic; 2010. p. 46–58. (Serbian)
8. *Cardona JM, Pastor E.* Calcitonin versus etidronate for the treatment of postmenopausal osteoporosis: A meta analysis of published clinical trials. *Osteoporos Int* 1997; 7(3): 165–74.
9. *Ruggiero S, Mehrotra B.* Bisphosphonate related osteonecrosis of the jaw: diagnosis, prevention and treatment. *Annu Rev Med* 2008; 60: 85–96.

Received on December 19, 2011.

Revised on February 23, 2012.

Accepted on March 12, 2012.