

Rhinoplasty: The Nasal Bones – Anatomy and Analysis

Goran D. Lazovic, MD, MSc; Rollin K. Daniel, MD, MSc;
Ljiljana B. Janosevic, MD, PhD; Rade M. Kosanovic, MD, PhD;
Miodrag M. Colic, MD, PhD; and Aaron M. Kosins, MD

Aesthetic Surgery Journal
2015, Vol 35(3) 255–263
© 2015 The American Society for
Aesthetic Plastic Surgery, Inc.
Reprints and permission:
journals.permissions@oup.com
DOI: 10.1093/asj/sju050
www.aestheticsurgeryjournal.com

OXFORD
UNIVERSITY PRESS

Abstract

Background: The analysis of nasal anatomy, and especially the nasal bones including the osseocartilaginous vault, is significant for functional and aesthetic reasons.

Objectives: The objective was to understand the anatomy of the nasal bones by establishing new descriptions, terms, and definitions because the existing parameters were insufficient. Adequate terminology was employed to harmonize the anthropometric and clinical measurements.

Methods: A two-part harvest technique consisting of resecting the specimen and then creating a replica of the skull was performed on 44 cadavers to obtain specific measurements.

Results: The nasal bones have an irregular, variable shape, and three distinct angles can be found along the dorsal profile line beginning with the nasion angle (NA), the dorsal profile angulation (DPA) and the kyphion angulation (KA). In 12% of cases, the caudal portion of the nasal bones was straight and without angulation resulting in a “V-shape” configuration. In 88% of cases, the caudal portion of the bone was angulated, which resulted in an “S-shape” nasal bone configuration. The intervening cephalic bone, nasion to sellion (N-S), represents the radix while the caudal bone, sellion to r (S-R), represents the bony dorsum.

Conclusions: By standardizing and measuring existing nasal landmarks and understanding the different anatomic configurations of the nasal bones, rhinoplasty surgeons can better plan their operations within the radix and bony and osseocartilaginous vaults.

Accepted for publication August 11, 2014.

Surgeons are familiar with the clinical nasofrontal and nasofacial angle for surgical planning. However, there is little in-depth analysis available of the actual nasal bone configurations and their relationship to the type of nasal hump which requires removal. The present anatomic study was undertaken to define the angulations intrinsic to the nasal bones and to improve operative planning for rhinoplasty surgery.

Terminology

Nasal terminology is often difficult because differences exist between classic anthropometric bony measurements¹ and clinical soft tissue measurements.²⁻⁴ Because this study was performed on skull samples, classic anthropometric

Dr Lazovic is Clinical Assistant Professor of Plastic Surgery, University of Belgrade, School of Medicine, Belgrade, Serbia; and Clinic of Burns, Plastic, and Reconstructive Surgery, Clinical Center of Serbia, Belgrade, Serbia. Dr Daniel is Clinical Professor of Plastic Surgery and Dr Kosins is Clinical Assistant Professor, Aesthetic and Plastic Surgery Institute, University of California, Irvine, Orange, California.

Dr Janosevic is Professor of Otorhinolaryngology, University of Belgrade, School of Medicine, Belgrade, Serbia; and Clinic of ENT and MFS, Clinical Center of Serbia, Belgrade, Serbia. Dr Kosanovic is a Professor of Otorhinolaryngology, Faculty of Stomatology, University of Belgrade, Belgrade, Serbia; and Clinic of ENT and MFS, Clinical Center Zvezdara, Belgrade, Serbia. Dr Colic is a plastic surgeon in private practice in Belgrade, Serbia.

Corresponding Author:

Goran D. Lazovic, MD, MSc, Resavska 2, 11000 Belgrade, Serbia.
E-mail: dr_lazovic@yahoo.com

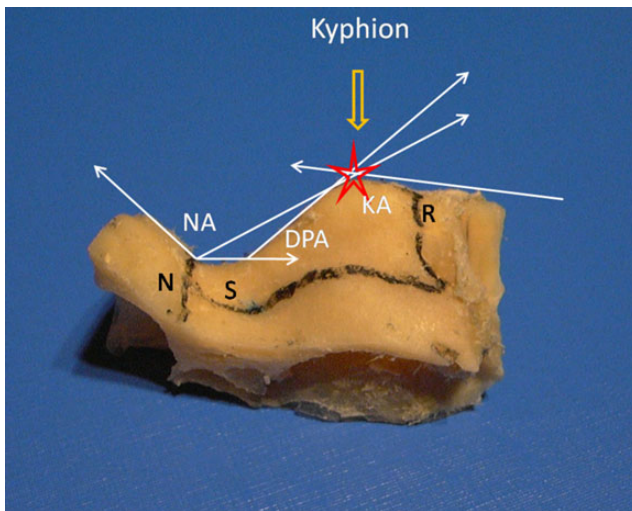


Figure 1. Nasal bone angles and points. The red star is the kyphion, or most prominent portion of the nasal hump. The yellow arrow points to this point.

terminology will be utilized followed by a discussion of possible clinical correlations (see Figure 1).

Points

Nasion (N) is the midpoint of the nasofrontal suture line where the frontal bone and nasal bones join.

Sellion (S) is the deepest depression of the nasal bones and often coincides with soft tissue nasion.

When using pretreatment clinical photographs, clinicians⁵ virtually always call the sellion the nasion in their treatment planning.

Kyphion (K) is the most prominent point on the bony nasal dorsum.

Rhinion (R) is the most caudal point of the paired nasal bones and marks the midline junction of the bony and cartilaginous vaults.

Cephalic portion of nasal bones (CeP) is between the Nasion (N) and the Sellion (S).

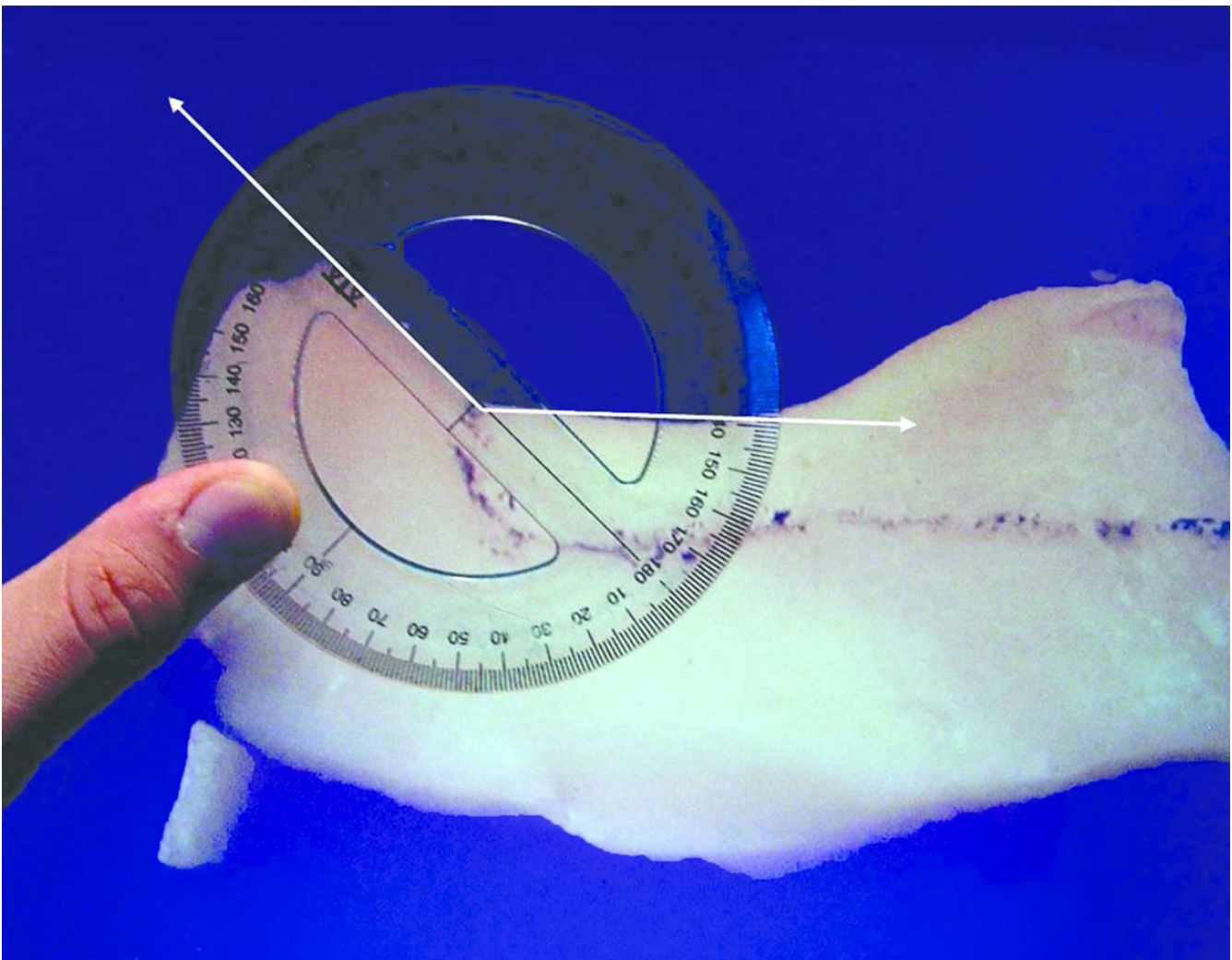


Figure 2. Measurement of the Nasion angle (NA).

Caudal portion of nasal bones (CaP) is between the Sellion (S) and the Rhinion point (R).

Angles

Nasion angle (NA) is the angle measured on the bony surface between the frontal bone and the cephalic portion of the nasal bone⁶ (see Figure 2).

Nasofrontal angle (NFA) is defined by the intersection of a line tangent to the glabella and the dorsal line passing from the nasion to tip.^{7,8} The clinical NFA is dramatically different from the bony surface NA. During pretreatment planning, surgeons draw the glabella limb as a tangent to the glabellar prominence. Next, the “dorsal line” is drawn from the tip retrograde until it intersects with the glabella tangent line. In contrast the NA is a true bony surface angle between frontal bone and nasal bone. Thus, the NFA is a soft tissue clinical planning tool rather than a true anthropometric measurement (NA).

Dorsal Profile Angle (DPA) is defined by the intersection between a line drawn tangent to the Sellion and a line tangent to the bony hump irrespective of the tip location with the intersection usually occurring at the Sellion point (S) (see Figure 3).

Kyphion Angle (KA) is defined by the intersection of a line drawn tangent to the bony hump and a line drawn tangent to the rhinion with the intersection defined as the Kyphion point (K) (see Figure 4).

These latter two angles represent the first attempt to define the bony hump. These angles and their presence or absence is determined by the configuration of the nasal bones.

Nasal Bone Configurations

The configuration of the nasal bones can be defined and divided based on their intrinsic angulation. Three sequential points are marked: Sellion (S), Kyphion (K), and Rhinion (R).

V-shaped nasal bones have essentially a straight line configuration from S to R and thus one locus of angulation located at the DPA (see Figure 5).




Figure 3. Measurement of the Dorsal Profile Angle (DPA).

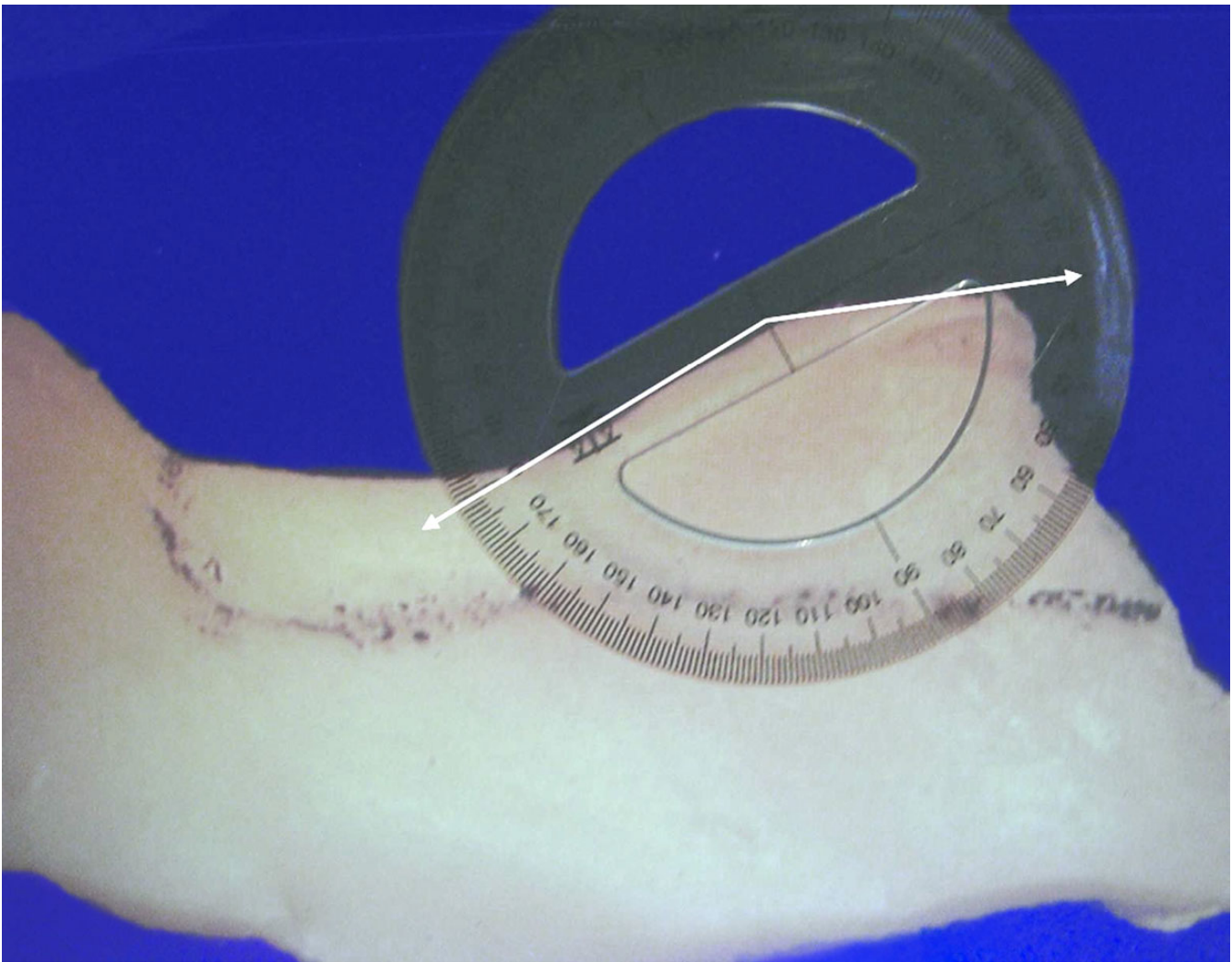


Figure 4. Measurement of the Kyphion Angle (KA).

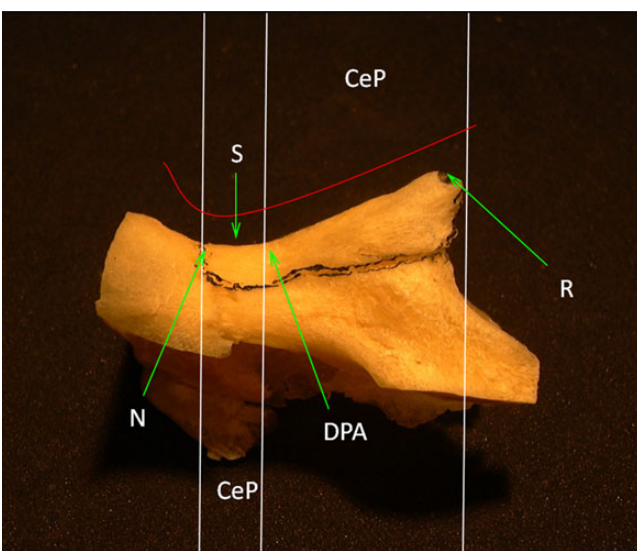


Figure 5. “V-shaped” nasal bones, CeP, Cephalic portion; CaP, Caudal Portion; N, Nasion and S, Sellion; DPA, Dorsal profile angulation.

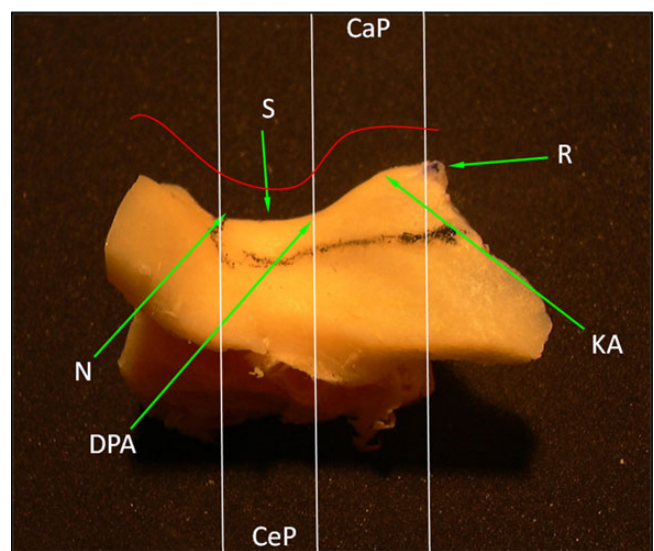


Figure 6. “S-shaped” nasal bones, CeP, cephalic portion; CaP, caudal portion; N, Nasion; S, Sellion; DPA, Dorsal profile angulation; KA, Kyphionic angulation; R, Rhinion.

S-shaped nasal bones have a curved line, which begins at S, passes to a distinct point at K, and plateaus at R. There are two loci of angulation – one located at the DPA and one at the KA (see Figure 6).

METHODS

Forty-four cadavers were obtained from the Institute of Forensic Medicine at the University of Belgrade Medical School during the period 1995 to 2005. Exclusion criteria consisted of any serious injuries of the nose or face. A two-part harvest technique was developed consisting of resecting the specimen and then creating a replica of the skull. The resected en-bloc specimen consisted of the following: nasal plus adjacent portions of frontal bone, frontal processes of the maxillary bone, nasal septum, and upper lateral cartilages. The resection was performed with an electrical craniotome in four lines: 1) the frontal line, parallel to the nasofrontal suture line and down into the ethmoidal cells, 2) the two lateral lines, straight across the frontal process of the maxillary bone 5 mm lateral from the nasomaxillary junction, and 3) the caudal line, perpendicularly and transversally through the nasal dorsum 5 mm caudal to the end of the nasal bones. The specimens were detached using a chisel and scissors and stored in 10% formalin solution. Next, a gypsum mass model of the original skull defect was made to allow accurate positioning of the resected specimen. Subsequently, the specimens were decalcified using an equal part solution of 20% sodium citrate and 85% formic acid for 6 weeks. Then, macroscopic examination was performed and measurements of:

- (1) Cephalic width of nasal bones
- (2) Lateral length of nasal bones
- (3) Medial length of nasal bones
- (4) Caudal width of nasal bones
- (5) Angulation of nasal bones on profile including NA, DPA, and KA
- (6) Width of nasal bones at the nasofrontal suture
- (7) Width of nasal bones at the DPA
- (8) Width of nasal bones at the KA
- (9) Distance of DPA from N
- (10) Distance of KA from R

To obtain precise measurements of the curved nasal bones, a tin wire, 0.5 mm in diameter, was employed because of its specific flexibility. Measurements were performed using the Vernier scale. Angles were determined using an angle meter on the enlarged photographs of the nasal bone profile.

RESULTS

Cadaver dissections were performed on 22 Caucasian females and 22 Caucasian males, age 18 to 55 years old

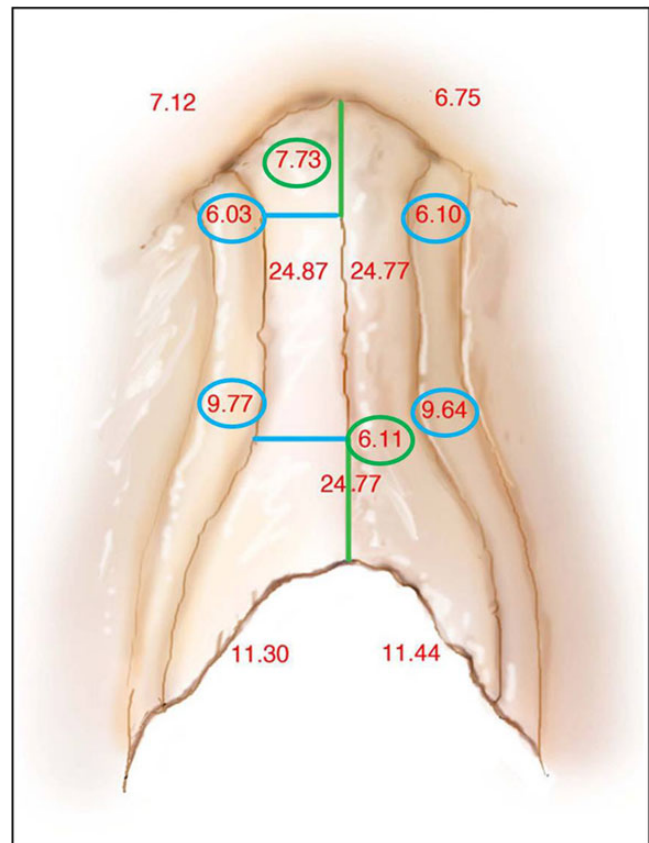


Figure 7. Average distances measured (shown in mm) are illustrated for the nasal bones. The anthropometric N to S as well as K to R are shown with the green lines. The distance S and K to the nasomaxillary junction are shown with blue lines.

Table 1. Measured Values for Nasal Bones Angulations

Specimens	NA°	DPA°	KA°
Male (n = 22)			
Mean	140.41°	155.29°	203.58°
SD	5.73°	3.79°	3.17°
Range	129-143°	145-157°	192-222°
Female (n = 22)			
Mean	142.35°	151.85°	199.95°
SD	4.34°	7.81°	8.51°
Range	124-149°	143-162°	189-207°
Total (n = 44)			
Mean	141.38°	153.57°	201.77°
SD	5.03°	5.81°	5.84°
Range	124-149°	143-162°	189-222°

SD, standard deviation.

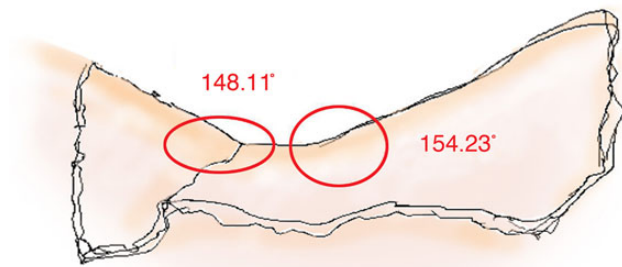


Figure 8. “V - shaped” nasal bones - values of nasion angle and dorsal profile angle in females.

(average age 59). The average anatomic measurements are illustrated in Figure 7. Although the nasal bones have an irregular variable shape, three distinct angles were found and measured along the dorsal profile line beginning with the nasion angle (NA), the dorsal profile angulation (DPA), and the kyphion angulation (KA) (see Table 1). The NA averaged ♀148.11° and ♂146.22°. The DPA averaged ♀154.23° and ♂151.78°. In 12% of cases, the caudal portion of the nasal bones was straight and without angulation, which resulted in a V-shape configuration (see Figure 8). In 88% of cases, the caudal portion of the bone was angulated that resulted in an S-shape configuration (see Figure 9). The most prominent convexity within the bony dorsum occurred at K, and KA located on top of the bony dorsum curvature averaged ♀199.95° and ♂203.58°. The values of NA, DPA, and KA were not significantly different between the sexes (see Figure 10).

DISCUSSION

Surgery of the nasal bones is crucial to successful rhinoplasty. Eliminating the hump on the profile and creating the cephalic portion of the post-reduction dorsal lines with osteotomies are critical to the post-operative result.⁹ It is the morphology of the radix, the bony vault, and the osseocartilaginous vault, with the overlying bony cap, that determines the shape of the pre-reduction nasal dorsum.³ In the sagittal plane, the nasal bones contain three important anthropometric nasal landmarks: N, S, and R, which in turn determine the nasofacial angle and profile. The importance of our anatomical observations and their potential relevance to rhinoplasty surgery will be discussed.

Anatomical Findings

Prior anatomic studies were limited to recording surface characteristics of the nasal bones. In contrast, the present study emphasizes the profile angulations of the nasal bones from the skull to the caudal portion of the osseocartilaginous vault, which provides a better understanding of the

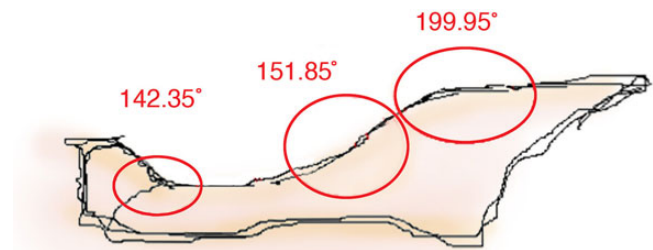


Figure 9. “S - shaped” nasal bones - values of nasion, dorsal profile, and kyphion angles in females.

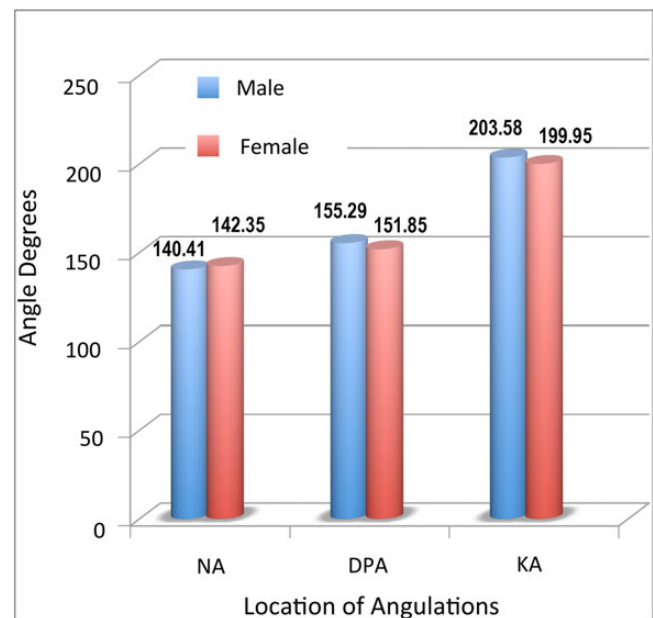


Figure 10. Angulations of nasal bones by gender.

complete nasal profile. The anthropometric N occurs at the midpoint of the nasofrontal suture line and S is the deepest depression of the nasal bones. The intervening cephalic bone, N-S, represents the radix while the caudal bone, S-R, represents the true bony dorsum cephalically and the osseocartilaginous vault caudally. The true bony vault lies cephalad and separate from the osseocartilaginous vault.

The radix was found to be a slightly concave plane, 7.73 mm in length and 6.03 mm above the nasomaxillary junction. With the introduction of DPA and KA, clinicians can further analyze the dorsal hump with greater accuracy as to severity and type. On lateral photographs, the surgeon can mark K at the most prominent point on the bony nasal profile, and R as the most caudal midline point of the nasal bones, which occurs at the osseocartilaginous junction. Then, one can draw the following two angles: the DPA at the sellion and KA at the kyphion. These angles allow one to subdivide the dorsal bony hump into two types:

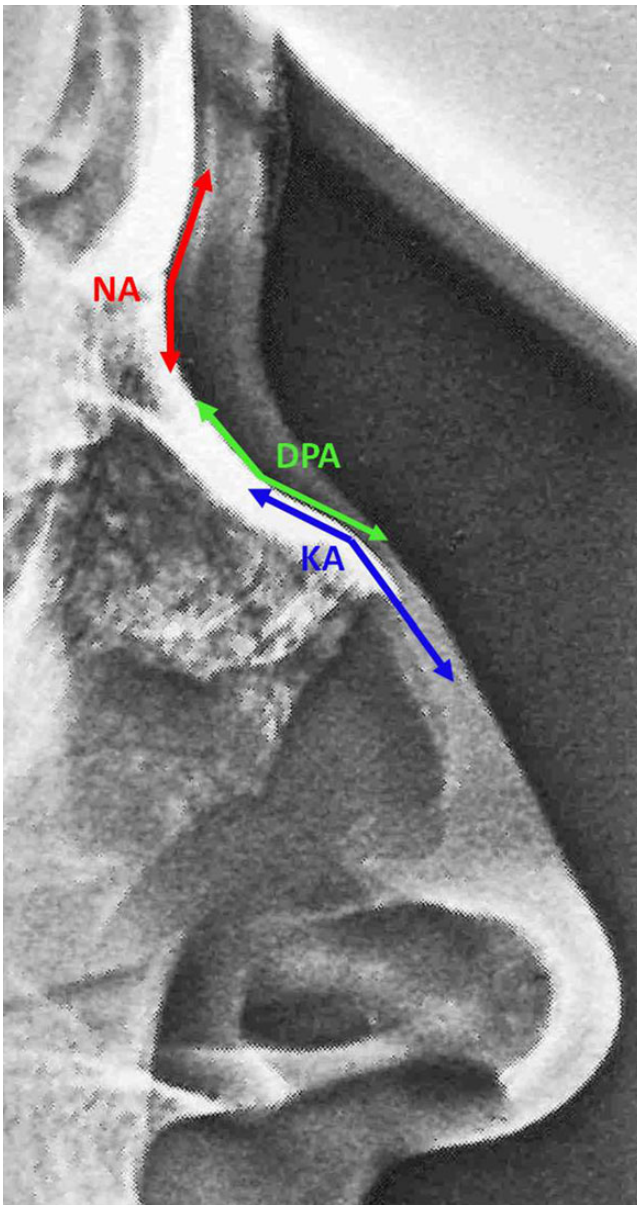


Figure 11. Nasal bones – pretreatment.

V-shaped and S-shaped. The V-shaped bones are relatively straight from S to R and do not have a distinct convex K. Despite the absence of a prominent dorsal convexity, a dorsal reduction may be done to reduce the overall size of the nose and to bring the dorsal profile line closer to the face. In contrast, S-shaped nasal bones have a distinct convexity at K, which is often the primary reason that a patient seeks a rhinoplasty.

Clinical Application

Although this is a study focused on the anatomy of the nasal bones, some clinical applications are worth mentioning. As

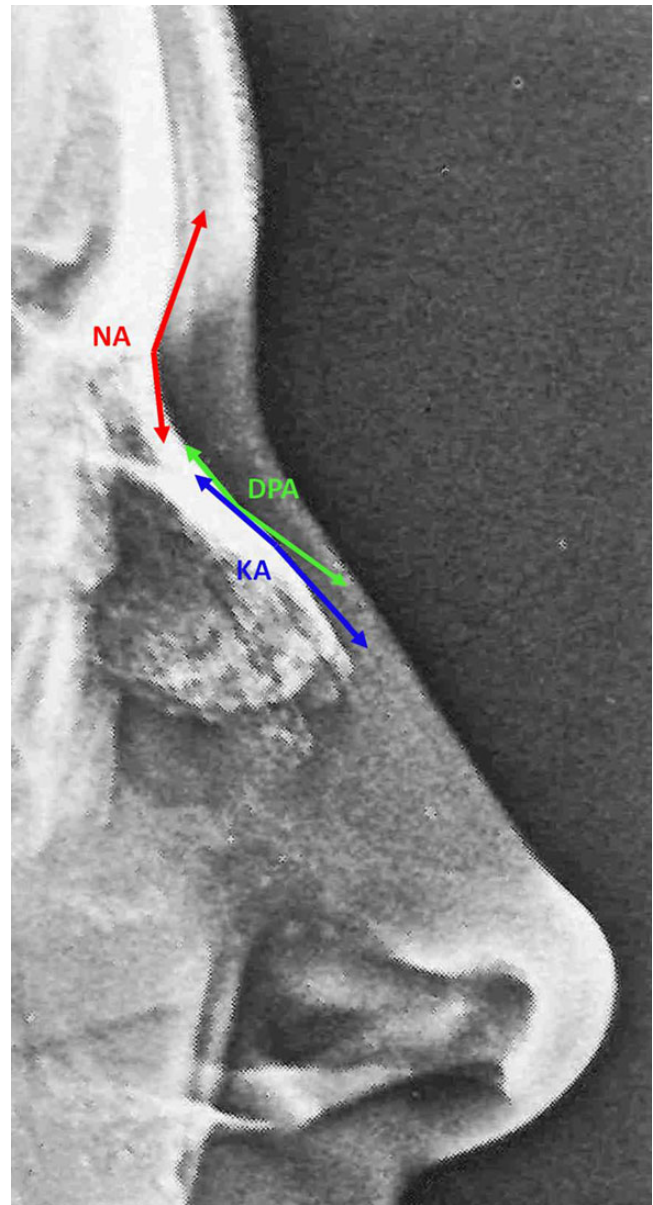


Figure 12. Nasal bones – postoperatively. Conversion of “S-shaped” nasal bones to “V-Shaped.”

previously mentioned, surgeons tend to transfer anthropometric terms indiscriminately from the bony surface to the skin surface for pretreatment planning. Obviously, this transfer requires certain assumptions that can lead to confusion and inaccuracies. Although purists object to this practice, the authors feel that the application of our anthropometric findings to pretreatment planning in rhinoplasty surgery is far more valuable than any potential conflict. The recognition that the cephalic portion of the nasal dorsum can be separated into radix, bony vault, and osseocartilaginous vault helps with pretreatment planning and analysis. Marking and measuring the different points and angles can help to point out whether the hump pathology lies in the radix, bony vault, or

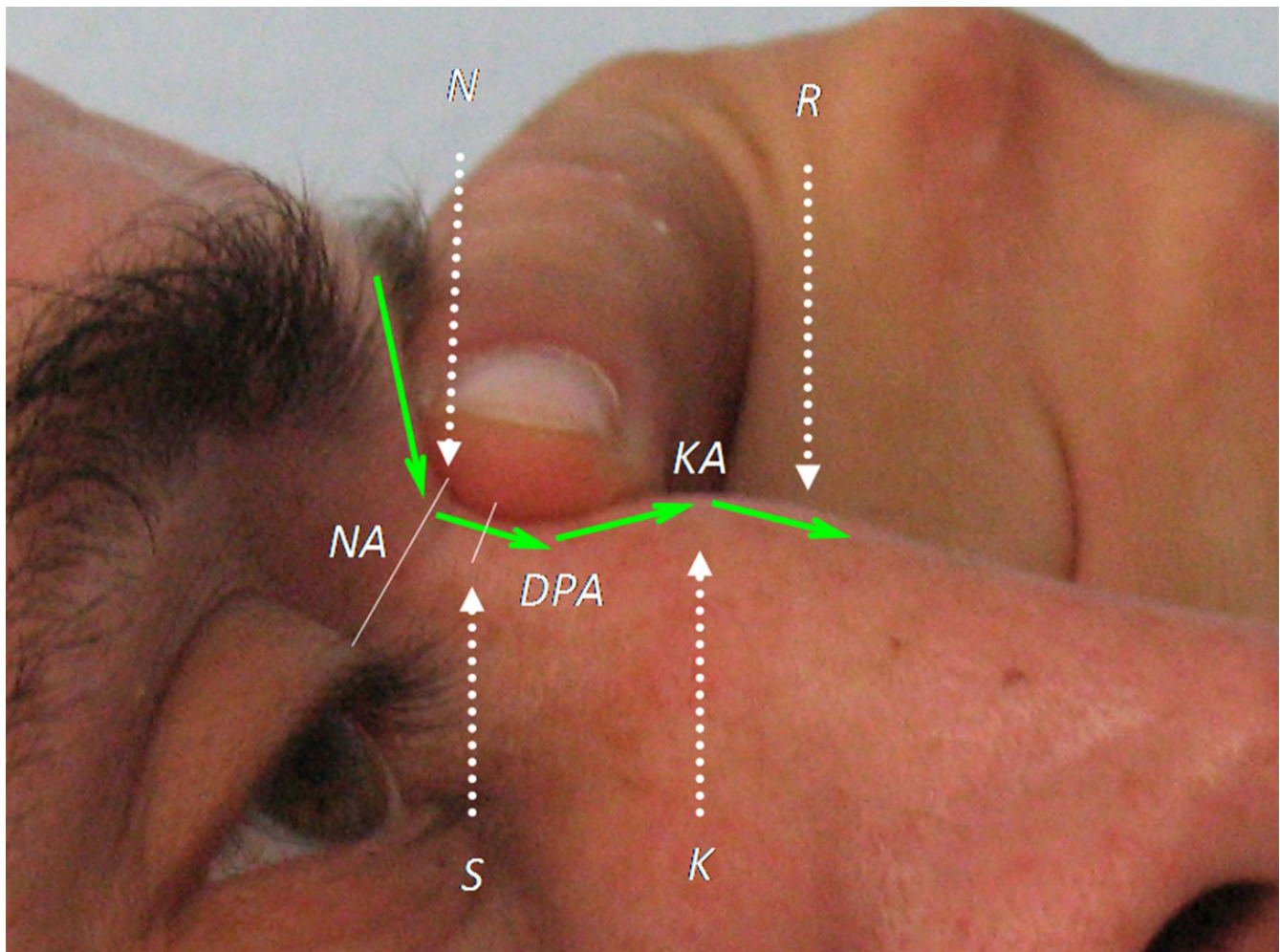


Figure 13. Approximate detection and marking of the nasal bones by palpation on a 47-year-old male subject.

osseocartilaginous vault. For example, for many patients a balanced rhinoplasty may involve osseocartilaginous reduction with radix grafting.¹⁰

The value of the anthropometric measurements is also demonstrated in analysis of pretreatment and postoperative radiographs. As shown in Figure 11, one can define the critical four points (N,S,K, and R) and then draw the essential three angles (NA, DPA, and KA). The presence of the dorsal convexity confirms that this patient has an S-shape bony configuration. Postoperatively, there is a significant change in the bony angulation following the dorsal reduction (see Figure 12). The soft tissue surface NFA is changed dramatically as the dorsal limb is reduced along with the tip over-projection. In contrast, the anthropometric nasion angle NA is not changed because there was no radix reduction. Both the DPA and the KA are increased significantly following the dorsal reduction. Perhaps more importantly, the K point virtually disappears and to a certain degree the S-shaped nasal bones have been converted to V-shape nasal bones. It should be noted that at times a slight hump (K) might be left to create a straight dorsal profile. This is

due to variable thickness in the nasal dorsal skin with thinner skin located in the rhinion.

Study Limitations

This anatomical study identifies anthropometric points, and angles are then measured based on these landmarks. From a surgical planning standpoint, these landmarks can be hard to delineate and localize without using radiography (see Figure 13). Knowing the normal values of these angles of the nasal bones does not in and of itself help a clinician decide whether to remove a hump or how much to remove. In addition, differences in skin thickness and soft tissue may alter the way in which a hump is removed. For example, if radix reduction is necessary, some patients may benefit from reduction with a burr while others may benefit from procerus/soft tissue reduction. However, using the nasal angles does help separate the nasal bones and hump profile into radix, bony hump, and osseocartilaginous vault. By breaking down the hump profile each

segment can be analyzed with the requisite reduction or augmentation.

We also must address that the cephalic portion of the nose (radix to osseocartilaginous junction) must be analyzed independently but also in relation to the complete nasal profile. Tip projection must be taken into account to harmonize the nasal tip and nasal dorsum. In fact, some patients may benefit from dorsal augmentation to balance nasal tip projection.¹¹

CONCLUSION

This anatomical study identifies and measures three important anthropometric angles of the nasal bones. These angles help surgeons to better understand the pre-reduction nasal profile as well as where the pathology lies when creating the ideal nasal dorsum.

Disclosures

Dr Daniel receives royalties from Springer Publishing. Dr Kosins is a consultant for ZO Skin Health, Inc. None of the other authors have any disclosures.

Funding

The authors received no financial support for the research, authorship, and publication of this article.

REFERENCES

1. Farkas LG, Kolar JC, Munro IR. Geography of the nose : A morphometric study. *Aesthetic Plast Surg.* 1986;10:191-223.
2. Guyuron B. Precision Rhinoplasty. Part II: Prediction. *Plast Reconstr Surg.* 1988;81:500-505.
3. Oneal RM, Bell RJ Jr, Izenberg PH, Schlesinger J. Surgical Anatomy of the Nose. *Operative Techniques in Plastic and Reconstructive Surgery.* 2000;7:158-167.
4. Anderson KJ, Hennenberg M, Norris NM. Anatomy of the nasal profile. *J Anat.* 2008;213:210-216.
5. Daniel RK. *Aesthetic Plastic Surgery: Rhinoplasty.* 1st ed. Boston, MA: Little, Brown and Company; 1993: 151-215.
6. Mowlavi A, Meldrum DG, Wilhelm BJ. Implications for Nasal Recontouring: Nasion Position Preferences as Determined by a Survey of White North Americans. *Aesthetic Plast Surg.* 2004;27:438-445.
7. Aiach G, Laxenaire A, Vendroux J. Deepening the nasofrontal angle. *Aesthetic Plast Surg.* 2002;26 (SUPPL. 1):S5.
8. Tezel E, Durmus FN. A new instrument for achieving a natural nasofrontal angle. *J Plast Reconstr Aesthet Surg.* 2009;62:617-619.
9. Palhazi P, Daniel RK, Kosins AM. The osseocartilaginous vault of the nose: Anatomy and surgical observations. *Aesthet Surg J.* 2015;35(3):242-251.
10. Daniel RK. *Rhinoplasty: An Atlas of Surgical Techniques.* Singapore: Springer, 2002.
11. Daniel RK, Calvert JW. Diced cartilage grafts in rhinoplasty surgery. *Plast Reconstr Surg.* 2004;7:2156-2171.



The Help You Need
Is Finally
Here.

**SMART
BEAUTY
GUIDE**

BROUGHT TO YOU BY
THE AMERICAN SOCIETY FOR
AESTHETIC PLASTIC SURGERY

Prospects for Your Practice
Products Patients Want
Content You Trust

www.smartbeautyguide.com

American Society for Aesthetic Plastic Surgery
11262 Monarch St., Garden Grove, CA 92841-1441
800.364.2147 • 562.799.2356