



Graft stability after endothelial keratoplasty

Stabilnost kalema rožnjače posle endotelne keratoplastike

Vesna Jovanović, Ljubiša Nikolić

Department of Ophthalmology, Faculty of Dental Medicine, University of Belgrade,
Belgrade, Serbia

Abstract

Background/Aim. Techniques for replacing the corneal endothelium have been improved. The host-graft interface is the key to graft adhesion and visual recovery. The aim of this study was to establish graft stability after Descemet stripping with endothelial keratoplasty (DSEK), compare it to the graft stability after endothelial keratoplasty with the intact posterior corneal layers (nDSEK) in the rabbit cornea, and to investigate the nature of wound healing. **Methods.** Adult white rabbits (n = 20) were divided in two experimental groups: ten rabbits underwent monocular DSEK, and ten rabbits underwent endothelial keratoplasty without Descemet stripping (nDSEK). On the second postoperative day a horizontal dislocation of the graft was tried using the Lindstrom roller in each animal. Corneas were processed for the light microscopy study. **Results.** Rolling the Lindstrom instrument over the corneal surface did not cause horizontal dislocation in any of the operated eyes. In the DSEK group light microscopy revealed the lack of inflammation and fibrosis at the clearly distinctive donor-recipient interface (DRI). Retrocorneal membrane was found in two eyes. In nDSEK group, the host Descemet's membrane (DM) was intact without endothelial cells, with good graft apposition, without inflammation, fibrosis, or retrocorneal membrane. **Conclusion.** This study suggests that there is no difference in graft stability in DSEK compared to nDSEK in rabbit corneas. Wounds healed at DRI by hypocellular scarring only in both experimental groups.

Key words:

cornea; rabbits; ophthalmologic surgical procedures; transplantation; graft survival; histological techniques.

Apstrakt

Uvod/Cilj. Tehnike zamene kornealnog endotela se unapređuju. Ključ za adheziju grafta i oporavak vida je interfejs domaćina prema kalemu. Cilj rada bio je da se utvrdi stabilnost kalema rožnjače kod endotelne keratoplastike sa svlačenjem (DSEK) i uporedi sa stabilnošću kalema kod endotelne keratoplastike sa intaktnom zadnjom površinom (nDSEK) na zečijoj rožnjači, kao i da se ispita način zarastanja operativne rane. **Metode.** Eksperiment je izveden na kunićima soja činčile (n = 20), podeljenim u dve eksperimentalne grupe. U prvoj grupi (deset očiju) urađen je DSEK, a u drugoj (deset očiju) endotelna keratoplastika bez ljuštenja endotela. Drugog postoperativnog dana kod svih kunića izvršen je pokušaj horizontalne dislokacije kalema pomoću Lindstromovog rolera. Rožnjače su pripremljene za svetlosnu mikroskopiju. **Rezultati.** Pomeranjem Lindstromovog rolera preko površine rožnjače nije bilo moguće dislocirati nijedan kalem. U DSEK grupi, na svetlosnoj mikroskopiji nije bilo zapaljenja, niti fibroze na spoju strome primaoca i donatora (DRI), ali je DRI bio histološki uočljiv. Takođe, uočena je i retrokornealna membrana u dva oka. U grupi podvrgnutoj endotelnoj keratoplastici bez svlačenja Descemetove membrane (DM), DM primaoca je bila intaktna, bez endotelnih ćelija, sa dobrom apozicijom kalema, bez zapaljenja ili fibroze, a retrokornealna membrana nije uočena. **Zaključak.** Ova studija pokazuje da nema razlike u stabilnosti kalema kod DSEK, u poređenju sa stabilnošću kalema kod nDSEK i na zečijim rožnjačama. Zarastanje rane kod oba postupka odvija se stvaranjem hipocelularnog ožiljka u obe eksperimentalne grupe.

Ključne reči:

rožnjača; zečevi; hirurgija, oftalmološka, procedure; transplantacija; graft, preživljavanje; histološke tehnike.

Introduction

In the quest for better understanding of human corneal wound healing in the blooming era of refractive and lamellar keratoplasty procedures, animal model offered a valuable insight^{1–10}. Although the rabbit cornea has some differ-

ences compared to the human, such as the lack of Bowman layer, abundant regenerative capacity of endothelial cells, and overall thinner cornea, the similarity of stromal corneal lamellar architecture, and keratocyte distribution, as well as the response to different agents, served as a good model for decades^{4, 11–15}.

For more than 100 years, the only surgical technique to replace the diseased endothelium has been full-thickness penetrating keratoplasty (PK). Although useful vision could be achieved after PK, this procedure suffers from a wide range of complications. Graft failure is not uncommon and it accounts for up to 40% of all corneal transplants^{16, 17}. Moreover, regrafts have higher failure rates than the first time PK, so an alternative would be desirable¹⁸.

Since 1998, the technique for posterior lamellar keratoplasty (PLK) has evolved, maintaining the concept of replacing the corneal endothelium with an unsutured posterior lamellar graft through a small limbal incision in eyes that have not been previously grafted. The most commonly used modification of PLK is Descemet stripping with endothelial keratoplasty (DSEK). DSEK involves stripping of Descemet's membrane (DM) from the host cornea and placement of a donor graft, comprising a thin layer of the posterior stroma, DM and endothelium, onto the posterior surface of the host stroma. PLK may be better option than regrafting previously failed PKs, particularly when rapid visual recovery is important and an acceptable refractive outcome was achieved with the first time graft. It seems that in some cases stripping of DM is not necessary, but published data are limited and long term results are not known.

The host-graft interface is the key to graft adhesion and visual recovery. We compared PLK graft stability with and without DM stripping in a rabbit cornea and investigated the nature of wound healing by light microscopy.

Methods

Study design

A total of 20 white rabbits (weight 3–4 kg) with normal corneas were divided in two experimental groups: in the first group animals underwent monocular DSEK, and in the second one monocular PLK without DM removal. On the second postoperative day, a Lindstrom roller was used to try to dislocate graft horizontally in each animal, and after 7, 30 and 90 days corneas were harvested and evaluated using light microscopy. The rabbits were anaesthetised with an intramuscular injection of xylazine (5 mg/kg), and ketamine hydrochloride (35 mg/kg), and topically with tetracaine hydrochloride. The animals were heparinized (2 mL, 5,000 IU intravenously) immediately before surgery to prevent clotting of the aqueous humour. Postoperative treatment included topical 0.1% dexamethasone-neomycin four times *per day*, and 1% chloramphenicol ointment once. At the selected time points animals were killed by overdosing sodium pentobarbital (100 mg/kg), and the corneas were processed for histology (hematoxyline and eosin staining). Experiments were approved by "Zvezdara" University Medical Center Ethical Board, and all animals were housed and treated to Association for Research in Vision and Ophthalmology (ARVO) statement for the use of animals in ophthalmic and visual research.

Surgical procedure

Donor

The donor cornea was prepared first, followed by the surgery of the recipient. Using the whole globe a 4 mm peripheral corneal incision was made with the perpendicular edge of a blade at approximately 2/3 stromal depth. From the bottom of the incision, a manual stromal dissection was made. Once the dissection was completed, the corneoscleral button was cut, transferred to a punching block, endothelial side up and cut with a 5 mm punch trephine. The button was placed on a spatula, endothelial side up, and covered with viscoelastic substance.

Recipients

The DSEK group: The recipient corneal epithelium was lightly marked with 5 mm trephine, to outline the area for Descemet stripping and placement of donor tissue. A 1.5 mm corneal incision was made 4 mm away from limbal area, and the anterior chamber was filled with air. A bent, 21 G needle was used to score DM in a circular pattern under the area of the epithelial reference mark. Reversed Sinsky hook was used to strip off DM and endothelium within the scored area and to remove it from the anterior chamber. The anterior chamber was filled with air. The initial corneal incision was lengthened to 5 mm, and the previously prepared donor graft was inserted into the anterior chamber laying on a spatula with stromal side up, and endothelial side protected with viscoelastic. Air was injected into the anterior chamber to press it up against the recipient cornea. The peripheral corneal incision was closed with 10–0 monofilament nylon suture. Air was left in place for two hours, and then partially replaced with balanced salt solution (BSS).

The nDSEK group: The procedure was the same as described above, except for leaving the recipient DM intact.

Results

Rolling the Lindstrom instrument over the corneal surface on the second postoperative day did not cause horizontal dislocation in any of the operated eyes.

The DSEK group

Seven days after DSEK

Tissue obtained on the day 7 after DSEK and stained with haematoxylin and eosine (HE) revealed that donor-recipient interface (DRI) could be determined, but was not conspicuous. Stromal collagen lamellae both of the recipient and donor were parallel, but with greater interlamellar space and with less keratocytes on the donor side. DM end the endothelium of the graft appeared unchanged.

Thirty days after DSEK

Thirty days after DSEK, DRI were still inconspicuous. In one specimen there was a deposit of amorphous material at DRI (Figure 1). Stromal collagen lamellae remained parallel, but with greater intralaminar space and less keratocytes in the donor graft. DM end endothelium appeared normal.

Ninety days after DSEK

HE staining revealed DRI still without scarring, with

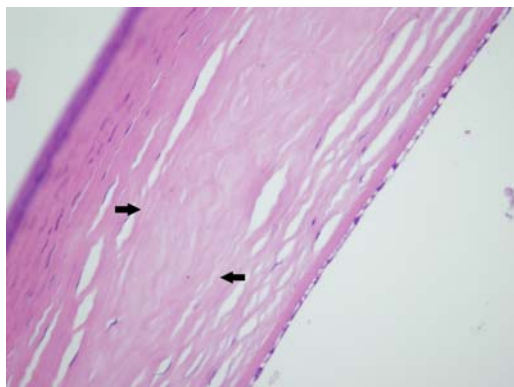


Fig. 1 – Light microscopy after Descemet stripping with endothelial keratoplasty (DSEK) from the peripheral part of the cornea (HE, ×20). Arrows indicate the interface between host and a donor stroma.

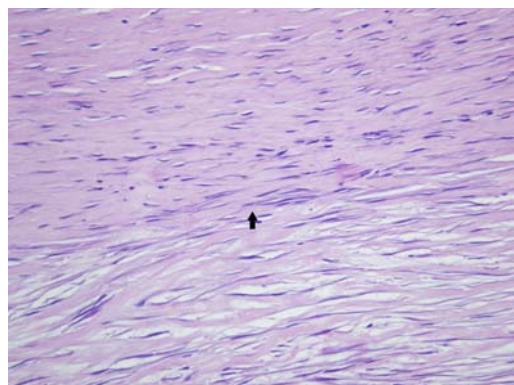


Fig. 3 – Light microscopy one month after Descemet stripping with endothelial keratoplasty (DSEK) showing amorphous material at donor-recipient interface (HE, ×40).

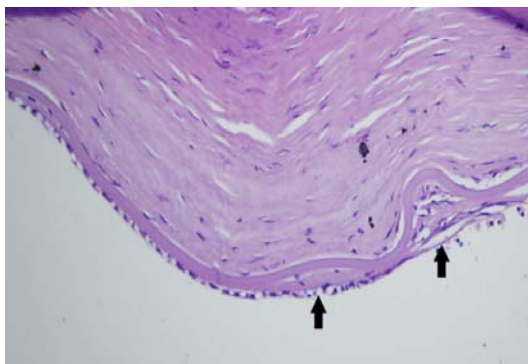


Fig. 5 – Light microscopy 3 months after Descemet stripping with endothelial keratoplasty (DSEK) showing thin delicate retrocorneal membrane (arrow) (HE, ×20).

parallel lamellae and evenly distributed keratocytes. In two specimens retrocorneal membrane was visible (Figures 2–5).

The nDSEK group

On days 7, 30 and 90 after surgery, histology revealed similar findings in all specimens. Recipient endothelium was absent, and DM retained normal appearance. Stromal collagen lamellae were parallel with the uniform distribution of keratocytes, both on recipient and donor side. Donor DM and endothelial cells were normal. Histology revealed good graft apposition (Figure 6).

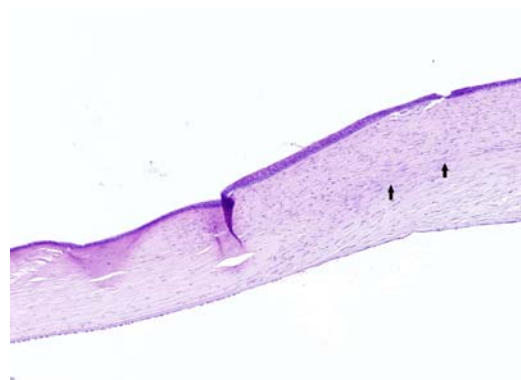


Fig. 2 – Light microscopy 2 months after Descemet stripping with endothelial keratoplasty (DSEK) at a higher magnification (HE, ×40): donor-recipient interface with hypocellular scarring (arrows).

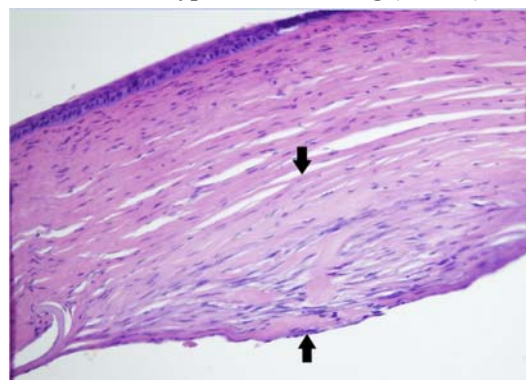


Fig. 4 – Light microscopy 3 months after Descemet stripping with endothelial keratoplasty (DSEK) showing globular retrocorneal membrane between arrows (HE, ×20).

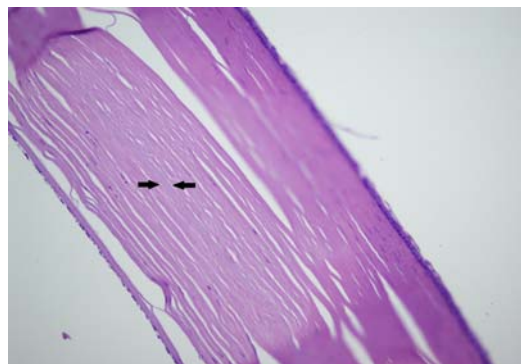


Fig. 6 – Light microscopy 3 months after posterior lamellar keratoplasty without Descemet's membrane (DM) removal, showing the absence of host endothelial cells, firm attachment of host DM to both host and donor stroma, and normal HE staining (arrows) (HE, ×20).

Discussion

The anatomy of the rabbit eye makes endothelial keratoplasty much more challenging compared to human. First, the peripheral convexity of the iris in the rabbit eye, makes an incision near the limbus impossible, as both the iris and the lens would be damaged. Therefore the incision had to be placed 4 mm away from the limbus in the clear cornea, where the anterior chamber is deeper, and allows more space for surgical manipulation. Second, the rabbit cornea is overall thinner than human (300 μm compared to 550 μm) which made the endothelial transplant extremely thin and fragile, with a tendency to twist inwards. As manipulation should be minimal, it was of utmost importance to be careful about the orientation of the stromal and endothelial side, in order to avoid the wrong orientation during insertion into the anterior chamber. Third, the aqueous humour in rabbits has strong tendency to clot during intraocular surgery, and seriously compromise its outcome. In order to prevent this the animals in both groups were heparinized immediately before the surgery. Besides, abundant regenerative capacity of corneal endothelial cells in rabbits limits the evaluation of viability of the endothelium in the late postoperative period¹⁹.

Our study demonstrates that there is no difference in the graft stability with and without DM removal. The study also suggests that in both experimental groups wounds heal by hypocellular scar only. The retrocorneal membrane formation was observed only in the DSEK group.

Our results were obtained after endothelial keratoplasty in healthy eyes, without intra- or postoperative complications, which could be compared only to failed human grafts.

Light microscopy in our DSEK group, showed a firm attachment between the posterior donor and anterior host stromal tissue, lack of inflammation and fibrosis at DRI, and a barely perceptible DRI. Amorphous material found at DRI in one specimen could be related to collagen fibers rupture during DM stripping, which is more difficult to perform in a healthy rabbit cornea than in eyes with underlying endothelial pathologic abnormalities²⁰.

Caldwell et al.²¹ analysed 10 failed grafts, with the DRI being mostly indistinctive, although in some specimens focal hypercellularity was visible in the areas of separation between the graft and the anterior stroma. The author assigned this to a proliferative response to the loss of apposition to DM or stroma. Contrary to this, in eyes enucleated 7 days after the surgery, we found a good apposition and hypocellularity near the DRI. It has been shown earlier, that lamellar cut across the cornea produced by microkeratome, as performed during laser-assisted *in situ* keratomileusis (LASIK), induces keratocyte apoptosis, not only peripherally at the site of epithelial injury, as would be expected, but also along both sides of the lamellar interface. The proposed mechanism is the diffusion of cytokines from the injured peripheral epithelium along the lamellar interface¹⁰.

Several studies showed the presence of fibrocellular tissue at the DRI^{22, 23}. Shulman et al.²² showed that half of the failed grafts with interface fibrosis was associated with chronic stromal inflammation. The authors presumed that increa-

sed intraocular manipulation might have contributed to the inflammatory response, which further led to stromal fibroblast activation by inflammatory mediators. In our study we did not notice either inflammatory cells, or fibrocellular scar. Contrary to the surgical procedure used in published studies where graft was folded, grasped (and eventually partially crushed) with forceps, and pulled through a very tight incision, we used the previously described technique where the graft was unfolded, flat, positioned on the spatula, endothelial side down, with the viscoelastic protection, and introduced into the anterior chamber-which did not cause any compression to the graft. As previously mentioned, manipulation of a very thin graft is extremely difficult, so we decided to use the technique where the graft could be minimally damaged.

We did not find any epithelial cells at the DRI, which is consistent with the early Melles' et al.⁶ report. However, there are several reports on epithelial ingrowth and the presence of epithelial membrane at DRI²²⁻²⁴. In report by Bansal et al.²⁴ epithelial ingrowth was continuous with the stromal puncture incision for interface fluid removal, while in a Shulmans et al.²² report there was an eccentric lenticule trephination, which resulted in the retention of a full-thickness donor cornea and its epithelium at one edge of the graft. We did not perform corneal incision for interface fluid removal. Opposite to microkeratome dissected tissue which could result in eccentric trephination, we prepared the graft by manual dissection, so that none of the epithelial cells could have access to the DRI.

In the DSEK group, DM was adherent in all but two cases, which we believe that this detachment is attributable to shearing stress from tissue cutting. Endothelium was preserved in all specimens.

The most frequent reason for endothelial keratoplasty graft failure is endothelial atrophy often preceded by its damaging during graft preparation and manipulation during implantation into the anterior chamber^{25, 26}. Using the air bubble at the end of the surgery, to keep the donor disc in its position, potentially could harm the endothelium in the early postoperative period^{11, 27}. The chronic endothelial cell loss may include slow migration of the central endothelium to the periphery, apoptosis and a slow, subclinical, immune-mediated destruction of the donor endothelium by the recipient. The use of the donor tissue that has been pre-cut with a microkeratome or femtosecond laser by the eye bank and then shipped to the surgeon are becoming the popular way of performing endothelial keratoplasty throughout the world, although the long term effect on the donor endothelial cell counts is unknown²⁸.

In our experimental model, endothelium could not be evaluated, because of the immense regenerative capacity of the rabbit endothelium. Furthermore, we used grafts prepared from the fresh, whole globes with highly viable endothelial cells.

In the two of our DSEK cases, retrocorneal membrane was present after a 90-day follow-up.

In ten failed grafts Caldwell et al.²¹ found 4 retrocorneal membranes, two of which were thin, and two other were prominent and localized at the graft edges. Shulman et al.²² found retrocorneal membrane in one third of the 22 failed

grafts, while Sbarbaro et al.²⁹ described two membranes in three failed grafts. Similar to retrocorneal fibrous membrane in failed PK grafts, retrocorneal fibrous membrane in failed DSEKs can result from fibrous ingrowth or from fibrous metaplasia of endothelial cells. It is well-documented that disruption and separation of DM can provide the trigger for emanating stromal tissue from the wound edge³⁰. While not necessarily contributing to graft failure, if it is limited to the edge of the graft, the retrocorneal membranes could lead to graft decompensation, if it is large and diffuse, as in the case of a large wound, or poor host and the graft DM alignment as in PKP or DSEK³¹. Clinically, the cornea appears cloudy and oedematous. Since the regenerative capacity of rabbit endothelial cells is large, we could expect more aggressive response to the poor alignment of graft. In one case we noticed a mature, globular retrocorneal membrane, at the edge of the graft which did not compromise the optical clarity. In the second specimen, the membrane was thin, and delicate so did not cause significant corneal edema.

One of the major concerns regarding endothelial keratoplasty is graft dislocation, which is very often followed by graft decompensation. It is now well-known that mastering the technique leads to lower percentage of dislocation. At the dawn of this technique the reported rate of dislocation was even 50%^{25,26}. Today, it is less than 1–2%²⁸. It was presumed that thinner grafts were associated with a higher rate of early donor failure^{26,32}. Preliminary results of the transplantation of a bare DM without stromal carrier, show that the graft thickness does not play the major role in dislocation³³. Melles³³ states that donor dislocation rarely happens when fresh tissue is used, which may suggest that eye banks preservation process affects the endothelial pump function. He also presumes that the most important surgical factor which prevents graft attachment is the use of hyaluronic acid (dextran in tissue storage media also has similar viscous feature).

The mechanism of graft adhesion is still unknown. The proposed mechanism by which a graft remains attached to the host stroma is wound compression by imbibition swelling of the exposed, posterior edges of both the donor and the recipient, stickiness of the stromal tissue at DRI, the suction force of the donor endothelium and fibrin deposition throughout the wound area in the early healing phase³⁴. It has already been shown that fibronectin appears at the site of corneal stromal wound in rabbits shortly after wounding, and in case of lamellar keratoplasty, fibronectin has been detected at the interface of the graft and the recipient cornea^{1,9}. Stromal remodelling is supposed to be the mechanism of wound healing in later phases.

Rolling the Lindstrom instrument over the surface of the cornea on the second postoperative day, did not cause any graft dislocation. It seems that the proposed mechanisms for early graft adhesion were efficient enough to hold the graft in apposition in early postoperative period. If fibrotic wound repair was the only mechanism to hold the graft in place, it would be possible to dislocate the graft for a much longer postoperative period.

The hypocellular primitive scar lacks collagen fibrils as previously shown on post LASIK corneas⁷. The experiment

with rabbit corneas showed that in weeks after lamellar surgery, regions of healing stromal matrix were structurally disorganised, and contain collagen-free areas populated by abnormally large sulphated proteoglycan filaments, which might aid tissue restructuring because of their water-binding capacity⁸.

There was no graft dislocation in the DSEK group. The possible explanation could be that we used fresh, unfolded tissue. Our grafts were manually prepared which could increase the stickiness of the lamellar stromal surfaces.

Light microscopy in the nDSEK group showed firm host DM attachment to both host and donor stroma and the disappearance of the host endothelial cells. There was no inflammation or retrocorneal membrane formation. In the previous reports on lamellar keratoplasty using full thickness donor material in rabbit eyes, it was shown that donor endothelial cells start to disappear 30 minutes after the surgery, and that disappearance is completed by 24 hours. There were very few inflammatory cells in the neighbouring recipient cornea. The DM remained intact. Our finding goes in line with the previous reports. There were no host endothelial cells, and no inflammatory response. DM remained intact, and showed normal staining for HE³⁵.

Although first descriptions of failed and detached grafts implicated that the retention of DM at DRI may weaken graft adhesion and cause primary graft failure²³, in eight histologic sections of failed grafts Caldwell et al.²¹ show that the presence of DM does not hinder graft adhesion. Furthermore, it appeared that there was an increased adhesion in the areas of residual DM. In two of the cases residual host DM was more adherent to DSEK graft than to the anterior host cornea. There was no alteration in cellularity or inflammation in the areas of residual DM. From that Caldwell et al.²¹ suggested that removal of DM might not be necessary.

Sbarbaro et al.²⁹ described histology of 3 failed endothelial keratoplasty grafts. In two grafts there was a delicate fibrous retrocorneal membrane, and the authors suggested that it could be a possible reason for endothelial keratoplasty failure. They also found a firm adhesion of residual host DM to the donor stroma and concluded that removing optically clear DM may not be necessary.

Price and Price³⁶ described initial series of endothelial keratoplasty without DM removal. They treated 5 eyes with failed PKs for endothelial decompensation after previously having clear corneal transplant. In all cases the graft adhered to and cleared the edema from the previous penetrating graft. Within the next 3 months of endothelial keratoplasty visual acuity (VA) had improved as well³⁶.

We recently showed histological and ultrastructural finding of endothelial keratoplasty without DM removal in a failed PK graft a year after the surgery. Light microscopy showed the absence of host endothelium, and good graft apposition. Electron microscopy revealed quiet keratocytes without prominent endoplasmic reticulum. Host DM had the normal homogenous structure, without scar formation on either of its sides³⁷.

A recently performed study on a similar experimental model showed clear corneas and good graft apposition after both

DS/EK and non-Descemet stripping automated endothelial keratoplasty (nDSAEK). Analysing the fate of endothelial cells two weeks after the surgery, the authors expressed concerns regarding long-term graft adherence in nDSAEK cases³⁸. In our study the follow up was much longer (12 weeks), and there was a good graft adherence throughout the observation period.

Clinical evaluation of nDSEK in selected cases showed very favourable outcome. Park and Chuck³⁹ reported a case of non-Descemet stripping Descemet membrane endothelial keratoplasty (nDMEK) in one patient with pseudophakic bullous keratopathy. During a 6-month follow-up a graft remained attached and corneal edema subsided, which resulted in a remarkable visual acuity improvement³⁹. Masaki et al.⁴⁰ reported a good clinical outcome of 19 nDSAEK for non-Fuchs-type bullous keratopathy. All corneas remained clear after one year of follow-up⁴⁰. Similar results had Chaurasia et al.⁴¹ in their series of 23 patients with the mean follow up of 7.4 months. Based on their favorable results regarding corneal clarity, visual acuity and no interface haze, the authors suggested non-DSAEK as safe option in cases of corneal decompensation when the Descemet membrane is healthy.

Leaving the intact DM from the failed penetrating grafts seems to offer some advantages. Scraping DM from the graft could be difficult and incomplete which may provoke stromal overgrowth and the formation of a retrocorneal membrane²⁰. Furthermore, DM is a storage depot for bound basic fibroblast growth factor, and a mechanical injury to this membrane could convert it into a reservoir for the sustained release of mitogenic activity that may overcome rapid degradation of this factor⁴².

Conclusion

In conclusion, our study showed that both removing or leaving Descemet's membrane does not destabilize the endothelial keratoplasty graft in the early postoperative period. Removing the Descemet membrane could initialize formation of retrocorneal membrane which could lead to the late graft decompensation, while leaving the Descemet membrane intact reduces such risk. Furthermore, leaving the optically clear Descemet membrane could increase the chance for a long-term graft survival.

R E F E R E N C E S

1. *Fujikawa LS, Foster CS, Harrist TJ, Lanigan JM, Colvin RB.* Fibronectin in healing rabbit corneal wounds. *Lab Invest* 1981; 45(2): 120–9.
2. *Ivarsen A, Laurberg T, Moller-Pedersen T.* Characterisation of corneal fibrotic wound repair at the LASIK flap margin. *Br J Ophthalmol* 2003; 87(10): 1272–8.
3. *Kato T, Nakayasu K, Hosoda Y, Watanabe Y, Kanai A.* Corneal wound healing following laser in situ keratomileusis (LASIK): a histopathological study in rabbits. *Br J Ophthalmol* 1999; 83(11): 1302–5.
4. *Kim EK, Cristol SM, Geroski DH, McCarey BE, Edelhauser HF.* Corneal endothelial damage by air bubbles during phacoemulsification. *Arch Ophthalmol* 1997; 115(1): 81–8.
5. *Laurent JM, Schallhorn SC, Spigelnir JR, Tanzer DJ.* Stability of the laser in situ keratomileusis corneal flap in rabbit eyes. *J Cataract Refract Surg* 2006; 32(6): 1046–51.
6. *Melles GR, Binder PS, Beekhuis WH, Wijdh RH, Moore MN, Anderson JA, et al.* Scar tissue orientation in unsutured and sutured corneal wound healing. *Br J Ophthalmol* 1995; 79(8): 760–5.
7. *Miyamoto T, Saika S, Yamanaka A, Kawashima Y, Suzuki Y, Ohnishi Y.* Wound healing in rabbit corneas after photorefractive keratectomy and laser in situ keratomileusis. *J Cat Ref Surg* 2003; 29(1): 153–8.
8. *Quantock AJ, Padroni S, Connon CJ, Milne G, Schanzlin DJ.* Proteoglycan alterations in the rabbit corneal stroma after a lamellar incision. *J Cat Ref Surg* 2003; 29(4): 821–4.
9. *Suda T, Nishida T, Ohashi Y, Nakagawa S, Manabe R.* Fibronectin appears at the site of corneal stromal wound in rabbits. *Curr Eye Res* 1981; 1(9): 553–6.
10. *Wilson SE.* Analysis of the keratocyte apoptosis, keratocyte proliferation, and myofibroblast transformation responses after photorefractive keratectomy and laser in situ keratomileusis. *Trans Am Ophthalmol Soc* 2002; 100: 411–33.
11. *Lee DA, Wilson MR, Yoshizumi MO, Hall M.* The ocular effects of gases when injected into the anterior chamber of rabbit eyes. *Arch Ophthalmol* 1991; 109(4): 571–5.
12. *Michels RG, Kenyon KR, Maumenne E.* Retrocorneal fibrous membrane. *Invest Ophthalmol* 1972; 11(10): 822–31.
13. *Nikolic L, Friend J, Taylor S, Thoft RA.* Inhibition of vascularization in rabbit corneas by heparin: cortisone pellets. *Invest Ophthalmol Vis Sci* 1986; 27(4): 449–56.
14. *Sherrard ES, Rycroft PV.* Retrocorneal membranes. II. Factors influencing their growth. *Br J Ophthalmol* 1967; 51(6): 387–93.
15. *Sherrard ES, Rycroft PV.* Retrocorneal membranes. I. Their origin and structure. *Br J Ophthalmol* 1967; 51(6): 379–86.
16. *Thompson RW, Price MO, Bowers PJ, Price FW.* Long-term graft survival after penetrating keratoplasty. *Ophthalmology* 2003; 110(7): 1396–402.
17. *Patel NP, Kim T, Rapuano CJ, Cohen EJ, Laibson PR.* Indications for and outcomes of repeat penetrating keratoplasty. *Ophthalmology* 2000; 107(4): 719–24.
18. *Weisbrod DJ, Sit M, Naor J, Slomovic AR.* Outcomes of repeat penetrating keratoplasty and risk factors for graft failure. *Cornea* 2003; 22(5): 429–34.
19. *van Horn DL, Sendele DD, Seideman S, Bucu PJ.* Regenerative capacity of the corneal endothelium in rabbit and cat. *Invest Ophthalmol Vis Sci* 1977; 16(7): 597–613.
20. *Heindl LM, Hofmann-Rummelt C, Schlötzer-Schrehardt U, Kruse FE, Cursiefen C.* Histologic analysis of descemet stripping in posterior lamellar keratoplasty. *Arch Ophthalmol* 2008; 126(4): 461–4.
21. *Caldwell MC, Afshari NA, Decroos FC, Proia AD.* The histology of graft adhesion in descemet stripping with endothelial keratoplasty. *Am J Ophthalmol* 2009; 148(2): 277–81.
22. *Shulman J, Kropinak M, Ritterband DC, Perry HD, Sedor JA, McCormick SA, et al.* Failed descemet-stripping automated endothelial keratoplasty grafts: a clinicopathologic analysis. *Am J Ophthalmol* 2009; 148(5): 752–9.
23. *Sub LH, Yoo SH, Deobhakta A, Donaldson KE, Alfonso EC, Culbertson WW, et al.* Complications of Descemet's stripping with automated endothelial keratoplasty: survey of 118 eyes at One Institute. *Ophthalmology* 2008; 115(9): 1517–24.
24. *Bansal R, Ramasubramanian A, Das P, Sukhija J, Jain AK.* Intra-corneal epithelial ingrowth after descemet stripping endothelial keratoplasty and stromal puncture. *Cornea* 2009; 28(3): 334–7.

25. Price FW Jr, Price MO. Descemet's stripping with endothelial keratoplasty in 50 eyes: a refractive neutral corneal transplant. *J Refract Surg* 2005; 21(4): 339–45.
26. Price FW Jr, Price MO. Descemet's stripping with endothelial keratoplasty in 200 eyes: Early challenges and techniques to enhance donor adherence. *J Cataract Refract Surg* 2006; 32(3): 411–8.
27. Kim JY, Kim MJ, Kim T, Choi H, Pak JH, Tchah H. A femtosecond laser creates a stronger flap than a mechanical microkeratome. *Invest Ophthalmol Vis Sci* 2006; 47(2): 599–604.
28. Terry MA, Hoar KL, Wall J, Ousley P. Histology of dislocations in endothelial keratoplasty (DSEK and DLEK): a laboratory-based, surgical solution to dislocation in 100 consecutive DSEK cases. *Cornea* 2006; 25(8): 926–32.
29. Sbarbaro JA, Eagle RC, Thumma P, Raber IM. Histopathology of posterior lamellar endothelial keratoplasty graft failure. *Cornea* 2008; 27(8): 900–4.
30. Obata H, Tsuru T. Corneal wound healing from the perspective of keratoplasty specimens with special reference to the function of the Bowman layer and descemet membrane. *Cornea* 2007; 26: 9 (Suppl 1): S82–9.
31. Sherrard ES. Further studies on the retrocorneal membrane-endothelium relationship. *Br J Ophthalmol* 1969; 53(12): 808–18.
32. Faia LJ, Baratz KH, Bourne WM. Corneal graft folds: a complication of deep lamellar endothelial keratoplasty. *Arch Ophthalmol* 2006; 124(4): 593–5.
33. Melles GR. Posterior lamellar keratoplasty. DLEK to DSEK to DMEK. (editorial). *Cornea* 2006; 25(8): 879–81.
34. Melles GR, Eggink FA, Lander F, Pels E, Rietveld FJ, Beekhuis WH, et al. A surgical technique for posterior lamellar keratoplasty. *Cornea* 1998; 17(6): 618–26.
35. McCulloch C, Thompson GA, Basu PK. Lamellar Keratoplasty Using Full Thickness Donor Material. *Trans Am Ophthalmol Soc* 1963; 61: 154–80.
36. Price FW Jr, Price MO. Endothelial keratoplasty to restore clarity to a failed penetrating graft. *Cornea* 2006; 25(8): 895–9.
37. Nikolic L, Jovanovic V, Lackovic V, Todorovic V. Endothelial keratoplasty without descemet's membrane stripping: histologic and ultrastructural findings. *Ophthalmic Res* 2010; 43(1): 56–60.
38. Hatanaka H, Koizumi N, Okumura N, Takabashi H, Tanioka H, Young RD, et al. A study of host corneal endothelial cells after non-Descemet stripping automated endothelial keratoplasty. *Cornea* 2013; 32(1): 76–80.
39. Park CY, Chuck RS. Non-Descemet stripping Descemet membrane endothelial keratoplasty. *Cornea* 2013; 32(12): 1607–9.
40. Masaki T, Kobayashi A, Yokogawa H, Saito Y, Sugiyama K. Clinical evaluation of non-Descemet stripping automated endothelial keratoplasty (nDSEK). *Jpn J Ophthalmol* 2012; 56(3): 203–7.
41. Chaurasia S, Ramappa M, Sangvan VS. Clinical outcomes of non-Descemet stripping automated endothelial keratoplasty. *Int Ophthalmol* 2012; 32(6): 571–5.
42. Folkman J, Klagsbrun M, Sasse J, Wadzinski M, Ingber D, Vlodavsky I. A heparin-binding angiogenic protein--basic fibroblast growth factor--is stored within basement membrane. *Am J Pathol* 1988; 130(2): 393–400.

Received on April 22, 2014.

Revised on August 16, 2014.

Accepted on August 19, 2014.

Online First September, 2015.