



Influence of postoperative low-level laser therapy on the osseointegration of self-tapping implants in the posterior maxilla: A 6-week split-mouth clinical study

Uticaj postoperativne terapije laserom male snage na oseointegraciju samourezujućih implantata u bočnoj regiji gornje vilice: šestonedeljna *split-mouth* klinička studija

Borka Mandić*, Zoran Lazić†‡, Aleksa Marković*, Bojan Mandić§, Miška Mandić¶, Ana Djinić*, Biljana Miličić||

*Clinic of Oral Surgery, §Clinic of Maxillofacial Surgery, ||Department for Medical Statistics and Informatics, ¶Department of Orthodontics, Faculty of Dental Medicine, University of Belgrade, Belgrade, Serbia; †Clinic of Dental Medicine, Military Medical Academy, Belgrade, Serbia; ‡Faculty of Medicine of the Military Medical Academy, University of Defence, Belgrade, Serbia

Abstract

Background/Aim. Low-level laser therapy (LLLT) has been proven to stimulate bone repair, affecting cellular proliferation, differentiation and adhesion, and has shown a potential to reduce the healing time following implant placement. The aim of this clinical study was to investigate the influence of postoperative LLLT osseointegration and early success of self-tapping implants placed into low-density bone. **Methods.** Following the split-mouth design, self-tapping implants ($n = 44$) were inserted in the posterior maxilla of 12 patients. One jaw side randomly received LLLT (test group), while the other side was placebo (control group). For LLLT, a 637 nm gallium-aluminum-arsenide (GaAlAs) laser (Medicolaser 637, Technoline, Belgrade, Serbia) with an output power of 40 mW and continuous wave was used. Low-level laser treatment was performed immediately after the surgery and then repeated every day in the following 7 days. The total irradiation dose *per* treatment was 6.26 J/cm² *per* implant. The study outcomes were: implant stability, alkaline-phosphatase (ALP)

activity and early implant success rate. The follow-up took 6 weeks. **Results.** Irradiated implants achieved a higher stability compared with controls during the entire follow-up and the difference reached significance in the 5th postoperative week (paired *t*-test, $p = 0.030$). The difference in ALP activity between the groups was insignificant in any observation point (paired *t*-test, $p > 0.05$). The early implant success rate was 100%, regardless of LLLT usage. **Conclusion.** LLLT applied daily during the first postoperative week expressed no significant influence on the osseointegration of self-tapping implants placed into low density bone of the posterior maxilla. Placement of self-tapping macro-designed implants into low density bone could be a predictable therapeutic procedure with a high early success rate regardless of LLLT usage.

Key words: dental implants; oral surgical procedures; laser therapy, low-level; bone regeneration; alkaline phosphatase; treatment outcome.

Apstrakt

Uvod/Cilj. Terapija laserom male snage (TLMS) stimuliše reparatorne sposobnosti kosti utičući na ćelijsku proliferaciju, diferencijaciju i adheziju, i ima potencijal da skрати vreme zarastanja kosti nakon ugradnje implantata. Cilj ove kliničke studije bio je da se ispita uticaj postoperativne primene TLMS na oseointegraciju i rani uspeh ugradnje samourezujućih implantata u kost male gustine. **Metode.** Prateći *split-mouth* dizajn, samourezujućih implantata ($n = 44$) ugrađeni su u posterioarne regije gornje vilice 12 pacijenata. Slučajnim iz-

borom, jednoj od strana vilice je dodeljena TLMS (test grupa), dok je druga strana bila placebo (kontrolna grupa). Za TLMS korišćen je galijum-aluminijum-arsenid (GaAlAs) laser (Medicolaser 637, Technoline, Beograd, Srbija) talasne dužine 637 nm, snage 40 mW, neprekidnog režima rada. Tretman laserom male snage sprovodio se neposredno po ugradnji, a zatim svakodnevno, tokom narednih sedam dana. Ukupna zračna doza po tretmanu bila je 6,26 J/cm² po implantatu. Praćeni su stabilnost implantata, aktivnost alkalne fosfataze (ALP) i procenat rane uspešnosti implantatne terapije. Period praćenja bio je šest nedelja. **Rezultati.** Zra-

čeni implantati imali su veću stabilnost u odnosu na kontrolne tokom celog perioda praćenja, a statistički značajno veća stabilnost bila je u petoj postoperativnoj nedelji (t -test za vezane uzorke, $p = 0.030$). Razlika u aktivnosti ALP između grupa nije bila statistički značajna ni u jednoj tački posmatranja (t -test za vezane uzorke, $p > 0.05$). Procenat rane uspešnosti terapije implantatima bio je 100%, bez obzira na primenjenu TLMS. **Zaključak.** Svakodnevna primena TLMS u prvoj postoperativnoj nedelji nije pokazala značajan uticaj na oseointegraciju samourežujućih implantata u

kost male gustine bočne regije gornje vilice. Primena implantata samourežujućeg makrodizajna u kosti male gustine mogla bi predstavljati predvidljivu terapijsku proceduru sa visokim procentom rane uspešnosti, bez obzira na primenjenu TLMS.

Ključne reči:

implantati, stomatološki; hirurgija, oralna, procedure; lečenje laserom male snage; kost, regeneracija; alkalna fosfataza; lečenje, ishod.

Introduction

Low-level laser therapy (LLLT) has been used for more than 30 years in the medical field and no adverse effects have been reported¹. It is defined as red beam or near-infrared laser therapies of low energy density and output power, with wavelengths between 500 and 1,200 nm, that do not increase normal tissue and body temperature¹. Its effects are therefore nonthermal and biostimulative.

As LLLT affects various tissue responses such as blood flow, inflammation, cellular proliferation and/or differentiation², stimulation with LLLT creates a number of environmental conditions that appeared to have accelerated healing of bone defects in animal models and clinical investigations²⁻⁵.

Though the exact mechanism of these effects is not elucidated yet, they are considered to be results of laser irradiation on the cell membrane, mitochondria, DNA and RNA synthesis, collagen synthesis, neovascularization, cell proliferation, and the production of ATP⁶.

In oral implantology, research has been focused on the potential of LLLT to reduce the healing time following implant placement and to improve the potential for bone regeneration².

Previous experimental studies reported that low-level laser treatment stimulated proliferation and differentiation of osteoblasts⁷⁻¹¹ as well as their bonding to titanium implant⁷. It significantly increased alkaline phosphatase (ALP) activity, which is considered to be a marker of differentiated osteoblasts, in culture^{8,9,11} and animal models¹⁰. When applied in the early postoperative period, LLLT lead to an enhancement of the mechanical strength of bone-implant interface¹²⁻¹⁴ and stimulation of bone matrix production and bone nodule formation⁹.

There are a number of studies suggesting that low-level laser treatment in the early postoperative period after implant placement may lead to a positive clinical effect².

As low-density bone (D3 and D4 class of bone, Leckholm & Zarb classification¹⁵) is usually present in the molar region of the upper jaw, this has proven to be the region of lower success rates of dental implant therapy due to lack of primary stability that can be obtained¹⁶. Postoperative LLLT might have potential beneficial influence on dental implant treatment in this area, making it more predictable.

The aim of our study was to investigate the influence of postoperative LLLT on osseointegration of self-tapping im-

plants placed into low density bone, by investigating and comparing clinical status – implant stability with the appearance of the marker of alkaline phosphatase in the periimplant crevicular fluid. The second aim was to evaluate early success rate of implants placed into the premolar/molar maxillary region, regarding LLLT.

Methods

The study was conducted in accordance with the 1975 Declaration of Helsinki, as revised in 2002. The protocol was approved by the Ethics Committee of the Faculty of Dentistry, University of Belgrade (No.36/22), and the patients gave their written informed consent. Written patient's consent was also obtained to publish clinical photographs.

A total of 12 patients (6 males and 6 females) seeking implant therapy for bilateral reconstruction in the posterior maxilla were recruited for this study. All the patients were healthy adults, age 18 or older. The patients were selected in accordance with the following inclusion criteria: sufficient bone volume to receive implants without requiring bone augmentation (reconstruction) procedures and no history of previous tooth extraction in the last six months in the selected area. Exclusion criteria were: 1) systemic: pregnancy or lactation, systemic disease that affects osseointegration, anticoagulant therapy, systemic glucocorticoid therapy, history of radiotherapy in the craniofacial region within last 12 months, smoking habit of more than 10 cigarettes per day and 2) local: acute infection in the mouth, uncontrolled or untreated periodontal disease.

For patients' selection and treatment planning, panoramic radiographs and 3D computed tomography scans were required, followed by clinical intraoral examination.

Following split mouth design, a total of 44 self-tapping BlueSky® (Bredent, Germany) implants with diameter of 4 mm and length of 10 mm were inserted bilaterally and symmetrically in the posterior maxilla of the selected patients.

Local anesthesia was induced by infiltration with 2% lidocaine hydrochloride and 1: 80 000 adrenaline. After crestal incision and mucoperiosteal flap elevation, preparations of implant recipient sites were performed under cooling with physiological solution, according to the protocol following the manufacturer's instructions (Bredent, Germany). The speed of 15 rpm with a torque of 35 Ncm was set for insertion of all implants. The implants were allowed to heal transmucosally and sutures were removed after 7 days.

Postoperatively all the patients were prescribed amoxicillin (1.5 g) or clindamycin (1.8 g) daily, for three days as well as nonsteroidal anti-inflammatory drugs for pain relief. The patients were also given detailed instructions with regard to oral hygiene. No temporary prosthesis was placed during the entire 6-week observation period.

After the surgery, one of the sides of the upper jaw of the patients was randomly (computer-generated random numbers) chosen to receive low-level laser treatment (test group). The other side of the jaw was placebo, without any treatment performed and served as a control (control group).

A 637 nm gallium-aluminum-arsenide (GaAlAs) laser (Medicolaser 637, Technoline, Belgrade, Serbia) with an output power of 40 mW and continuous wave was used. The implant on the chosen side was irradiated intraorally, orthoradially to the implant's longitudinal axis (Figure 1). Low-level laser treatment was performed immediately after the surgery and then repeated every day in the following 7 days. The total irradiation dose per treatment was 6.26 J/cm² per implant.

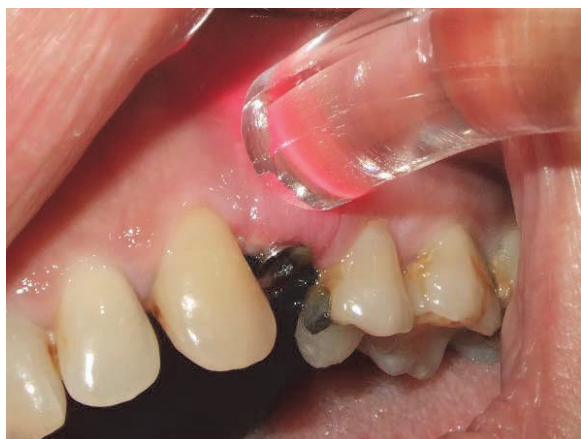

Fig. 1 – Postoperative low-level laser therapy. The operational field was irradiated by laser probe positioned intraorally, at a distance of 1 cm and orthoradially to the implant's longitudinal axis.

Evaluation of osseointegration of implants

All assessments of the study outcomes were performed in a double blind manner, since neither patients (due to placebo) or assessors (not involved in LLLT) were aware of treatment allocation.

Resonance frequency analysis (RFA) was performed using the Osstell™ Mentor instrument (Integration Diagnostics, Göteborg, Sweden) by a trained calibrated operator who was unaware of which side would be irradiated. Measurements were recorded immediately after implant insertion and then postoperatively in a weekly manner during the following 6 weeks. A standardized abutment of fixed length (Smartpeg™ Integration Diagnostics, Göteborg, Sweden) was inserted and hand-tightened into each implant. The transducer probe (Osstell™ Mentor Probe) was held so that the probe tip was aimed at the small magnet on top of the Smartpeg™ at a distance of 2–3 mm (Figure 2). It was held still until the instrument beeped and displayed the implant stability quotient (ISQ) value. Each measurement was repeated until the same value

was recorded twice, which was accepted as the authentic value. For the post-surgical stability measurements, abutments were removed from the implants.

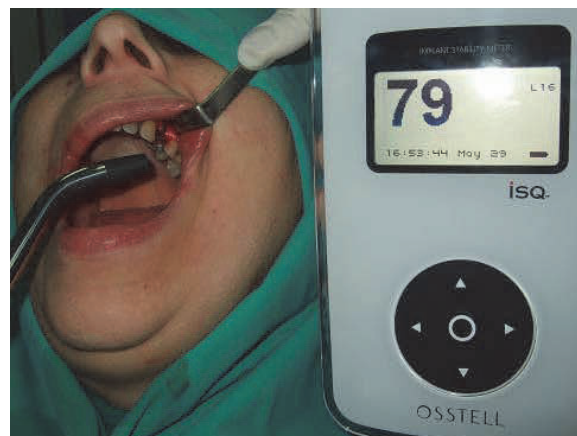


Fig. 2 – Implant stability measurement by means of resonance frequency analysis. The hand-held probe stimulates magnetically the transducer attached to the implant. The degree of implant stability is shown on the display as implant stability quotient value.

Evaluation of bone remodeling intensity and osteoblast differentiation

Peri-implant crevicular fluid (PICF) sampling was performed on the postoperative day 7, 14, 21 and 28.

To avoid mechanical irritation, blood contamination or stimulation of the PICF, PICF samples were collected before the clinical measurements. Briefly, following the isolation of the sampling area with sterile cotton rolls, supragingival plaque was removed and the sampling site was gently air dried to reduce any contamination with plaque and saliva. Extreme care was taken to minimize the level of mechanical irritation during PICF sampling as this is known to affect the actual fluid volume in a given site. Standardized sterile paper strip (Periopaper® N° 593525, Oraflow Inc, Amityville NY) was placed at the entrance of peri-implant sulcus and pushed until minimal resistance was felt (Figure 3). Sampling time was

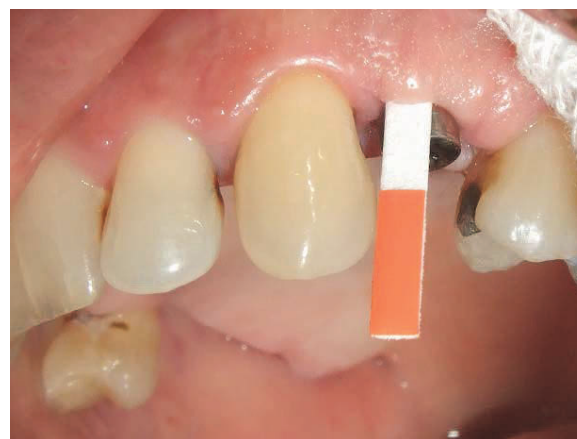

Fig. 3 – Peri-implant crevicular fluid collection. After the isolation of implant sites with cotton rolls, standardized paper strips were inserted into the sulci until a slight resistance was felt.

standardized as 60 s. Samples with visible blood contaminations were discarded. Paperstrips with PICF from single implants were immediately used for ALP activity determination.

A quantity of 20 μ l of distilled water was added to each sample. The tubes were vigorously shaken for 1 min and then centrifuged at 2,000 g for 5 min with the strips kept at the collar of the tube in order to completely elute PICF components.

ALP activity was assayed spectrophotometrically with spectrophotometer at 405 nm (Secomam Basic, France). The principle of method is coloured reaction in which ALP hydrolyses p-nitrophenyl phosphate in the presence of magnesium ions to yellow product p-nitrophenol and inorganic phosphate. The reaction of 10 μ l of the sample with 500 μ l of the working reagent is at 37 °C, and the rate of increase in absorbance is read after 1 min, then in 1 min intervals and finally recorded after 4 minutes at 405 nm. ALP activity is expressed in U, where U (international unit) represents the amount of enzyme that catalyses release of 1 μ mol of p-nitrophenol per min at 37 °C. The final results were reported as total ALP activity (U/sample).

Evaluation of early implant success

Early implant success was evaluated after the sixth postoperative week using the following criteria proposed by Buser et al.¹⁷: 1) the absence of recurring peri-implant infection with suppuration; 2) the absence of persistent subjective complaints such as pain, foreign body sensation, and/or dysesthesia, 3) the absence of a continuous radiolucency around the implant and 4) the absence of any detectable implant mobility.

Possible adverse events related to LLLT were also recorded during a 6-week follow-up.

(CI). One-sample Kolmogorov–Smirnov test was used to assess the normality of data distribution. Repeated measures analysis of variance was performed to analyze changes of ISQ, as well as ALP activity data, during the observation period and was followed by *post hoc* least significant difference test to determine differences within groups between particular observation points. The statistical significance of differences in the observed parameters (ISQ and ALP activity) between the groups in each observation point was analyzed using paired samples *t*-test since data from strictly symmetrical positions of the implants were compared (split-mouth design). The statistical significance of all tests was defined as $p < 0.05$.

Results

Twelve eligible patients were enrolled in the study. They received a total of 44 implants. Since all 4 implants of one male patient aged 68 inserted bilaterally into the regions of the first and the second maxillary molars failed to achieve primary stability sufficient for the one-stage surgery approach, they were covered, not irradiated and excluded from the study. Eleven remaining patients of both genders (5 females and 6 males), mean age 61.28 years (55 to 75) enrolled in this study completed the study protocol. They received a total of 40 implants bilaterally inserted into premolar and/or molar maxillary regions, with 20 implants randomly and symmetrically attributed to each of the two groups, irradiated (test) or non-irradiated (control) group that were included in the analyses. A total follow-up period per patient was 6 weeks.

Resonance frequency analysis

Within the test group significant changes were recorded during a 6-week follow-up ($p = 0.016$) (Table 1, Figure 4).

Table 1
Descriptive statistics for implant stability measurements by means of resonance frequency analysis in test (irradiated) and control (non-irradiated) implants at baseline and during six postoperative weeks

Time	Side	$\bar{x} \pm SD$	Med	Min	Max	95% CI
Baseline	test	76.00 \pm 3.52	75.5	70	82	74.25–77.75
	control	72.89 \pm 7.15	74.5	56	80	69.33–76.45
1st week	test	74.88 \pm 3.40	75	70	82	73.06–76.69
	control	74.69 \pm 4.80	74.5	67	84	72.13–77.24
2nd week	test	74.22 \pm 3.93	74	68	81	72.27–76.18
	control	72.56 \pm 5.67	72.5	61	80	69.74–75.37
3rd week	test	72.67 \pm 3.65	73	61	77	70.85–74.48
	control	70.44 \pm 6.16	70	55	80	67.38–73.51
4th week	test	72.50 \pm 4.18	73	60	77	70.42–74.58
	control	69.22 \pm 9.09	70	39	79	64.70–73.74
5th week	test	72.94 \pm 3.92	73.5	63	79	71.00–74.89
	control	69.83 \pm 7.03	71.5	48	78	66.34–73.33
6th week	test	72.67 \pm 3.69	73.5	63	78	70.83–74.50
	control	70.61 \pm 7.20	72	52	79	67.03–74.19

The results are presented as implant stability quotient values.

CI – confidence interval.

Statistical analysis was performed using the SPSS[®] 17.0 software (SPSS Inc., Chicago, IL, USA). Implants were used as units of analysis. ISQ and ALP activity data were reported using measures of central tendency (mean, median) and variation (standard deviation, min, max, 95% confidence interval

The maximum stability was achieved at baseline and afterwards significantly declined in the 2nd, 3rd and 4th week ($p = 0.029$; $p = 0.007$; $p = 0.008$; respectively) with the minimal recorded value in the 4th week. In the 5th week it started to rise insignificantly, but fell again in the 6th week, in both ob-

ervation points still being significantly lower than the baseline stability ($p = 0.017$; $p = 0.005$; respectively). The differences in ISQ values between both consecutive weeks within the test group were not significant ($p > 0.05$).

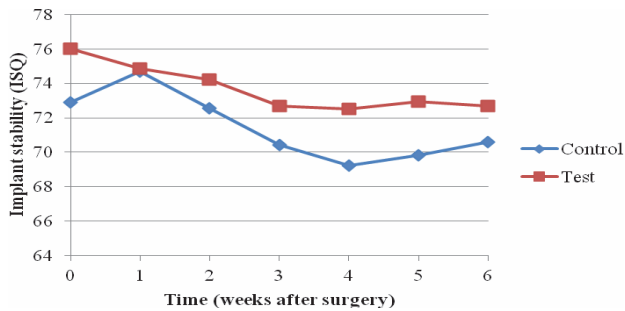


Fig. 4 – Effect of low-level laser therapy on implant stability measured by resonance frequency analysis.

In the control group significant changes in implant stability over time were revealed ($p = 0.023$) (Table 1, Figure 4). The maximum implant stability was achieved in the 1st week, and afterwards significantly decreased in the consecutive 2nd and 3rd week ($p = 0.047$; $p = 0.044$; respectively). An insignificant decrease continued in the 4th week ($p = 0.234$), when the minimum value was recorded and was significantly lower than baseline stability ($p = 0.039$). Afterwards it started to rise insignificantly during the 5th and 6th consecutive weeks ($p = 0.401$; $p = 0.110$; respectively) with ISQ values recorded in the 5th week being significantly lower compared to baseline stability ($p = 0.029$) whereas stability recorded in the 6th week was insignificantly different compared to baseline ($p = 0.074$).

Between group comparative analysis revealed higher ISQ values in the test group compared to the controls dur-

ing the entire 6-week observation period with the difference being statistically significant in the 5th week ($p = 0.030$) (Table 2). The highest implant stability was recorded at baseline, in the test group. Both groups showed the "stability dip" (with the lowest ISQ values) in the 4th week, with the minimal recorded ISQ value in the control group (Figure 4).

Alkaline-phosphatase activity

Within the test group, statistically significant changes of ALP activity were observed during the 4-week observation period ($p < 0.0005$) (Table 3, Figure 5). The highest ALP activity was recorded in the 1st week and afterwards significantly decreased in the 2nd week ($p \leq 0.005$). An insignificant decrease continued from the 2nd week till the 3rd week ($p = 0.175$) followed by an insignificant increase recorded in the 4th week ($p = 1.000$). The ALP activity value in each observation point (2nd, 3rd and 4th week) was significantly lower than in the 1st postoperative week ($p \leq 0.0005$; $p \leq 0.0005$; $p = 0.010$; respectively).

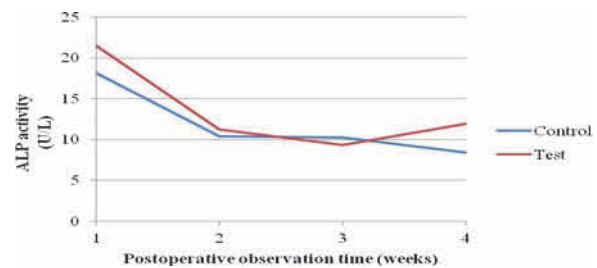


Fig. 5 – Effect of low-level laser therapy on alkaline phosphatase (ALP) activity in peri-implant crevicular fluid, measured spectrophotometrically during a 4-week observation period.

Table 2
Differences in implant stability between irradiated (test) and non-irradiated (control) implants

Time	Implant stability quotient ($\bar{x} \pm SD$)			<i>p</i>
	test	control	95% CI for MD	
Baseline	76.00 ± 3.52	72.89 ± 7.15	-0.78177 to 7.00399	0.110
1st week	74.88 ± 3.40	74.69 ± 4.80	-3.45378 to 3.82878	0.914
2nd week	74.22 ± 3.93	72.56 ± 5.67	-1.73616 to 5.06950	0.316
3rd week	72.67 ± 3.65	70.44 ± 6.16	-0.88360 to 5.32805	0.150
4th week	72.50 ± 4.18	69.22 ± 9.09	-0.72534 to 7.28089	0.102
5th week	72.94 ± 3.92	69.83 ± 7.03	0.34554 to 5.87668	0.030*
6th week	72.67 ± 3.69	70.61 ± 7.20	-0.60045 to 4.71157	0.121

MD – mean difference; **p* values (paired samples *t*-test) – statistically significant; CI – confidence interval.

Table 3
Descriptive statistics for alkaline phosphatase activity assayed spectrophotometrically in test (irradiated) and control (non-irradiated) implants during four week observation period.

Time	Side	Mean	Med	Min	Max	95% CI
1st week	test	21.53 ± 6.65	24.47	9.87	30.13	18.22–24.84
	control	18.16 ± 5.11	17.92	9.73	26.87	15.62–20.71
2nd week	test	11.26 ± 4.64	10.40	4.48	17.77	8.95–13.57
	control	10.39 ± 4.05	9.35	4.68	17.17	8.23–12.55
3rd week	test	9.36 ± 4.23	8.82	4.20	19.32	7.25–11.46
	control	10.22 ± 4.26	8.50	3.08	17.92	8.03–12.41
4th week	test	11.96 ± 8.34	8.89	5.46	39.92	7.81–16.10
	control	8.45 ± 3.46	7.47	3.05	18.97	6.73–10.17

The results are presented as U/sample, where U (international unit) represents the amount of enzyme that catalyses release of 1 μmol of p-nitrophenol per min at 37 °C; CI – confidence interval.

In the control group ALP activity values significantly changed during the 4-week follow-up ($p < 0.0005$) (Table 3, Figure 5). The maximum ALP activity was recorded in the 1st postoperative week and then continuously declined until the end of the 4th week. This decline was significant in the 2nd, 3rd and 4th week ($p = 0.006$; $p = 0.003$; $p < 0.0005$; respectively) in comparison with the 1st one. The decrease in ALP activity between the 1st and the 2nd week was statistically significant ($p = 0.006$) whereas no significant difference in ALP activity was observed between the 2nd and 3rd week ($p = 1.000$), neither between the 3rd and 4th postoperative week ($p = 0.743$).

The mean ALP values were higher in the test group during a 4-week follow-up, except in the 3rd postoperative week, but the difference between the groups was not statistically significant at any time of observation (Table 4). The

self-tapping implants placed into low density bone of posterior maxilla.

A 637 nm GaAlAs laser has been chosen due to its beneficial effects on bone regeneration reported in animal³ and clinical studies⁴. LLLT has been found to increase osteoblastic proliferation, collagen deposition, and bone neoformation in the irradiated comparing to non-irradiated bone^{3,9}. Studies using animal models and human osteoblast-like cells cultures, demonstrated that the use of low-level laser after titanium implant insertion promoted osseointegration due to rapid bone turnover^{7,12} and seemed to accelerate active bone replacement without causing tissue or implant damage⁷. Histomorphometric evaluation in animal models revealed more bone-implant contact in the irradiated groups as compared to the controls at 3 and 6¹⁹ and 16 weeks postoperatively²⁰. These results suggest that LLLT may stimu-

Table 4
Differences in alkaline phosphatase (ALP) activity between irradiated (test) and non-irradiated (control) implants

Time	ALP ($\bar{x} \pm SD$)		95% CI of MD	<i>p</i>
	Test	Control		
1st week	21.53 \pm 6.65	18.16 \pm 5.11	-0.50252 to 7.24085	0.084
2nd week	11.26 \pm 4.64	10.39 \pm 4.05	-0.26683 to 3.42371	0.088
3rd week	9.36 \pm 4.23	10.22 \pm 4.26	-2.77642 to 1.61913	0.584
4th week	11.9 \pm 8.34	8.45 \pm 3.46	-0.85890 to 7.87234	0.108

ALP activity is presented in U/L; MD – mean difference; *p*- values (paired samples *t*-test)
CI – confidence interval.

pattern of ALP activity changes over time was different in the test and control groups (Figure 5). After the initial decline of ALP activity in the test group an increase in the 4th week was observed reaching values similar to those of the 2nd week ($p = 1.000$), whereas in the control group a continuous decrease was recorded.

Early implant success

The early implant success rate after the first six weeks (prior to implant placement) was 100%, regardless of LLLT usage. No adverse event was recorded during the follow-up.

Discussion

Osseointegration is an essential prerequisite for the dental implants' long-term prognosis. Therefore, chemical, biological and biophysical adjunctive therapies to improve and accelerate healing at bone-implant interface have been widely investigated¹⁸. This randomized, double blind, split-mouth clinical study was focused on the effect of postoperative LLLT using a 637 nm GaAlAs laser with an output power of 40 mW and total irradiation dose *per* treatment of 6.26 J/cm² *per* implant, on osseointegration of self-tapping implants placed into posterior maxilla. Our intention was to explore this effect on bone healing after dental implant placement in the maxillary premolar and/or molar region, being the area of the least predictable success of implant therapy¹⁶, where the use of LLLT might be of major clinical relevance. The results of our study suggest that LLLT did not significantly affect the osseointegration of

late bone repair, affecting cellular proliferation, differentiation and adhesion^{7-14, 19, 20}.

In this study osseointegration was evaluated through its two indicators – secondary implant stability measured by means of RFA and ALP activity assayed spectrophotometrically. Secondary implant stability is a clinical reflection of cellular events in peri-implant healing department and therefore indicates the rate and extent of osseointegration²¹. We used RFA as a non-invasive method that has proved to be a reliable tool to assess implant stability, determine different healing phases of dental implants and predict success of implant treatment²¹. Longitudinal ISQ values in both groups followed the usual pattern of changes with "stability dip" in the 4th postoperative week that reflected bone remodeling process when primary spongiosa was being replaced with lamellar and/or parallel-fibered bone^{16,22}. The trend of higher ISQ values recorded in the test group compared to controls during the entire 6-week period of observation, reached a significant difference in the 5th postoperative week. This result might suggest biomodulatory effect of LLLT that increases cellular activity and bone apposition but still not clinically significant to provide an earlier and better anchorage of implants. Statistically significant regeneration of bone tissue around irradiated implants was recorded in an intermediate period, which was in agreement with literature data^{13,23}. It has been shown that although LLLT is capable to increase the number of osteogenic cells in the very initial stage of healing, its effect on implant stabilization in this stage is still insignificant^{13,23}. Conversely, previous reports of animal studies reported that postoperative LLLT improved

biomechanical characteristics of bone-implant interface¹²⁻¹⁴. The authors agreed that single¹⁴ or multisession^{12,13} LLLT was beneficial to improve bone-implant interface strength, resulting in higher values of removal torque required to detach bone and implant in sites previously submitted to irradiation in comparison to non-irradiated sites^{13,14}.

The only clinical study that investigated the stability of oral implants after LLLT was the study of García-Morales et al.²⁴. Under the conditions of their study, no evidence was found of any effect of LLLT on the stability of implants when measured by RFA. The authors remarked that potential beneficial effect of LLLT was perhaps masked by high initial stability attained in the posterior mandible region²⁴. With regard to different irradiation protocol used in a García-Morales study²⁴ (infrared laser with seven irradiations repeated every 48 h for the first 14 days), as well as different implantation sites, comparison with our results is difficult.

In our study, during the whole 6-week observation period in both irradiated and non-irradiated implants, implant stability rates were high (≥ 69 ISQ), which is interesting, since the implantation site was the posterior maxilla. These results could probably be explained by the self-tapping implant design as has been previously demonstrated by a recent randomized clinical trial²⁵. Exceptionally, four implants of one male patient aged 68 inserted bilaterally into the regions of the first and the second maxillary molars failed to achieve primary stability sufficient for one stage surgery approach. Although the cause of poor implant stability remains unclear, the fact that all the implants were placed to the same patient indicates the probable systemic factor despite the inconspicuous medical history. Regardless of the possibility of LLLT to promote the osseointegration of implants with poor primary stability demonstrated in animal model²⁶ we decided to cover them and exclude from the study due to concerns that weekly RFA measurements during early healing might damage weak bone-implant interface resulting in implant failure.

We compared clinical status of the implant – its stability, with the appearance of the marker of ALP in the peri-implant crevicular fluid. ALP is considered to be a marker of differentiated osteoblasts and their activity, as early progenitor cells do not express ALP activity but differentiate through a defined number of cell divisions to express ultimately a mature osteoblast phenotype that is capable of bone formation²⁷. Our results revealed significant changes in ALP activity longitudinally in time, i.e. during the 4-week observation period, within both groups. The significantly enhanced ALP activity in the early stage of bone tissue healing (first postoperative week) was found in both irradiated and non-irradiated implants. As new bone formation starts as early as 1 week after implant placement when the primary bone contacts are supplemented by newly formed secondary bone contacts²⁸, this result may indicate an intensive osteoblastic activity around implants, i.e. bone formation. On the other hand, a subsequent decrease of ALP activity from the second week and onwards, would therefore be the result of greater presence of differentiated cells (osteocytes) at the implant-bone interface. However, this is un-

likely the case, as this is too early for the bone deposition process to decline. Apart from that released from osteoblasts during bone remodeling, ALP found in PICF can also derive from polymorphonuclear cells during inflammation²⁹ and periodontal fibroblasts during periodontal regeneration³⁰. Increased ALP activity in the first postoperative week is therefore more likely the result of inflammation that occurs as a physiological response to operation trauma, and which presents the first phase of osseointegrating process.

Although our results showed no statistically significant difference in ALP activity between the test and control group in all observation points, the pattern of ALP activity changes over time was different. In contrast to the control group where continuous decrease of ALP activity was recorded, in the test group after the initial decline, an increase was observed in the 4th week. The increase in ALP activity in the laser group might be interpreted as an indication of enhanced osteoblast activity and therefore, improved bone neoformation and mineralization. This biochemical result was supported by our clinical finding from the 5th observation week when a significantly higher stability was recorded for irradiated implants compared to controls, suggesting beneficial effect of LLLT on osseointegration.

Previous *in vitro*^{8,9,11} and animal¹⁰ studies reported on enhancements in the ALP activity as well as matrix formation after LLLT, which the authors considered as an indication of increased osteoblastic activity after LLLT.

Generalisation of our results might be affected by bone density, implant macro design, as well as irradiation protocol we used. In the literature, there is no consensus regarding LLLT protocol. The ideal wave length, energy density and irradiation protocol are perhaps yet to be determined. Furthermore, we have used self-tapping implant macro design since it has been recommended for low density bone of posterior maxilla in order to achieve sufficient implant stability²⁵. However, non self-tapping implants are not so effective in providing good primary stability into spongy bone and more pronounced effect of LLLT on the healing of such implants could be expected since the effect of LLLT in our study might be masked by self-tapping design.

Conclusion

Low-level-laser therapy applied daily during the first postoperative week using a 637 nm gallium-aluminum-arsenide (GaAlAs) laser with an output power of 40 mW and total irradiation dose *per* treatment of 6.26 J/cm² *per* implant expressed no significant influence on the osseointegration of self-tapping implants placed into low density bone of posterior maxilla. Placement of self-tapping macro-designed implants into low density bone could be predictable therapeutic procedure with a high early success rate regardless the low-level laser therapy use.

Acknowledgements

The study was financially supported in part by Bredent, Senden, Germany.

R E F E R E N C E S

1. *Harris DM*. Biomolecular mechanism of laser biostimulation. *J Clin Laser Med Surg* 1991; 9(4): 277–80.
2. *Stanford OT, Beirne R, Ellingsen JE*. Effects of Low-Level Laser Treatment on Bone Regeneration and Osseointegration of Dental Implants. *Int J Oral Maxillofac Implants* 2007; 22(5): 691–5.
3. *Marković A, Koković V, Todorović L*. The influence of low-power laser on healing of bone defects: An experimental study. *J Oral Laser Applic* 2005; 5: 169–72.
4. *Marković A, Todorović L*. The Influence of Low-power Laser on Healing of Bone Defects after Periapical Surgery: A Clinical Study. *J Oral Laser Applic* 2006; 6: 163–8.
5. *Pinheiro AL, Gerbi ME*. Photoengineering of bone repair processes. *Photomed Laser Surg* 2006; 24(2): 169–78.
6. *Karu T*. Photobiology of low-power laser effects. *Health Phys* 1989; 56(5): 691–704.
7. *Khadra M, Lyngstadaas SP, Haanaes HR, Mustafa K*. Effect of laser therapy on attachment, proliferation and differentiation of human osteoblast-like cells cultured on titanium implant material. *Biomaterials* 2005; 26(17): 3503–9.
8. *Stein E, Koehn J, Sutter W, Wendtlandt G, Wanschütz F, Thurnber D, et al*. Initial effects of low-level laser therapy on growth and differentiation of human osteoblast-like cells. *Wien Klin Wochenschr* 2008; 120(3–4): 112–7.
9. *Ozuna Y, Shimizu N, Kariya G, Abiko Y*. Low-energy laser irradiation stimulates bone nodule formation at early stages of cell culture in rat calvarial cells. *Bone* 1998; 22(4): 347–54.
10. *da Silva AP, Petri AD, Crippa GE, Stuaní AS, Stuaní AS, Rosa AL, et al*. Effect of low-level laser therapy after rapid maxillary expansion on proliferation and differentiation of osteoblastic cells. *Lasers Med Sci* 2012; 27(4): 777–83.
11. *Abramovitch-Gottlieb L, Gross T, Naveh D, Geresb S, Rosenwaks S, Bar I, et al*. Low level laser irradiation stimulates osteogenic phenotype of mesenchymal stem cells seeded on a three-dimensional biomatrix. *Lasers Med Sci* 2005; 20(3–4): 138–46.
12. *Khadra M, Ronold HJ, Lyngstadaas SP, Ellingsen JE, Haanaes HR*. Low-level laser therapy stimulates bone-implant interaction: an experimental study in rabbits. *Clin Oral Implants Res* 2004; 15(3): 325–32.
13. *Maluf AP, Maluf RP, da Brito CR, França FM, de Brito RB*. Mechanical evaluation of the influence of low-level laser therapy in secondary stability of implants in mice shinbones. *Lasers Med Sci* 2010; 25(5): 693–8.
14. *Boldrini C, de Almeida JM, Fernandes LA, Ribeiro FS, Garcia VG, Theodoro LH, et al*. Biomechanical effect of one session of low-level laser on the bone-titanium implant interface. *Lasers Med Sci* 2013; 28(1): 349–52.
15. *Lekholm U, Zarb GA*. Patient selection and preparation. In: *Branemark PI, Zarb GA, Albrektsson T*, editors. *Tissue-Integrated Prosthesis: Osseointegration in clinical dentistry*. 1st ed. Chicago: Quintessence; 1985. p. 199–210.
16. *Bischof M, Nedir R, Szemekler-Moncler S, Bernard J, Samson J*. Implant stability measurement of delayed and immediately loaded implants during healing. *Clin Oral Implants Res* 2004; 15(5): 529–39.
17. *Buser D, Weber HP, Lang NP*. Tissue integration of non-submerged implants. 1-year results of a prospective study with 100 ITI hollow-cylinder and hollow-screw implants. *Clin Oral Implants Res* 1990; 1(1): 33–40.
18. *Mavrogenis AF, Dimitriou R, Parvizí J, Babis GC*. Biology of implant osseointegration. *J Musculoskelet Neuronal Interact* 2009; 9(2): 61–71.
19. *Pereira CL, Sallum EA, Nociti FH, Moreira RW*. The effect of low-intensity laser therapy on bone healing around titanium implants: a histometric study in rabbits. *Int J Oral Maxillofac Implants* 2009; 24(1): 47–51.
20. *Jakse N, Payer M, Tangl S, Bergbold A, Kirmeier R, Lorenzoni M*. Resonance frequency analysis in relation to jawbone characterization and osseointegration of dental implants following sinus augmentation. An experimental study on sheep. *Clin Oral Implants Res* 2007; 18(4): 517–24.
21. *Meredith N*. Assessment of implant stability as a prognostic determinant. *Int J Prosthodont* 1998; 11(5): 491–501.
22. *Huñiler MA, Pjetursson BE, Bosshardt DD, Salvi GE, Lang NP*. Resonance frequency analysis in relation to jawbone characteristics and during early healing of implant installation. *Clin Oral Implants Res* 2007; 18(3): 275–80.
23. *Lopes CB, Pinheiro AL, Sathaiab S, Duarte J, Cristinamartins M*. Infrared laser light reduces loading time of dental implants: a Raman spectroscopic study. *Photomed Laser Surg* 2005; 23(1): 27–31.
24. *García-Morales JM, Tortamano-Neto P, Todescan FF, de Andrade JC, Marotti J, Zezell DM*. Stability of dental implants after irradiation with an 830-nm low-level laser: a double-blind randomized clinical study. *Lasers Med Sci* 2012; 27(4): 703–11.
25. *Marković A, Calvo-Guirado JL, Lazčić Z, Gómez-Moreno G, Calasan D, Guardia J, et al*. Evaluation of primary stability of self-tapping and non-self-tapping dental implants. A 12-week clinical study. *Clin Implant Dent Relat Res* 2013; 15(3): 341–9.
26. *Campanha BP, Gallina C, Geremia T, Loro RC, Valiati R, Hubler R, et al*. Low-level laser therapy for implants without initial stability. *Photomed Laser Surg* 2010; 28(3): 365–9.
27. *Owen TA, Aronow M, Shalhoub V, Barone LM, Wilming L, Tassinari MS, et al*. Progressive development of the rat osteoblast phenotype in vitro: reciprocal relationships in expression of genes associated with osteoblast proliferation and differentiation during formation of the bone extracellular matrix. *J Cell Physiol* 1990; 143(3): 420–30.
28. *Berglundh T, Abrahamsson I, Lang NP, Lindhe J*. De novo alveolar bone formation adjacent to endosseous implants. *Clin Oral Implants Res* 2003; 14(3): 251–62.
29. *Plagnat D, Giannopoulou C, Carrel A, Bernard J, Mombelli A, Belser UC*. Elastase, alpha2-macroglobulin and alkaline phosphatase in crevicular fluid from implants with and without periimplantitis. *Clin Oral Implants Res* 2002; 13(3): 227–33.
30. *Groeneveld MC, van den Bos T, Everts V, Beertsen W*. Cell-bound and extracellular matrix-associated alkaline phosphatase activity in rat periodontal ligament. *Experimental Oral Biology Group. J Periodont Res* 1996; 31(1): 73–9.

Received on December 2, 2013.

Accepted on February 6, 2014.

OnLine-First November, 2014.