

Changes in Soft Tissue Profile Using Functional Appliances in the Treatment of Skeletal Class II Malocclusion

Zorana Stamenković, Vanja Raičković, Vladimir Ristić

University of Belgrade, School of Dental Medicine, Department of Orthodontics, Belgrade, Serbia

SUMMARY

Introduction The effects of orthodontic treatment are considered to be successful if the facial harmony is achieved, while the structures of soft tissue profile are in harmony with skeletal structures of neurocranium and viscerocranium. In patients with skeletal distal bite caused by mandibular retrognathism, facial esthetics is disturbed often, in terms of pronounced convexity of the profile and change in the position and relationship of the lips.

Objective The aim of this study was to determine the extent of soft tissue profile changes in patients with skeletal Class II malocclusion treated with three different orthodontic appliances: Fränkel functional regulator type I (FR-I), Balters' Bionator type I and Hotz appliance.

Methods The study included 60 patients diagnosed with skeletal Class II malocclusion caused by mandibular retrognathism, in the period of early mixed dentition. Each subgroup of 20 patients was treated with a variety of orthodontic appliances. On the lateral cephalogram, before and after treatment, the following parameters were analyzed: T angle, H angle, the height of the upper lip, the position of the upper and lower lip in relation to the esthetic line. Within the statistical analysis the mean, maximum, minimum, standard deviation, coefficient of variation, two-factor analysis of variance with repeated measures and the factor analysis of variance were calculated using ANOVA, Bonferroni test and Student's t-test.

Results A significant decrease of angles T and H was noticed in the application of FR-I, from 21.60° to 17.15°, and from 16.45° to 13.40° ($p < 0.001$). FR-I decreased the height of the upper lip from 26.15 mm to 25.85 mm, while Hotz appliance and Balters' Bionator type I increased the height of the upper lip, thereby deteriorating esthetics of the patient.

Conclusion All used orthodontic appliances lead to changes in soft tissue profile in terms of improving facial esthetics, with the most distinctive changes in the application of Fränkel's functional regulator type I, which is the most successful appliance for achieving the overall facial harmony of the patient.

Keywords: Fränkel functional regulator; malocclusion, Angle Class II; orthodontic appliances, functional; soft tissue profile

INTRODUCTION

Skeletal Class II malocclusion is an orthodontic malocclusion that is very commonly found in the general population and requires a comprehensive treatment, considering that in addition to the disturbed occlusal morphology and functional variations, changes in facial esthetics and soft tissues are often present, which are one of the primary reasons why patients go to the orthodontist for help. Functional appliances can successfully affect not only skeletal and dentoalveolar structures, but also changed soft tissues of the face, resulting in harmony of the soft tissues with craniofacial structures, and providing significantly more acceptable facial appearance of the patient, primarily profile [1].

OBJECTIVE

The aim of this study was to determine how can different types of orthodontic appliances – Fränkel functional regulator type I (FR-I), Balters' Bionator type I and Hotz appliance – cause changes in soft tissue profile in the treat-

ment of distal skeletal bite during the period of intensive growth.

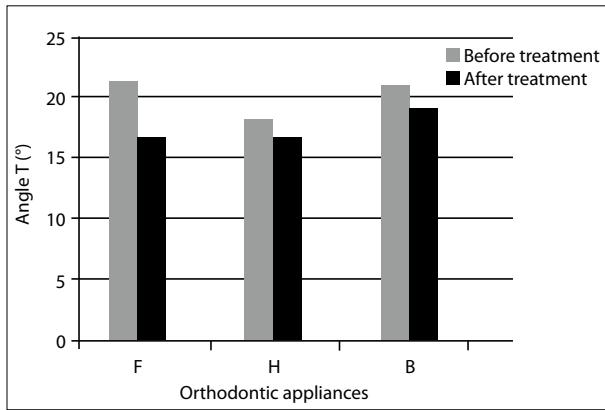
METHODS

The study included 60 patients with skeletal Class II malocclusion (the angle ANB > 4°). The entire sample was divided into 3 subgroups, with 20 patients in each: the first subgroup (Ia) was treated with the FR-I, the second subgroups (Ib) was treated with Balters' Bionator type I, and the third subgroup (Ic) was treated with Hotz appliance with a frontal inclined plane. All patients were in the age before the pubertal growth spurt, and because of that they were not divided by gender. There were 28 boys and 32 girls, 10 boys and 10 girls in subgroup Ia and Ib each, and 12 girls and 8 boys in subgroup Ic. Average chronologic age in the whole group was 9 years and 9 months, in subgroup Ia 8 years and 9 months, in Ib 10 years and 7 months, in Ic 10 years and 2 months. Clinical and functional analysis, analysis of study models, orthopantomogram (Siemens orthopantomograph 10, exposure 14 s) and lateral cephalogram (Philips,

Correspondence to:

Zorana STAMENKOVIĆ
Nevesinjska 12/1/5
11000 Belgrade
Serbia

zorana.stamenkovic@stomf.bg.ac.rs
zzokac@yahoo.com



Graph 1. Average values of angle T (°) before and after orthodontic treatment

F – Fränkel I; H – Hotz; B – Balters' I

Table 1. Statistical analysis of position of the upper lip (UL) related to the esthetic line (EL)

UL/EL	F1	F2	H1	H2	B1	B2
\bar{X} (mm)	0.77	0.12	-2.10	-1.75	-1.65	-1.50
SD	2.39	1.78	2.83	2.02	2.83	2.06
Max (mm)	4.00	3.00	3.00	2.00	4.00	1.00
Min (mm)	-4.00	-3.00	-8.00	-6.00	-10.00	-7.00
C cor	0.756		0.769		0.742	

F1 – Fränkel I before treatment; F2 – Fränkel I after treatment; H1 – Hotz before treatment; H2 – Hotz after treatment; B1 – Balters' I before treatment; B2 – Balters' I after treatment; \bar{X} – mean value; SD – standard deviation; Max – maximum value; Min – minimum value; C – coefficient of variation

1.7 m distance from the source of radiation to object, exposure 1.5 s) were done on each patient before the start of the treatment. Therapeutic effects of different orthodontic appliances and resulting changes were noticed and analyzed on control study models, orthopantomogram and lateral cephalogram, which were made upon completion of the orthodontic treatment. Average period of wearing the appliance was 18/24 months, with retention period also of 24 months. On lateral cephalogram these parameters were measured and analyzed: T angle; H angle (Holdaway); the position of the upper lip in relation to the esthetic line (UL/AL); the position of the lower lip in relation to the esthetic line (LL/AL); and height of the upper lip.

Statistical analysis included calculation of mean, maximum, minimum, standard deviation and coefficient of variation for each examined parameter. Statistical analysis included two-factor analysis of variance with repeated measures, in relation to time and group affiliation. One-factor analysis of variance was done using Anova test, Bonferroni test and Student's t-test.

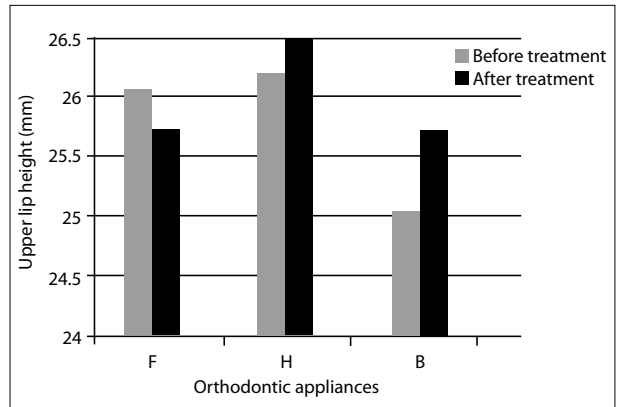
RESULTS

T angle was in correlation with facial inclination angle J and all of the used appliances led to a decrease in its value in the treatment of skeletal Class II (Graph 1). The largest decrease of T angle was caused by FR-I from 21.60° to 17.15°.

Patients with skeletal Class II malocclusion, mostly Class II Division 1 malocclusion, are characterized by changes in the position of the lips, which are potentially

Table 2. Statistical analysis of position of the lower lip (LL) related to esthetic line (EL)

LL/AL	F1	F2	H1	H2	B1	B2
\bar{X} (mm)	-1.00	0.00	-0.25	-0.45	-1.25	-0.40
SD	2.84	1.78	3.04	1.67	2.57	1.96
Maximum (mm)	4.00	3.00	6.00	3.00	4.00	3.00
Minimum (mm)	-9.00	-5.00	-6.00	-4.00	-7.00	-5.00
C cor	0.500		0.868		0.909	



Graph 2. Average values of upper lip height (mm) before and after orthodontic treatment

F – Fränkel I; H – Hotz; B – Balters' I

competent because of existing orthodontic malocclusion. During treatment the position of the upper lip to the esthetic line changes, its distance reduced in function of time (Table 1). The most prominent change in the position of the upper lip was caused by FR-I from 0.77 mm to 0.12 mm to EL.

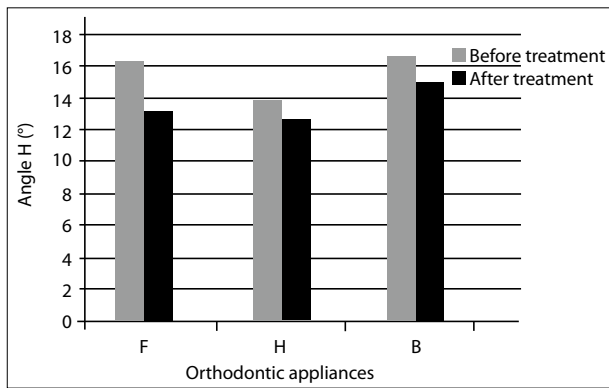
Treatment with FR-I reduced the distance of the lower lip to the esthetic line (EL) from -1.00 mm to 0.00 mm, as well as the treatment with Balters' Bionator type I from -1.25 mm to -0.40 mm. In contrast to them, Hotz appliance led to an increase in the distance of the lower lip to the esthetic line from -0.25 mm to -0.45 mm (Table 2).

During treatment with FR-I the height of the upper lips decreased from 26.15 mm to 25.85 mm. As opposed to that, the Balters' Bionator type I and Hotz appliance further increased the height of the upper lip, whereby the discrepancy of the soft tissue in relation to the skeletal structure and the dentoalveolar increased (Graph 2).

Holdaway angle (H) is in correlation with the value of the ANB angle. The decrease in the value of ANB angle led to the consequent reduction in the value of the angle H, using all three devices. The most significant decrease in the value of the angle H was caused by FR-I from 16.45° to 13.40°, with statistical significance at p<0.001 (Graph 3).

DISCUSSION

Facial esthetics is based on meeting the criteria of harmonic face and it refers to the establishment of balance between the skeletal and dentoalveolar structures, on one hand, and the soft tissue profile, on the other. During the process of growth and skeletal maturation the extent of changes in the soft tissues is greater than in the skeletal



Graph 3. Average values of angle H (°) before and after orthodontic treatment

F – Fränkel I; H – Hotz; B – Balters' I

structures, which is important for the stability of the therapeutic effect [2, 3]. The relations and proportions of facial soft tissues and relations of dentoalveolar structures to the lips and face are the main determinants of the overall appearance of the face [4]. In skeletal Class II malocclusion caused by mandibular retrognathism the changes in the soft tissues are a direct consequence of anterior displacement of the mandible [4, 5]. The angle T is in correlation with the value of angle J and it is significantly reduced in treatment, mainly with FR-I [6, 7, 8]. This provides a harmonious look of nasomaxillary complex, in accordance with the change of inclination of the whole face. Reduced values of T angle in treatment of the distal bite with FR-I and Balters' Bionator type I, were confirmed by Flores-Mir and Major [9], Melo Moreira et al. [10] and Stamenković [6]. The values of the angle H (Holdaway) are in correlation with the value of the ANB angle. During treatment the value of ANB angle decreases, with the consequent reduction in the value of angle H, which indicates a more correct relationship of skeletal structures in relation to the line of soft tissues [6, 11, 12]. The relationship of the lips is changed to further insertion of the lower lip between the upper and lower lip. Treatment with FR-I, Balters' Bionator type I and Hotz appliance reduces the distance of the upper lip to the esthetic line, which has changed position and function because of the prominent labial inclination of upper incisors [9, 13, 14]. Lingual inclination of the

upper incisors provides repositioning of the upper lip and reduction of its height, considering that before the start of the treatment the height of the upper lip was significantly increased due to the labial inclination of the incisors [15, 16]. Malta et al. [16] point out the importance of change in the sagittal position of the upper lip, in accordance to the change of the position of point A in soft tissues, and with the change in the soft tissues of the chin for 2.5 mm more than in the control group. Unlike them Siara-Olds et al. [17] observed no significant changes in the soft tissues that would improve facial contours, in treatment with functional appliances, primarily Bionator. The position of the lower lip is changed in the sense of reduced distance to the Ricketts' esthetic line, with the establishment of competent relationship with the upper lip, in treatment with FR-I type I and Bionator [18, 19], while the use of Hotz appliance leads to an increase in the distance to the esthetic line which further distorts facial esthetics and does not give satisfactory result [6]. Poor esthetic effect of Balters' Bionator and Hotz appliance is reflected in the increase of the overall height of the upper lip [6, 20, 21], which is considered to be an inadequate response of soft tissues to applied functional therapy. Changes of the upper and lower lip soft tissues and at the line of soft tissues result in the reduction of total profile convexity and in the anterior advancement of the skeletal and soft tissue structures of the chin and lower jaw [10, 14, 19].

CONCLUSION

During treatment with functional appliances, the structures of soft tissue profile are significantly changing, in a way of improving facial esthetics. The profile convexity of the patient reduces, better position of the upper and lower lip in relation to the esthetic line is achieved and harmony of soft tissues in relation to the skeletal structure is established, which are also changing and moving during orthodontic treatment. The most distinctive changes occur during treatment with the Fränkel's functional regulator type I, because it equally affects the skeletal and soft-tissue structures and contributes to an acceptable esthetic outcome of treatment for the patient and the therapist.

REFERENCES

- Bishara SE. Textbook of Orthodontics. Philadelphia: WB Saunders; 2001.
- Arat M, Köklü A, Ozdiler E, Rübendüz M, Erdoğan B. Craniofacial growth and skeletal maturation: a mixed longitudinal study. *Eur J Orthod.* 2001; 23:355-61.
- Ball G, Woodside D, Tompson B, Hunter WS, Posluns J. Relationship between cervical vertebral maturation and mandibular growth. *Am J Orthod Dent Orthop.* 2011; 139(5):455-61.
- Ward D M. Angle Class II, Division 1 malocclusion. *Am J Orthod Dent Orthop.* 1994; 106(4):428-33.
- McNamara JA. Components of Class II malocclusion in children 8-10 years of age. *Angle Orthod.* 2002; 51:177-202.
- Stamenković Z. Fränkel functional regulator in patients with skeletal Class II. *Belgrade: Zaduzbina Andrejević;* 2012.
- Frankel R, Frankel Ch. Orofacial Orthopaedics with the Function Regulator. Basel-München-Paris-London-New York-New Delhi-Singapore-Tokyo-Sydney: Karger; 1989.
- Alió-Sanz JJ, Iglesias-Conde C, Lorenzo-Periá J, Iglesias-Linares A, Mendoza-Mendoza A, Solano-Reina E. Craniofacial base and maxillary changes in patients treated with Frankel's functional regulator (1b). *Med Oral Patol Oral Cir Bucal.* 2012; 17(4):689-96.
- Flores-Mir C, Major PW. A systematic review of cephalometric facial soft tissue changes with the activator and bionator appliances in Class II division 1 subjects. *Eur J Orthod.* 2006; 28:586-93.
- Moreira Melo AC, dos Santos-Pinto A, da Rosa Martins JC, Martins LP, Sakima MT. Orthopedic and orthodontic components of Class II, division 1 malocclusion correction with Balters Bionator: A cephalometric study with metallic implants. *World J Orthod.* 2003; 4:273-42.

11. Patel HP, Moseley HC, Noar JH. Cephalometric determinants of successful functional appliance therapy. *Angle Orthod.* 2002; 72:410-7.
12. Almeida MR, Henriques JFC, Ursi W. Comparative study of the Frankel (FR-2) and bionator appliances in the treatment of Class II malocclusion. *Am J Orthod Dentofacial Orthop.* 2002; 121:458-66.
13. Janson GRP, Alegria Toruno JL, Rodrigez Martins D, Henriques JFC, de Freitas MR. Class II treatment effects of the Fränkel appliance. *Eur J Orthod.* 2003; 25:301-9.
14. Thieme KM, Nägerl H, Hahn W, Ihlow D, Kubein D. Variations in cyclic mandibular movements during treatment of Class II malocclusions with removable functional appliances. *Eur J Orthod.* 2011; 33(6):628-35.
15. Quintao C, Helena I, Brunharo VP, Menezes RC, Almeida MAO. Soft tissue facial profile changes following functional appliance therapy. *Eur J Orthod.* 2006; 28:35-41.
16. Malta LA, Baccetti T, Frenchi L, Faltin K Jr, McNamara JA Jr. Long-term dentoskeletal effect and facial profile changes induced by Bionator therapy. *Angle Orthod.* 2010; 80(1):10-7.
17. Siara-Olds NJ, Pangrazio-Kulbresch V, Berger J, Bayirli B. Long-term dentoskeletal changes with the Bionator, Herbst, Twin Block, and MARA functional appliances. *Angle Orthod.* 2010; 80(1):18-29.
18. Ren Y. Soft tissue changes inconclusive in Class II division 1 patients treated with Activator and Bionator appliances. *Evid Based Dent.* 2007; 8(2):49.
19. Baccetti T, McNamara JA Jr. The impact of functional jaw orthopedics in subjects with unfavourable class II skeletal patterns. *Prog Orthod.* 2010; 11(2):118-26.
20. Perillo L, Castaldo MI, Cannavale R, Longobardi A, Grassia V, Rullo R, et al. Evaluation of long-term effects in patients treated with Fränkel-2 appliance. *Eur J Paediatr Dent.* 2011; 12(4):261-6.
21. Freeman DC, McNamara JA Jr, Baccetti T, Franchi I, Fränkel C. Long-term treatment effects of the FR-2 appliance of Fränkel. *Am J Orthod Dentofacial Orthop.* 2009; 135(5):570-6.

Промене мекоткивног профила применом функционалних апарата у лечењу скелетних промена II класе

Зорана Стаменковић, Вања Раичковић, Владимир Ристић

Универзитет у Београду, Стоматолошки факултет, Клиника за ортопедију вилица, Београд, Србија

КРАТАК САДРЖАЈ

Увод Да би се учинак ортодонтског лечења могао сматрати успешним, неопходно је постићи фацијалну хармонију, при чему су структуре мекоткивног профила у хармонији са скелетним структурама неурокранијума и висцерокранијума. Код особа са скелетно-дисталним загрижајем изазваним мандибуларним ретрогнатизмом често је нарушена фацијална естетика у виду израженог конвекситета профила и промене у положају и међусобном односу усана.

Циљ рада Циљ овог истраживања био је да се утврди обим промена на структурама мекоткивног профила код особа са скелетно-дисталним загрижајем леченим помоћу три различита ортодонтска апарата: Френкеловог (*Fränkel*) регулатора функције тип I (*FR-I*), бионатора по Балтерсу (*Balters*) тип I и Хоцовог (*Hotz*) апарата.

Методе рада Истраживањем је обухваћено 60 пацијената са дијагнозом скелетно-дисталног загрижаја изазваног мандибуларним ретрогнатизмом у периоду ране мешовите дентиције. Свака подгрупа од по 20 испитаника лечена је различитим ортодонтским апаратима. На профилном телерендгенском снимку пре и после лечења анализирани су следећи параметри: угао *T*, угао *H*, висина горње усне и положај горње и доње усне у односу на естетску линију. У

оквиру статистичке анализе израчунати су средња, највећа и најмања вредност, стандардна девијација и коефицијент варијације, урађене двофакторска анализа варијансе с поновљеним мерењима и једнофакторска анализа варијансе уз примену теста *ANOVA*, Бонферонијевог (*Bonferroni*) теста и Студентовог *t*-теста.

Резултати Дошло је до значајног смањења вредности углова *T* и *H* при примени *FR-I* са 21,60° на 17,15°, односно са 16,45° на 13,40°, са статистичком значајношћу на нивоу $p < 0,001$. Применом *FR-I* смањена је висина горње усне са 26,15 *mm* на 25,85 *mm*, док се применом Хоцовог апарата и бионатора по Балтерсу тип I повећала, чиме се погоршао естетски изглед пацијента.

Закључак Сви коришћени ортодонтски апарати доводе до промена на мекоткивном профили у виду побољшања фацијалне естетике, при чему су промене најизразитије при коришћењу Френкеловог регулатора функције тип I, који најуспешније делује на постизање укупне хармоније лица пацијента.

Кључне речи: функционални апарати; Френкелов регулатор функције; мекоткивни профил; скелетно-дистални загрижај

Примљен • Received: 11/03/2014

Прихваћен • Accepted: 16/06/2014