



Urrets-Zavalía syndrome after deep anterior lamellar keratoplasty

Sindrom Urets-Zavalía nastao posle duboke prednje lamelarne keratoplastike

Vesna Jovanović*†, Ljubiša Nikolić**‡

*Faculty of Dental Medicine, University of Belgrade, Belgrade, Serbia; †Eye Clinic, University Medical Centre Zvezdara, Belgrade, Serbia; ‡Oculus Eye Infirmary, Belgrade, Serbia

Abstract

Introduction. Urrets-Zavalía syndrome is an uncommon complication of the deep anterior lamellar keratoplasty in keratoconus. The manifestations of this syndrome are an irreversible mydriasis, iris atrophy and secondary glaucoma. **Case report.** Deep anterior lamellar keratoplasty was done for keratoconus with a presumably healed corneal hydrops in a 21-year-old Caucasian man. The graft remained clear, but the surgery was complicated by a fixed, dilated pupil, patches of iris atrophy, ectropium of the iris pigment layer and glaukomflecken in the lens. **Conclusion.** Although safer than penetrating keratoplasty, the deep anterior lamellar corneal transplantation is not devoid of complications. Urrets-Zavalía syndrome can be avoided by not trying to secure an unhealed Descemet's membrane with air. Instead, a new Descemet's membrane transplanted within a penetrating graft is a safer choice.

Key words:

corneal transplantation; keratoconus; postoperative complications; syndrome.

Apstrakt

Uvod. Sindrom Urets-Zavalije je neuobičajena komplikacija posle operacije keratokonusa metodom duboke prednje lamelarne keratoplastike. Manifestacije ovog sindroma su trajna midrijaza, atrofiya dužice i sekundarni glaukom. **Prikaz bolesnika.** Kod bolesnika starog 21 godinu, urađena je duboka prednja lamelarna keratoplastika sa keratokonusom i naizgled zaceljenim hidropsom rožnjače. Kalem je ostao providan, ali se operacija komplikovala trajnom midrijazom, poljima atrofiye dužice, izvnutim rubom pigmentnog sloja dužice i mrljastim zamućenjima ispod prednje kapsule sočiva (*glaukomflecken*). **Zaključak.** Mada bezbednija od perforativne keratoplastike, duboka prednja lamelarna transplantacija rožnjače nije bez komplikacija. Sindrom Urets-Zavalije može se izbeći ako se umesto zaptivanja otvora u Descemetovoj membrani pomoću vazduha, presadi nova Descemetova membrana zajedno sa kalemom, tehnikom perforativne keratoplastike.

Ključne reči:

transplantacija rožnjače; keratokonus; postoperativne komplikacije; sindrom.

Introduction

Deep anterior lamellar keratoplasty (DALK) has become an alternative to penetrating keratoplasty (PK) in the treatment of keratoconus (KC) ¹. It permits preservation of the healthy endothelium of a young recipient, which makes late endothelial failure less probable and excludes endothelial rejection. Urrets-Zavalía syndrome (UZS) is a rare complication of DALK. Since the description of fixed, dilated pupil, iris atrophy and secondary glaucoma by Urrets-Zavalía in 1963 ², this syndrome, bearing his name, limited mainly to penetrating keratoplasty for keratoconus, has been the subject of many theories of its etiology. In the 1980s, it appeared to be extinct, probably due to less surgical trauma ³. However, new surgical techniques, barosurgery ⁴ and phakic lens implantation have brought the syndrome into the focus,

singling out pupillary block as its cause. Yet, the review of the literature has revealed only five papers describing 17 patients with UZS after DALK ⁵⁻⁹. To our knowledge, cases of this syndrome have not been presented in our literature. Thus, it seems worthwhile to address this issue again. We reported a case with UZS after DALK for keratoconus with a presumably healed Descemet's membrane after hydrops.

Case report

A 21-year-old Caucasian man was submitted to DALK in his left eye, which had developed hydrops six months earlier, leaving it with the best corrected visual acuity (BCVA) of counting fingers at 1 m. An initial 7.5 mm/300 µm trephination was used to remove the superficial slice of the cornea. While removing the deeper corneal layers by manual dissec-

tion, a small scar was noted at the site of a presumably healed Descemet's membrane (Figure 1) and a drop of aqueous protruded through a microperforation (Figure 2). An air-bubble injected into the anterior chamber enabled the removal of the remaining stroma and suturing an 8.0 mm graft with 16 interrupted 10-0 nylon sutures. Intravenous infusion of 100 mL 10% mannitol was started. Two hours later, approximately half of the bubble was aspirated, and the balanced salt solution was added. Dexamethasone and gentamycin were injected subconjunctivally at the end of surgery. Carbonic anhydrase inhibitor (acetazolamide, 500

pupil in the intact eye. There was still a small air bubble in the anterior chamber. On the second postoperative day, the pupil was fixed and dilated, with uveal ectropium from 10–2 o'clock, and *glaukomflecken* in the lens (Figure 3). The therapy with 1% pilocarpin did not constrict the pupil. During the following two weeks, patches of iris atrophy became visible, but the intraocular pressure was never higher than 19 mmHg. At three months follow-up, intraocular pressure was 16 mmHg, correction for astigmatism 2.25×120 , and BCVA was 20/50. These findings remained stationary during the following three months.

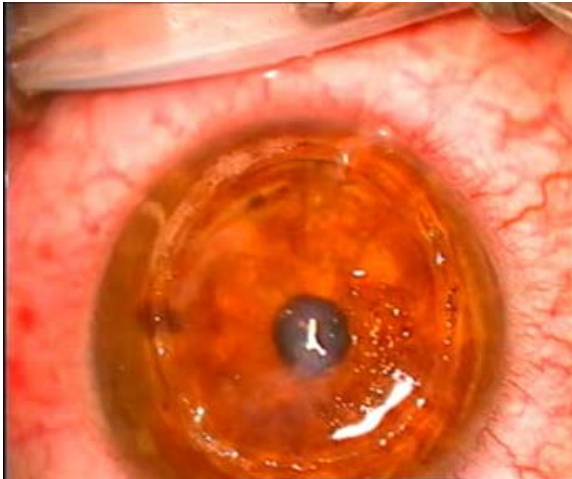


Fig. 1 – A scar at the site of presumably healed Descemet's membrane.

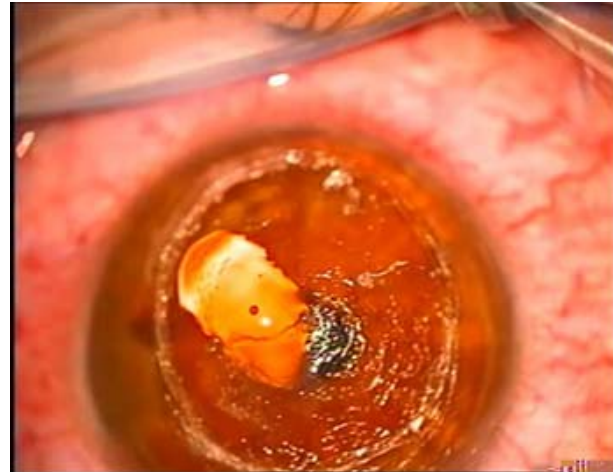


Fig. 2 – A drop of aqueous protruding through the unhealed microperforation in the Descemet's membrane.

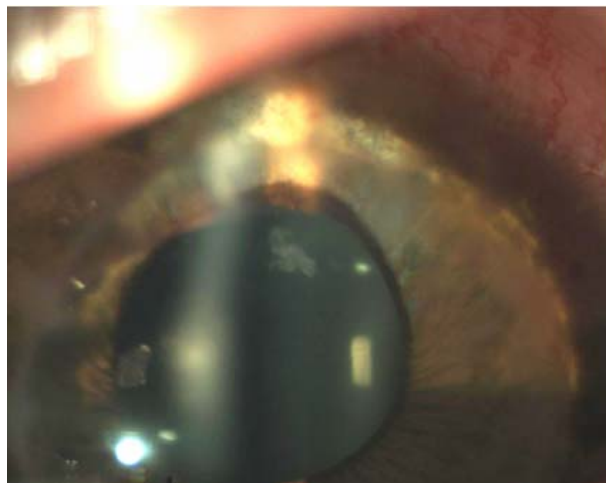


Fig. 3 – Fixed, dilated pupil, ectropium of the iris pigment layer, patches of iris atrophy and *glaukomflecken* in the lens.

mg) was given *per os* two hours after surgery. Intraocular pressure was checked digitally twice during the afternoon, and estimated to be normal. Another infusion of 100 mL 10% mannitol was given intravenously two hours before bedtime in order to prevent acute glaucoma during the night.

On the first postoperative day, the graft was clear, Descemet's membrane was attached, intraocular pressure was 19 mmHg, and the pupil was round, about 4 mm in diameter. It reacted to light, but less promptly and completely as did the

Discussion

The presented patient developed all classic signs of UZS, except for the late secondary glaucoma from angle closure by peripheral synechiae. Yet, the patient might have got it after the follow-up period. The influence of mydriatics and cycloplegics on the irreversible mydriasis in this case can be excluded, as the patient did not receive any of these drugs either pre- or postoperatively. Also, we have no data to sup-

port other etiologies of UZS, proposed in the older literature: abnormal reaction of the dilator musculature of the iris¹⁰, or a paralysis of parasympathetic nerves¹¹.

The trigger for the pathophysiological mechanism of UZS in this case seems to be an acute raise of intraocular pressure due to the pupillary block by air bubble during the first postoperative night, in spite of the therapy with mannitol and carbonic anhydrase inhibitor. *Glaukomflecken* in his lens are "the smoking gun" of acute glaucoma. The location of the patches of iris atrophy seems to correspond to the position where the air bubble exerted its pressure on the iris longer than elsewhere. This fits into the fluorescein and indocyanine green anterior segment angiography findings of ischemia of the iris¹². Although there are still cases of inexplicable etiology of UZS, like its development in only one eye after a bilateral trabeculectomy¹³, and a postoperative IOT of 19 mmHg, a recent retrospective study points to a rise of postoperative IOT as a serious indicator of an imminent UZS¹⁴. Even stronger confirmation of the significance of the pupillary block comes from a sudden rise of UZS after the

use of air, gas or phakic intraocular lenses^{9,15-17}. Finally, two recent papers report more cases of UZS after DALK for various indications than the complete previous literature^{8,9}. A constant event in these cases is a prolonged presence of an air bubble in the anterior chamber in order to seal a microperforation of Descemet membrane. Antiglaucoma medications and/or iridectomy, do not seem to offer an absolute protection of UZS¹³. Even if the pupillary block is not the sole explanation of the pathophysiology of UZS, it seems clear that its frequency is higher after a prolonged pressure of air on the iris¹⁸.

Conclusion

Irreversible mydriasis, iris atrophy and secondary glaucoma (Urrets-Zavalía syndrome) are infrequent complications after DALK. Yet, the doom of the lasting effects of this syndrome should govern surgeons to lower the incidence of UZS by converting to penetrating keratoplasty when corneal microperforation is evident, or even suspected.

R E F E R E N C E S

1. *Aggarwal R*. Deep lamellar keratoplasty: An alternative for penetrating keratoplasty. *Br J Ophthalmol* 1997; 81(3): 178–9.
2. *Urrets-Zavalía A Jr*. Fixed, dilated pupil, iris atrophy and secondary glaucoma. *Am J Ophthalmol* 1963; 56: 257–65.
3. *Pouliquen Y, Ginmaraes R, Petrountos G, Lacombe E*. Le syndrome d'Urrets-Zavalía: existe-t-il encore. *J Fr Ophtalmol* 1983; 6: 325–6.
4. *Giebel AW*. Barosurgery, the surgical use of air, as a technique to promote adhesion between corneal layers in lamellar keratoplasty. *Tech Ophthalmol* 2008; 6: 35–40.
5. *Maurino V, Allan BD, Stevens JD, Tuft SJ*. Fixed dilated pupil (Urrets-Zavalía syndrome) after air/gas injection after deep lamellar keratoplasty for keratoconus. *Am J Ophthalmol* 2002; 133(2): 266–8.
6. *Minasian M, Ayliffe W*. Fixed dilated pupil following deep lamellar keratoplasty (Urrets-Zavalía syndrome). *Br J Ophthalmol* 2002; 86(1): 115–6.
7. *Spadea L, Viola M, Viola G*. Regression of Urrets-Zavalía syndrome after deep lamellar keratoplasty for keratoconus: A case study. *Open Ophthalmol J* 2008; 2: 130–1.
8. *Niknam S, Rajabi MT*. Fixed dilated pupil (Urrets-Zavalía syndrome) after deep anterior lamellar keratoplasty. *Cornea* 2009; 28(10): 1187–90.
9. *Bozkurt KT, Acar BT, Acar S*. Fixed dilated pupilla as a common complication of deep anterior lamellar keratoplasty complicated with Descemet membrane perforation. *Eur J Ophthalmol* 2013; 23(2): 164–70.
10. *Castronovo R*. Atlas of Keratectomy and Keratoplasty. Philadelphia-London: WB Saunders Company; 1966. p. 336–7.
11. *Uribe LE*. Fixed pupil following keratoplasty: Evaluation of six cases. *Am J Ophthalmol* 1967; 63(6): 1682–6.
12. *Tuft SJ, Buckley RJ*. Iris ischaemia following penetrating keratoplasty for keratoconus (Urrets-Zavalía syndrome). *Cornea* 1995; 14(6): 618–22.
13. *Jain R, Assi A, Murdoch IE*. Urrets-Zavalía syndrome following trabeculectomy. *Br J Ophthalmol* 2000; 84(3): 338–9.
14. *Figueiredo GS, Kollí SS, Ahmad S, Gales K, Figueiredo FC*. Urrets-Zavalía syndrome following penetrating keratoplasty for keratoconus. *Graefes Arch Clin Exp Ophthalmol* 2013; 251(3): 809–15.
15. *Fournié P, Ponchel C, Malecaze F, Arné J*. Fixed dilated pupil (Urrets-Zavalía syndrome) and anterior subcapsular cataract formation after descemet stripping endothelial keratoplasty. *Cornea* 2009; 28(10): 1184–6.
16. *Aralikatti AKV, Tomlins PJ, Shah S*. Urrets-Zavalía syndrome following intracameral C3F8 injection for acute corneal hydrops. *Clin Experiment Ophthalmol* 2008; 36(2): 198–9.
17. *Yuzbasioglu E, Helvacioğlu F, Sencan S*. Fixed, dilated pupil after phakic intraocular lens implantation. *J Cataract Refract Surg* 2006; 32(1): 174–6.
18. *Spierer O, Lazgar M*. Urrets-Zavalía syndrome (fixed and dilated pupil following penetrating keratoplasty for keratoconus) and its variants. *Surv Ophthalmol* 2014; 59(3): 304–10.

Received on November 9, 2014.

Accepted on June 30, 2015.

Online First May, 2016.