



## Radiographic cephalometry analysis of condylar position after bimaxillary osteotomy in patients with mandibular prognathism

Rendgen-kefalometrijska analiza pozicije kondila nakon bimaksilarne osteotomije mandibularnog prognatizma

Nikola D. Miković\*, Miloš M. Lazarević\*, Zoran Tatić<sup>†‡</sup>, Sanja Krejović-Trivić<sup>†</sup>, Milan Petrović\*, Aleksandar Trivić<sup>§</sup>

\*Clinic of Maxillofacial Surgery, Faculty of Dentistry, University of Belgrade, Belgrade, Serbia; <sup>†</sup>Clinic of Oral Surgery and Implantology, Military Medical Academy, Belgrade, Serbia; <sup>‡</sup>Faculty of Medicine of the Military Medical Academy, University of Defence, Belgrade, Serbia; <sup>§</sup>Clinic of Otorhinolaryngology and Maxillofacial Surgery, Clinical Center of Serbia, Faculty of Medicine, University of Belgrade, Belgrade, Serbia

### Abstract

**Background/Aim.** Postoperative condylar position is a substantial concern in surgical correction of mandibular prognathism. Orthognathic surgery may change condylar position and this is considered a contributing factor for early skeletal relapse and the induction of temporomandibular disorders. The purpose of this study was to evaluate changes in condylar position, and to correlate angular skeletal measurements following bimaxillary surgery. **Methods.** On profile telerradiographs of 21 patients with mandibular angular and linear parameters, the changes in condylar position, were measured during preoperative orthodontic treatment and 6 months after the surgical treatment. **Results.** A statistically significant difference in values between the groups was found. The most distal point on the head of condyle point (DI) moved backward for 1.38 mm ( $p = 0.02$ ), and the point of center of collum mandibulae point (DC) moved backward for 1.52 mm ( $p = 0.007$ ). The amount of upward movement of the point DI was 1.62 mm ( $p = 0.04$ ). **Conclusion.** In the patients with mandibular prognathism, the condyles tend to migrate upward and forward six months after bimaxillary surgery.

### Key words:

prognathism; surgery, oral; postoperative period; cephalometry; temporomandibular joint; centric relation.

### Apstrakt

**Uvod/Cilj.** Postoperativna pozicija kondila je značajna za hiruršku korekciju mandibularnog prognatizma. Ortognatska hirurgija može da promeni poziciju kondila, a to može biti jedan od faktora koji doprinosi ranom skeletnom recidivu i pojavi temporomandibularnih disfunkcija. Zbog toga je cilj ove studije bio da proceni promene pozicije kondila kao i da ne korelišu promene pozicije kondila sa angularnim skeletnim promenama nakon bimaksilarne hirurgije. **Metode.** Na telerrendgenskim snimcima 21 bolesnika sa mandibularnim prognatizmom mereni su angularni i linearni parametri koji opisuju promene u položaju kondila, pre ortodonske pripreme i šest meseci nakon hirurške korekcije. **Rezultati.** Ustanovljena je statistička značajnost razlika u vrednosti parametara između grupa. Tačka DI – najdistalnija tačka na glavi kondila, pomerila se unazad 1,38 mm ( $p = 0,02$ ), a tačka DC – tačka koja označava centar *collum mandibulae*, pomerila se, takođe, unazad za 1,52 mm ( $p = 0,007$ ). Vrednost pomeranja tačke DI naviše bila je 1,62 mm ( $p = 0,04$ ). **Zaključak.** Kod bolesnika sa mandibularnim prognatizmom, kondili su težili da migriraju unapred i naviše šest meseci nakon bimaksilarne operacije.

### Ključne reči:

prognatizam; hirurgija, maksilofacijalna; postoperativni period; kefalometrija; temporomandibularni zglob; centrički odnos.

### Introduction

Mandibular prognathism (MP) or skeletal Class III malocclusion with a prognathic mandible has long been viewed as one of the most severe maxillofacial deformities<sup>1</sup>. The treatment of

MP is complex and includes preoperative orthodontic treatment and orthognathic surgery. In some severe cases both mandibular and maxillary osteotomy are needed. One of the preferred surgical procedures for the correction of mandibular prognathism, since its introduction by Trauner and Obwegeser<sup>2</sup>, is bilateral

sagittal split osteotomy (BSSO). Another popular technique, mostly used for maxillary reposition, is Le Fort I osteotomy. In some severe cases of MP both mandibular and maxillary osteotomy are needed, and that form of correction is commonly known as bimaxillary surgery.

One of the goals of bimaxillary surgery is maintaining skeletal and occlusal stability. Occlusal stability, which is one of the most important factors in the prevention of postoperative relapse in orthognathic surgery, results from good dental occlusion and a normal postoperative condylar position<sup>3</sup>. Condylar process is a part of the mandibular ramus and a part of the temporomandibular joint (TMJ), specific to the human body in its morphology, position and function<sup>4</sup>. This makes it particularly important, both in functional and in anatomical terms, because of its shape and position depending on the position of the mandible, the function of the TMJ and facial appearance<sup>5</sup>. Good dental occlusion depends on normal temporomandibular joint; that is, dental malocclusion or abnormal interdigitation with normal condylar position can be controlled postoperatively by orthodontic treatment, but an abnormal condylar position can not be corrected postoperatively and eventually disrupts postoperative occlusal stability<sup>3</sup>. Therefore, postoperative condylar position is a substantial concern in the surgical correction of a mandibular prognathism. Orthognathic surgery may change condylar position and this is considered a contributing factor for early skeletal relapse<sup>6-9</sup> and the induction of temporomandibular disorders (TMDs)<sup>10-13</sup>.

Positional changes in the condyle have been hard to recognize and accurately measure following orthognathic surgery<sup>14,15</sup>. Displacement of the condyle can be expected as a result of four variables: anterior-posterior, vertical, medial-lateral, and along the long axis of the condyle<sup>16</sup>.

The purpose of this study was to evaluate changes in condylar position, and to correlate angular skeletal measurements following bimaxillary surgery in patients with mandibular prognathism.

## Methods

The study included 21 patients (13 males, 8 females; ages between 18–25 years). Clinical examinations and standardized lateral cephalometric radiographs were conducted at the Belgrade University Faculty of Dentistry. The study was approved by the Ethics Committee at the Faculty of Dentistry in Belgrade. Informed consent was obtained from each patient. All the patients were diagnosed with mandibular prognathism on the basis of the following criteria: the angle of mandibular prognathism (SNB)  $\geq 80^\circ$ ; the angle of sagittal intermaxillary relationship (ANB)  $\leq 0^\circ$ ; reverse overlap of the frontal teeth and relationship of the first permanent molars in Class III, and had ended the growth and development of orofacial system. The patients with mandibular prognathism as a result of severe facial asymmetry, deformity secondary to trauma, syndromes, patients with systemic disease, degenerative joint disease, and with signs and symptoms of temporomandibular dysfunction were not included in the study.

The presurgical protocol included preoperative orthodontic treatment, model surgery, cephalometric and photocephalometric analysis. The preoperative orthodontic treatment lasted from 18 to 24 months.

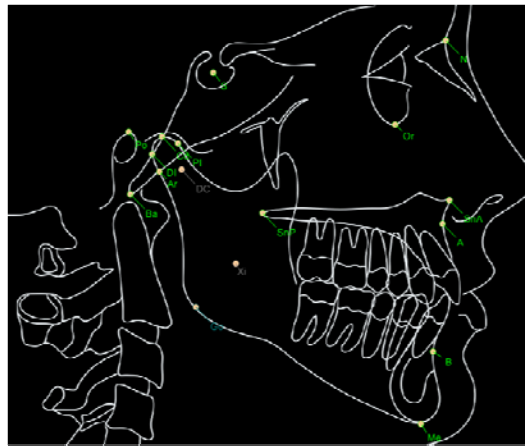
The surgery began with soft tissue incision and initial osteotomy of the ramus of the mandible as in BSSO, but with no definitive separation of bone fragments. The wound was filled with gauze soaked in saline and then the complete Le Fort I osteotomy was done. Using the interocclusal splint and maxillo-mandibular fixation, the maxilla was positioned in a certain position and fixed with monocortical screws (at least four) and L-shaped plates. After fixing the maxilla, the maxillo-mandibular fixation was removed, so the separation of mandibular bone fragments was completed. A separated central fragment of mandible was placed in the correct occlusion with the maxilla, the intermaxillary fixation was restored, and bone fragments of the mandible were fixed with monocortical screws and plates. Monocortical screws were located on the buccal surface of the mandible, three of them on each side of the osteotomy line. Rigid intermaxillary fixation was maintained for 6 to 8 weeks and after that period of time, the elastic fixation was maintained for 4 weeks. Postoperative orthodontic treatment started 6 to 8 weeks after the surgery.

Standardized lateral cephalometric radiographs were obtained at the following 2 stages in all the patients: before the preoperative orthodontic treatment (T1) and 6 months after the surgical treatment (T2).

The machine used to obtain lateral cephalometric radiographs was Ortoceph (Simens, Germany). The scanning settings of the machine were: 65–80 kVp tube voltage, 20 mA tube current, and 1–1.5 second scan time. All the patients sat in an upright position with the teeth in centric occlusion. The patients' Frankfort horizontal (FH) plane was parallel to the floor.

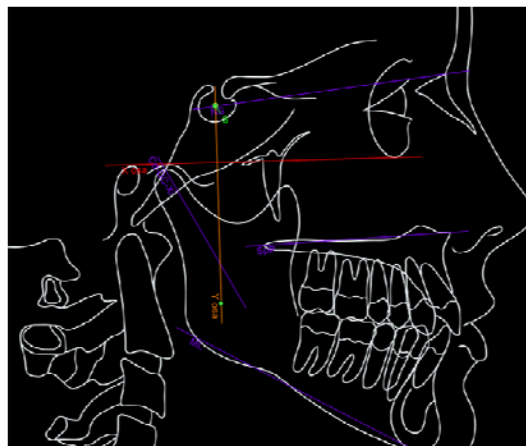
Cephalometric radiographs were scanned by a scanner EPSON 1600 PRO (Japan) into jpg format. In that way all the radiographs were converted into digital form. The software Ax Ceph version 2.3 (Audax, Slovenia) was used for computerized cephalometric analysis. Cephalometric analysis was carried out by one examiner and included the reference points and lines shown in Figures 1 and 2. Analyses were performed twice by the same examiner, on different days. Statistically significant differences did not appear between these two analyses.

Certain linear and angular parameters were used to define the position of the condyle pre- and postoperatively (Table 1). Angular parameters included: SNA – the angle of maxillary prognathism; SNB – the angle of mandibular prognathism; ANB – the angle of sagittal intermaxillary relationships; Cd-DC-Xi/FH – the angle formed by centerline of mandibular rami and X axis; ArGoMe – gonial angle (angle of the mandible); Sna-Snp/FH – the angle formed by the main plane of maxilla and X axis. Linear parameters were the distances between the points Go, Ar, DC, Cd, PI, CI, A, B and Y axis; and distances between the points Go, Ar, DC, Cd, PI, CI, A, B and X axis (see Abbreviations in addendum).



**Fig. 1 – Reference points included in the analysis.**

S (sella) – The point representing the geometric center of the *sella turcica*.; N (nasion) – The most anterior (midline) point of the frontonasal suture; A (*subspinale*) – The deepest point in the bony concavity in the midline below the anterior nasal spine; Or (*orbitalis*) – The point representing the lowest point on the inferior orbital rim; Po (porion) – The most superior point of the external auditory meatus; Sna (*spina nasalis anterior*) – The most prominent point of maxilla; Snp (*spina nasalis posterior*) – The most distal point of the conjunction of palatal bone and pterygomaxillar fissure; B (*supramentalis*) – The innermost point on the contour of the mandible between the incisor tooth and the bony chin; Me (menton) – The lowest point of the mandibular symphysis; Go (gonion) – the midpoint of the mandibular angle between the ramus and mandibular body; Cd (condylion) – the most posterosuperior point on head of the condyle; Ar (articularis) – The point midway between the two posterior borders of the left and the right mandibular rami at the intersection with the basilar portion of the occipital bone; DI – The most distal point on the head of the condyle; PI – The most anterior point on the head of the condyle; DC – The center point of the collum mandibulae on the Ba-N line; Xi – The point located at the geographic center of the ramus; Ba (basion) – The point of the anterior margin of the foramen magnum – The midpoint of the curvature between upper and the lower surfaces of the basilar portion of the occipital bone.



**Fig. 2 – Reference planes included in the analysis.**

N-S – The main plane of the anterior cranial base; Go-Me – The main plane of the mandible body; Sna-Snp – The main plane of the maxilla; Cd-DC-Xi – the centerline of the mandibular rami; X axis (Or-Po Frankfort horizontal (FH)) – The horizontal plane of the head; Y axis – The vertical plane which is normal to the X axis and goes from the point S.

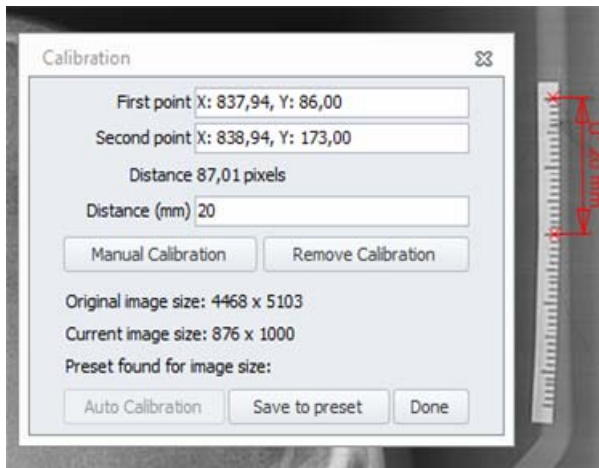
**Table 1**

**Linear and angular parameters included in the analysis**

Linear parameters (millimeters)	Angular parameters (degrees)
Go- Y axis	Cd-DC-Xi / FH
Ar- Y axis	ArGoMe
DC- Y axis	Sna-Snp / FH
Cd- Y axis	ANB
PI- Y axis	SNB
CI- Y axis	SNA
A- Y axis	
B- Y axis	
Go- X axis	
Ar- X axis	
DC- X axis	
Cd- X axis	
PI- X axis	
CI- X axis	
A- X axis	
B- X axis	

SNB – Angle of mandibular prognatism; ANB – Angle of sagittal intermaxillary relationship; SNA – sella nasion, A point. See abbreviations in Addendum.

Using the software, after insertion the digital (jpg) format of lateral cephalogram, calibration was set up. The calibration is used to convert pixels of the images into millimetres. A metal ruler on a cephalostat which is visible on radiography was used for calibration (Figure 3).



**Fig. 3 – Calibration of the digital image using the software “Ax Ceph”.**

Then, the location of reference points and lines were defined. To analyze linear (anterior-posterior and vertical) movement of the condyle, in every cephalometric radiograph the coordinate system with X and Y axis (as described in Figure 2) was inserted. After that, the distance between the points Go, Ar, DC, Cd, PI, CI, A, B and Y axis was measured to determine horizontal skeletal changes postoperatively. The distance between the points Go, Ar, DC, Cd, PI, CI, A, B and X axis was measured to determine vertical skeletal changes postoperatively. Angles SNA, SNB, and ANB were used to describe skeletal changes after the intervention. The angle Ar-Go-Me and angle Cd-DC-Xi/FH were used to analyze rotation of the condyle after the intervention. Angle Sna-Snp/FH was

used to describe rotation of the maxilla after bimaxillary surgery (see Abbreviations in addendum).

Data analysis was not performed until the last patient had been examined for the last time to prevent bias from the examiner's awareness of any trends in the basic data.

Statistical analyses were performed with SPSS version 15 (SPSS, Chicago, Ill). For the assessment of the differences between angular and linear parameters before (T1) and after (T2) the surgery, Students paired *t*-test was used. Pearson's correlation was used to correlate changes in condylar position with angular skeletal changes following bimaxillary surgery. The differences were considered significant at  $p < 0,05$ .

## Results

**Horizontal skeletal changes:** the mean setback of the mandible 6 months postoperatively (T2-T1) was 0.91 mm at point B but the differences were not statistically significant ( $p = 0.658$ ). Point Go showed tendency to go forward (1,19 mm) but also was not statistically significant ( $p = 0.242$ ). On the other hand, maxilla was on average moved forward 3.29 mm at point A ( $p = 0.0038$ ) (Table 2). **Horizontal changes in condylar position:** six months after the surgery the position of point DI and DC changed significantly. Point DI moved backward 1.38 mm ( $p = 0.02$ ), likewise, point DC moved backward for 1.52 mm ( $p = 0.007$ ). The movement of the points PI and Cd were not statistically significant, but it was noted that point PI showed the tendency to move forward by 0.1 mm (Table 2).

**Vertical skeletal changes:** the results showed the tendency of downward movement of the mandible at points B and Go (1.43 mm,  $p = 0.644$ ; 3.85 mm  $p = 0,058$ , respectively). Maxilla was moved upward at point A for 3.18 mm but showed no statistical significance (Table 3).

**Vertical changes in condylar position:** the position of condyle changed only at point DI. The amount of upward movement of point DI was 1.62 mm ( $p = 0.04$ ). Points PI and DC

**Table 2**

Distances between the reference points and Y axis							
Distances (mm)	n	$\bar{x}$	SD	Med	Min	Max	<i>p</i>
YB T1	21	60.48	14.84	65.00	39.00	100.00	0.658
YB T2	21	59.57	10.82	60.00	37.00	85.00	
YA T1	21	59.52	11.26	60.00	45.00	82.00	0.0038*
YA T2	21	62.81	8.01	63.00	47.00	79.00	
YDI T1	21	17.38	3.69	16.00	12.00	26.00	0.020*
YDI T2	21	18.76	4.21	19.00	8.00	24.00	
YPI T1	21	6.48	3.31	6.00	1.00	13.00	0.653
YPI T2	21	6.38	3.15	6.00	0.00	11.00	
YCd T1	21	14.38	3.97	14.00	8.00	24.00	0.446
YCd T2	21	14.86	3.62	16.00	6.00	20.00	
YDC T1	21	9.19	3.70	10.00	2.00	16.00	0.007*
YDC T2	21	10.71	3.94	11.00	2.00	17.00	
YAr T1	21	15.33	4.08	15.00	8.00	23.00	0.005*
YAr T2	21	16.86	3.92	16.00	7.00	23.00	
YGo T1	21	7.00	6.32	6.00	0.00	24.00	0.242
YGo T2	21	8.19	5.95	6.00	0.00	20.00	

\* $p < 0.05$  (2-tailed);  $\bar{x}$  – mean; SD – standard deviation; Med – median;

Min-Max – minimal-maximal value; T1 – Standardized lateral cephalometric radiographs obtained before preoperative orthodontic treatment; T2 – Standardized lateral cephalometric radiographs obtained 6 months after the surgical treatment.

See abbreviations in Addendum.

Table 3

Changes in distances between the reference points and X axis								
Distances (mm)		n	$\bar{x}$	SD	Med	Min	Max	<i>p</i>
XB	T1	21	71.86	13.28	71.00	45.00	95.00	0.644
	T2	21	73.29	9.03	71.00	61.00	96.00	
XA	T1	21	35.38	13.20	32.00	23.00	88.00	0.137
	T2	21	32.19	5.78	30.00	24.00	49.00	
XDI	T1	21	5.24	2.91	5.00	0.00	11.00	0.040*
	T2	21	6.86	3.41	7.00	0.00	14.00	
XPI	T1	21	3.62	1.99	4.00	0.00	8.00	0.887
	T2	21	3.81	3.17	3.00	0.00	12.00	
XCd	T1	21	4.33	3.79	4.00	0.00	16.00	0.263
	T2	21	3.57	2.73	3.00	0.00	8.00	
XDC	T1	21	8.48	5.47	11.00	0.00	16.00	0.335
	T2	21	9.10	6.20	10.00	0.00	17.00	
XAr	T1	21	12.86	4.05	12.00	6.00	20.00	0.007*
	T2	21	14.57	4.25	14.00	8.00	21.00	
XGo	T1	21	58.05	10.67	57.00	40.00	82.00	0.058
	T2	21	61.90	5.20	62.00	51.00	75.00	

\**p* < 0,05 (2-tailed);  $\bar{x}$  – mean; SD – standard deviation; Med – median; Min-Max – minimal-maximal value; T1 – Standardized lateral cephalometric radiographs obtained before preoperative orthodontic treatment; T2 – Standardized lateral cephalometric radiographs obtained 6 months after the surgical treatment. See abbreviations in Addendum.

showed the trend to move upward (0.19 mm and 0.62 mm, respectively). On the contrary, point Cd showed the tendency to move downward (0.76 mm; *p* = 0.263) (Table 3).

The results suggest that point Ar was moved significantly from both X and Y axis. Point Ar moved downward (mean difference T2-T1 was 1.71 mm; *p* = 0.007) and forward (T2-T1 was 1.53 mm; *p* = 0.005) (Tables 2 and 3).

SNA, SNB and ANB angle significantly changed postoperatively. SNA and ANB angle increased in dimensions (T2-T1) for 1.76° and 3.76° respectively (*p* = 0.049 and *p* < 0.001). On the other hand, SNB angle decreased for 1.95° (*p* = 0.04). Angles which predicted the rotation of the condyle – ArGoMe changed significantly (*p* = 0.009) for 5.1°, but Cd-DC-Xi/FH did not (*p* = 0.277). The rotation of maxilla (SnaSnp/FH angle) did not change significantly six months after the surgery (*p* = 0.128) (Table 4).

The study showed a positive correlation between the distance XB and the ArGoMe angle. The XA distance also correlated negatively with ArGoMe angle. The distance between the point DI and the X axis showed negative correlation with SNA angle (Table 5).

A positive correlation between the distance YB and the angle SNB, YA and SNB was noted. The distance between the Y axis and the point DI showed a positive correlation with the angle ArGoMe (Table 6).

### Discussion

Condyle displacement from or in the glenoid fossa can be caused by abnormal mandibular movement, methods used for fixation, segment rigidity, or masticatory muscle tension<sup>17</sup>. Condylar displacement, especially after BSSO, can cause postoperative complications<sup>18</sup>. Rotational changes also contribute to idiopathic condylar resorption after BSSO<sup>14-16</sup>. The direction of movement of the jaw during surgery is of great importance because it is considered to be one of the factors that influence the postoperative position of the condyle<sup>3</sup>. This study shows a statistically significant movement of the mandible six months after the surgery, which significantly influenced the position of the condyle. Studies have shown that the method of fixation of fragments contributes significantly to the stability of the condyle<sup>8,16,19</sup>, for

Table 4

Changes in angular parametres								
Angle (°)		n	$\bar{x}$	SD	Med	Min	Max	<i>p</i>
SNA	T1	21	81.86	5.51	82.00	72.00	96.00	0.049*
	T2	21	83.62	5.59	84.00	74.00	94.00	
SNB	T1	21	86.57	6.03	88.00	77.00	103.00	0.040*
	T2	21	84.62	5.04	84.00	75.00	92.00	
ANB	T1	21	-4.71	2.41	-4.00	-10.00	0.00	< 0.001**
	T2	21	-0.95	2.62	-1.0	-6.00	3.00	
ArGoMe	T1	21	139.48	7.94	137.00	126.00	155.00	0.009*
	T2	21	134.38	8.55	134.00	119.00	154.00	
Cd-DC-Xi/FH	T1	21	61.90	6.20	62.00	43.00	70.00	0.277
	T2	21	63.76	6.36	63.00	52.00	77.00	
SnaSnpFH	T1	21	4.10	3.27	4.00	0.00	9.00	0.128
	T2	21	5.19	3.37	5.00	1.00	11.00	

\**p* < 0.05 (2-tailed); \*\**p* < 0.001 (2-tailed);  $\bar{x}$  – mean; SD – standard deviation; Med – median; Min-Max – minimal-maximal value; T1 – Standardized lateral cephalometric radiographs obtained before the preoperative orthodontic treatment; T2 – Standardized lateral cephalometric radiographs obtained 6 months after the surgical treatment. See abbreviations in Addendum.

Table 5

Correlation of angular and linear parametres (Xaxis)							
(T1-T2) n = 21		Cd-DC-Xi / FH	SnaSnp/FH	ArGoMe	SNA	SNB	ANB
X B	r	0.009	-0.031	0.652**	-0.206	-0.303	0.194
	p	0.969	0.893	0.001	0.371	0.182	0.400
X A	r	0.069	-0.188	-0.619**	0.041	0.280	-0.347
	p	0.768	0.415	0.003	0.859	0.218	0.123
X DI	r	-0.063	-0.053	0.148	-0.509*	-0.360	-0.191
	p	0.787	0.818	0.523	0.018	0.109	0.406
X PI	r	-0.067	-0.053	0.037	-0.130	-0.340	0.237
	p	0.775	0.818	0.873	0.574	0.131	0.300
X Cd	r	0.193	0.374	0.232	-0.238	-0.394	0.177
	p	0.403	0.095	0.311	0.299	0.077	0.442
X DC	r	0.077	0.010	-0.089	-0.414	-0.245	-0.261
	p	0.740	0.966	0.702	0.062	0.284	0.252
X Ar	r	-0.234	-0.123	0.261	-0.207	-0.146	-0.041
	p	0.308	0.594	0.252	0.368	0.527	0.860
X Go	r	0.035	-0.171	-0.339	0.074	0.274	-0.252
	p	0.881	0.457	0.133	0.749	0.229	0.271

\*Correlation is significant at the level  $p < 0.05$  (2-tailed); \*\*Correlation is significant at the level  $p < 0.01$  (2-tailed); (T1-T2) – The difference in dimensions in angles/distances before the preoperative orthodontic treatment and six months after the correction of mandibular prognathism. See abbreviations in Addendum.

Table 6

Correlation of angular and linear parametres (Y axis)							
(T1-T2) n = 21		Cd-DC-Xi / FH	SnaSnp/FH	ArGoMe	SNA	SNB	ANB
Y B	r	-0.303	-0.005	-0.027	0.379	0.680**	-0.360
	p	0.181	0.983	0.906	0.090	0.001	0.109
Y A	r	-0.174	-0.053	-0.218	0.422	0.499*	-0.112
	p	0.450	0.819	0.343	0.057	0.021	0.630
Y DI	r	-0.099	0.078	0.498*	-0.235	-0.061	-0.194
	p	0.668	0.738	0.022	0.306	0.793	0.398
Y PI	r	0.204	-0.393	-0.370	-0.308	-0.234	-0.090
	p	0.374	0.078	0.099	0.175	0.308	0.700
Y Cd	r	-0.328	-0.123	0.178	-0.067	0.071	-0.163
	p	0.147	0.595	0.440	0.774	0.759	0.481
Y DC	r	-0.294	-0.225	0.425	-0.179	-0.236	0.131
	p	0.195	0.327	0.055	0.437	0.303	0.571
Y Ar	r	0.112	0.206	0.422	-0.415	-0.276	-0.129
	p	0.629	0.370	0.057	0.061	0.226	0.577
Y Go	r	0.175	0.009	-0.275	0.193	0.189	0.081
	p	0.447	0.969	0.227	0.401	0.413	0.727

\*Correlation is significant at level  $p < 0.05$  (2-tailed); \*\*Correlation is significant at level  $p < 0.01$  (2-tailed); (T1-T2) – difference in dimensions in angles/distances before preoperative orthodontic treatment and six months after the correction of mandibular prognathism. See abbreviations in Addendum.

these reasons, in this study the patients' jaw fragments were connected with rigid fixation.

Many researchers, using various radiographic methods, studied the movement of the condyle in patients after orthognathic surgery<sup>20-22</sup>. However, there are still few studies that deal with bimaxillary orthognathic surgery mandibular prognathism<sup>23,24</sup>. In this study, four points on the condyle – DI, PI, DC and Cd were used and based on the distance of these points with the X and Y axis the anteroposterior and vertical changes in position of the condyle before the preoperative orthodontic preparation and 6 months after the bimaxillary surgical correction were established. The results of this study indicate the condyle tend to move forward and upward. The anterior condyle movement is similar with the study which Ueki et al.<sup>25</sup> conducted. They also reported that there was anterior and inferior move-

ment of the condyle after BSSO and intraoral vertical ramus osteotomy, but there was no statistically significant difference between these different techniques. The possible reason for moving the condyle forward and downward is anatomical feature of the front part of the glenoid fossa<sup>3</sup>.

On the other hand, Hu et al.<sup>26</sup> investigated the effect of sagittal split ramus osteotomy of the mandible on the temporomandibular joint. By comparing images of temporomandibular joints, they noticed a posterior condyle movement in the group of patients who underwent BSSO. They also found the forward rotation of the condyle, which is similar to our results. These results can be explained by the pulling force of the anterior and posterior segments of *m. temporalis* and *m. masseter*. In this study there was a decrease in the value of the angle ArGoMe six months after the surgery which could partially influence the

forward rotation of the condyle. Contrary to the results of Hu et al.<sup>26</sup>, a study by Harris et al.<sup>27</sup> showed medial, posterior and superior movement of the condyle after BSSO, and also medial rotation of the condyle.

The results showed that the amount of the mandibular and maxillar movement postoperatively did not correlate statistically with condylar displacement as did the results of Harris et al.<sup>27</sup> and Lee and Park<sup>3</sup>. Interestingly, only changes in ArGoMe angle correlated with the changes in the distance Y-DI, and changes in the angle SNA correlated with changes in the distance X-DI.

## Conclusion

This study shows that the position of the condyle after bimaxillary orthognathic surgery is altered. In our group of patients, six months after surgery, the condyles tend to migrate upward and forward. Only the most distal point on the head of the condyle (point DI) correlated with the gonial and SNA angle. Although this study yielded significant results over a period of six months, it was performed in a limited number of patients due to strict inclusion criteria. Further research on changes in condylar position is needed with a longer observation period.

## R E F E R E N C E S

1. Gruber LW. Chin cup therapy for mandibular prognathism. *Am J Orthod* 1977; 72(1): 23–41.
2. Traumer R, Obwegeser H. The surgical correction of mandibular prognathism and retrognathia with consideration of genioplasty. *Oral Surg Oral Med Oral Pathol Oral Radiol Endod* 1957; 10(7): 677–89.
3. Lee W, Park JU. Three-dimensional evaluation of positional change of the condyle after mandibular setback by means of bilateral sagittal split ramus osteotomy. *Oral Surg Oral Med Oral Pathol Oral Radiol Endod* 2002; 94(3): 305–9.
4. Cutović T, Pavlović J, Kozomara R. Radiographic cephalometry analysis of dimensions of condylar process in persons with mandibular prognathism. *Vojnosanit Pregl* 2008; 65(7): 513–9. (Serbian)
5. Ricketts RM, Roth RH, Chacones SJ, Schllhof RJ, Engel GA. Orthodontic diagnosis and planing. Denver: Rocky Mountain Data Systems; 1982.
6. Joss CU, Vassalli IM. Stability after bilateral sagittal split osteotomy advancement surgery with rigid internal fixation: a systematic review. *J Oral Maxillofac Surg* 2009; 67(2): 301–13.
7. Epker BN, Wessberg GA. Mechanisms of early skeletal release following surgical advancement of the mandible. *Br J Oral Surg* 1982; 20(3): 175–82.
8. Will LA, Joondeph DR, Hohl TH, West RA. Condylar position following mandibular advancement: its relationship to relapse. *J Oral Maxillofac Surg* 1984; 42(9): 578–88.
9. Van SJ, Tiner BD, Keeling SD, Clark GM, Bays R, Rugh J. Condylar position with rigid fixation versus wire osteosynthesis of a sagittal split advancement. *J Oral Maxillofac Surg* 1999; 57(1): 31–4.
10. Ellis E, Hinton RJ. Histologic examination of the temporomandibular joint after mandibular advancement with and without rigid fixation: an experimental investigation in adult *Macaca mulatta*. *J Oral Maxillofac Surg* 1991; 49(12): 1316–27.
11. Lisniewska-Machorowska B, Cannon J, Williams S, Bantleon H. Evaluation of force systems from a "free-end" force system. *Am J Orthod Dentofacial Orthop* 2008; 133(6): 791–10.
12. Mladenović I, Jović N, Čutović T, Mladenović G, Kozomara R. Temporomandibular disorders after orthognathic surgery in patients with mandibular prognathism with depression as a risk factor. *Acta Odontol Scand* 2013; 71(1): 57–64.
13. Mladenović I, Dodić S, Stošić S, Petrović D, Cutović T, Kozomara R. TMD in class III patients referred for orthognathic surgery: psychological and dentition-related aspects. *J Craniomaxillofac Surg* 2014; 42(8): 1604–9.
14. Kawamata A, Fujishita M, Nagahara K, Kanematu N, Niva K, Langlais RP. Three-dimensional computed tomography evaluation of post-surgical condylar displacement after mandibular osteotomy. *Oral Surg Oral Med Oral Pathol Oral Radiol Endod* 1998; 85(4): 371–6.
15. Bettge G, Cinquin P, Lebeau J, Raphaël B. Computer-assisted orthognathic surgery: Clinical evaluation of a mandibular condyle repositioning system. *J Oral Maxillofac Surg* 2002; 60(1): 27–34.
16. Kundert M, Hadjiangbelou O. Condylar displacement after sagittal splitting of the mandibular rami. A short-term radiographic study. *J Maxillofac Surg* 1980; 8(4): 278–87.
17. Ueki K, Degerlyurt K, Hashiba Y, Marukawa K, Nakagawa K, Yamamoto E. Horizontal changes in the condylar head after sagittal split ramus osteotomy with bent plate fixation. *Oral Surg Oral Med Oral Pathol Oral Radiol Endod* 2008; 106(5): 656–61.
18. Ueki K, Nakagawa K, Takatsuka S, Yamamoto E. Plate fixation after mandibular osteotomy. *Int J Oral Maxillofac Surg* 2001; 30(6): 490–6.
19. Nishimura A, Sakurada S, Iwase M, Nagumo M. Positional changes in the mandibular condyle and amount of mouth opening after sagittal split ramus osteotomy with rigid or nonrigid osteosynthesis. *J Oral Maxillofac Surg* 1997; 55(7): 672–6.
20. Fang B, Shen GF, Yang C, Wu Y, Feng YM, Mao LX, et al. Changes in condylar and joint disc positions after bilateral sagittal split ramus osteotomy for correction of mandibular prognathism. *Int J Oral Maxillofac Surg* 2009; 38(7): 726–30.
21. Kim YI, Jung YH, Cho BH, Kim JR, Kim SS, Son WS, et al. The assessment of the short- and long-term changes in the condylar position following sagittal split ramus osteotomy (SSRO) with rigid fixation. *J Oral Rehabil* 2010; 37(4): 262–70.
22. Chen S, Lei J, Wang X, Fu K, Farzad P, Yi B. Short- and long-term changes of condylar position after bilateral sagittal split ramus osteotomy for mandibular advancement in combination with Le Fort I osteotomy evaluated by cone-beam computed tomography. *J Oral Maxillofac Surg* 2013; 71(11): 1956–66.
23. Draenert FG, Erbe C, Zenglein V, Kämmerer PW, Wriedt S, Al Nawas B. 3D analysis of condylar position after sagittal split osteotomy of the mandible in mono- and bimaxillary orthognathic surgery - a methodology study in 18 patients. *J Orofac Orthop* 2010; 71(6): 421–9.
24. Kim Y, Lee Y, Chun Y, Kang N, Kim S, Kim M. Condylar positional changes up to 12 months after bimaxillary surgery for skeletal class III malocclusions. *J Oral Maxillofac Surg* 2014; 72(1): 145–56.
25. Ueki K, Marukawa K, Nakagawa K, Yamamoto E. Condylar and temporomandibular joint disc positions after mandibular osteotomy for prognathism. *J Oral Maxillofac Surg* 2002; 60(12): 1424–32.
26. Hu J, Wang D, Zou S. Effects of mandibular setback on the temporomandibular joint: a comparison of oblique and sagittal split ramus osteotomy. *J Oral Maxillofac Surg* 2000; 58(4): 375–80.
27. Harris MD, Van SJ, Alder M. Factors influencing condylar position after the bilateral sagittal split osteotomy fixed with bicortical screws. *J Oral Maxillofac Surg* 1999; 57(6): 650–4.

Received on December 10, 2014.

Revised on February 23, 2015.

Accepted on March 5, 2015.

Online First July, 2015.

**Addendum****Abbreviations:**

S (sella) – The point representing the geometric center of the *sella turcica*; N (nasion) – The most anterior (midline) point of the frontonasal suture; A (*subspinale*) – The deepest point in the bony concavity in the midline below the anterior nasal spine; Or (*orbitalis*) – The point representing the lowest point on the inferior orbital rim; Po (porion) – The most superior point of the external auditory meatus; Sna (*spina nasalis anterior*) – The most prominent point of maxilla; Snp (*spina nasalis posterior*) – The most distal point of the conjunction of palatal bone and pterygomaxillar fissure; B (*supramentalis*) – The innermost point on the contour of the mandible between the incisor tooth and the bony chin; Me (menton) – The lowest point of the mandibular symphysis; Go (gonion) – the midpoint of the mandibular angle between the ramus and mandibular body; Cd (condylion) – the most posterosuperior point on head of the condyle; Ar (articularis) – The point midway between the two posterior borders of the left and the right mandibular rami at the intersection with the basilar portion of the occipital bone; DI – The most distal point on the head of the condyle; PI – The most anterior point on the head of the condyle; DC – The center point of the collum mandibulae on the Ba-N line; Xi – The point located at the geographic center of the ramus; Ba (basion) – The point of the anterior margin of the foramen magnum – The midpoint of the curvature between upper and the lower surfaces of the basilar portion of the occipital bone. N-S – The main plane of the anterior cranial base; Go-Me – The main plane of the mandible body; Sna-Snp – The main plane of the maxilla; Cd-DC-Xi – the centerline of the mandibular rami; X axis (Or-Po Frankfort horizontal (FH)) – The horizontal plane of the head; Y axis – The vertical plane which is normal to the X axis and goes from the point S.